

## CASE REPORT

# Parieto-temporal pleomorphic xanthoastrocytoma in a black African child

Aaron Musara, Kazadi K. Kalangu, Maximillan N. Dzowa, Wilfred Muteweze, Rudo Mutasa<sup>1</sup>

Departments of Surgery and <sup>1</sup>Pathology, University of Zimbabwe, College of Health Sciences, Avondale, Harare, Zimbabwe

## ABSTRACT

Pleomorphic xanthoastrocytoma (PXA) is a rare cerebral tumor, accounting for <1% of all astrocytic neoplasms. PXA, usually, has a favorable prognosis in spite of what might be suggested from the ominous microscopic appearance. There is no literature immediately available on the black population for this tumor. Management is by surgical resection. The ideal is gross total resection, which offers an excellent prognosis. This disease condition has not been reported in the black population. The following is a presentation of a case report in a black African girl, followed by a review of the literature.

**Key words:** Astrocytic neoplasms, brain tumor, pleomorphic xanthoastrocytoma

## Introduction

Pleomorphic xanthoastrocytoma (PXA) is a rare cerebral tumor, accounting for <1% of all astrocytic neoplasms.<sup>[1]</sup> It was originally described by Kepes *et al.* in 1979 in a case series of 12 patients.<sup>[2]</sup> It was only in 1993 that it was added to the World Health Organization classification of central nervous system tumors.<sup>[3]</sup> The description of the tumor led to a re-examination of pathological specimens from long forgotten resected supratentorial tumors. One of such cases was a re-examination of a left temporo-parietal tumor removed in 1930 from a medical student aged 24, by Mr. Hugh Cairns in London.<sup>[4]</sup> The patient survived for 40 year's post resection without any recurrence. Re-examination of the specimen revealed that the tumor was a PXA. Though PXA is a rare tumor, it has fascinated researchers worldwide with more than 250 articles being written since the description of the condition. Most of the cases in the literature are from the West. Few cases from the Asian continent have been reported.<sup>[5]</sup> However, there is a paucity of literature from Africa or the black population concerning the tumor.

## Case Report

A 5-year-old girl presented with a history of headache, inability to walk, talk, and sit, drooling saliva, excessive sleeping and seizures. She had progressively worsening hemi-paresis for about 5 months.

The child had a past medical history of right-sided hemi-paresis at the age of 1 year 2 months. She was able to continue walking but, with a spastic gait and a weak right-hand grip. She was taken to hospital at that time where a clinical diagnosis of a cerebro-vascular accident was made. A computed tomography (CT) scan of the brain done then suggested a vascular event with a resultant left parietal area porencephalic cyst secondary to a suspected vascular event [Figure 1]. The child had physiotherapy done at that time with little improvement.

She was referred to our neurosurgical unit in the current presentation. On examination, the child was lethargic, with a reduced level of consciousness of 12/15 and hemiparesis.

A CT scan done revealed a large left temporo-parietal mass with peri-lesional oedema, marked midline shift and dilated ventricles [Figure 2]. After optimizing the child's condition, a temporo-parietal craniotomy for excision of the tumor was

This is an open access article distributed under the terms of the Creative Commons Attribution-NonCommercial-ShareAlike 3.0 License, which allows others to remix, tweak, and build upon the work non-commercially, as long as the author is credited and the new creations are licensed under the identical terms.

**For reprints contact:** reprints@medknow.com

Access this article online	
<b>Quick Response Code:</b> 	<b>Website:</b> <a href="http://www.asianjns.org">www.asianjns.org</a>
	<b>DOI:</b> 10.4103/1793-5482.145535

## Address for correspondence:

Dr. Aaron Musara, Department of Surgery, University of Zimbabwe College of Health Sciences, Avondale, P.O. Box A178, Harare, Zimbabwe.

E-mail: musaraaaron@zol.co.zw

**How to cite this article:** Musara A, Kalangu KK, Dzowa MN, Muteweze W, Mutasa R. Parieto-temporal pleomorphic xanthoastrocytoma in a black African child. *Asian J Neurosurg* 2017;12:298-301.

done. At operation, this was a firm and very vascular tumor with a -well-defined edge. Gross complete excision of the lesion was done. A repeat CT scan was done 5 days post-operation. It showed post-operative edema, an epidural hygroma, postoperative mild brain contusion around the tumor cavity and hydrocephalus [Figure 3].

Post-operative recovery was complicated by cerebrospinal fluid leak and surgical site infection. The cerebrospinal fluid leak closed spontaneously after about 4 days and the infection settled on antibiotics. The hydrocephalus was managed conservatively. There was a remarkable gain in power on the hemiparetic side with the child being able to walk with support, talking and able to sit at 1 month post-operation. The histology results of the lesion were consistent with a PXA [Figures 4 and 5].

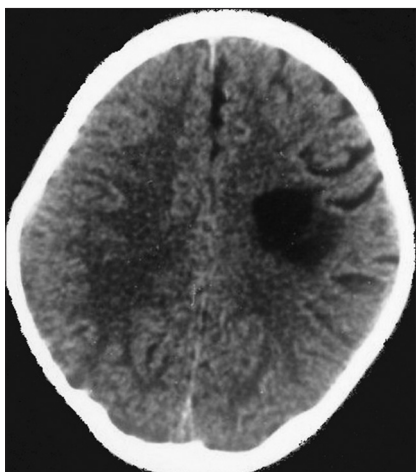
### Discussion

Pleomorphic xanthoastrocytoma is an astrocytic tumor which has a favorable prognosis in spite of what might be suggested

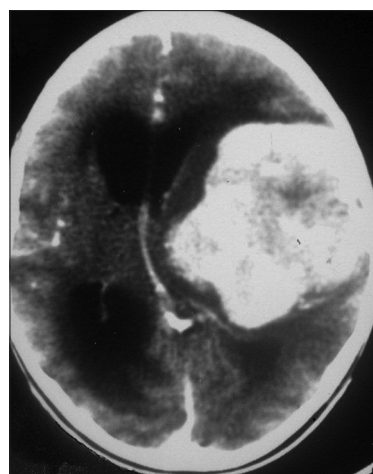
from the ominous microscopic appearance. The tumor though has the potential for aggressive behavior. It is, usually, a superficial tumor with a predilection for the supratentorial region, most commonly found in the temporal region, followed by frontal and parietal regions, respectively.<sup>[6]</sup> Most of the affected population is young (children and young adults below 30 years). A few cases have however been described in adults. It equally afflicts males and females though in one series there was a slight male preponderance (1.25:1).<sup>[7]</sup> Clinically, most of the patients present with headaches and seizures (57%). The patient can also present with focal neurological deficits as well as signs of raised intracranial pressure.

The pathophysiology of PXAs is obscure. Recent studies suggest the presence of neuronal differentiation and an origin from pluri-potent precursor cells.<sup>[8]</sup> In molecular genetics, p35 gene aberrations have been implicated in PXA formation and progression.<sup>[9]</sup>

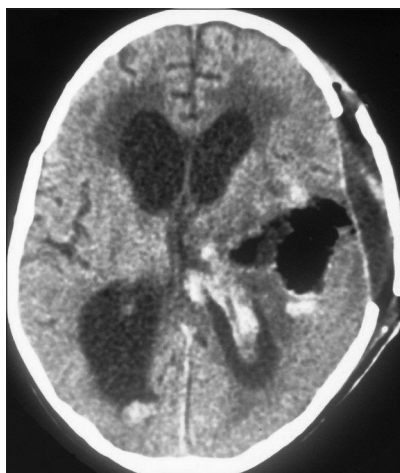
Pleomorphic xanthoastrocytoma has also been noted to develop in atypical sites. While more than 200 cases of



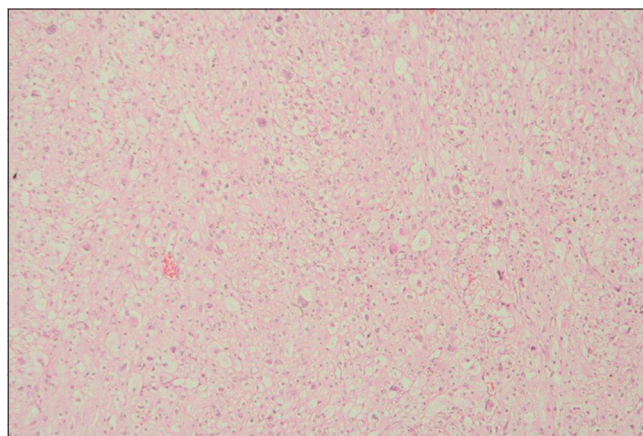
**Figure 1:** This is the computed tomography scan image of the patient done four years before the current presentation. This had been thought to be a porencephalic cyst secondary to a vascular event



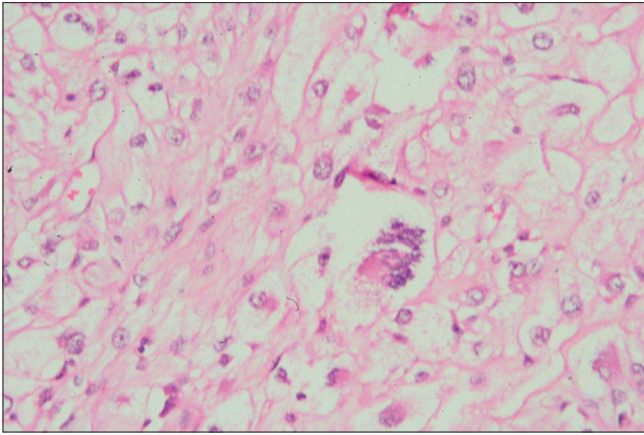
**Figure 2:** Preoperative computed tomography scan



**Figure 3:** Postoperative computed tomography scan



**Figure 4:** Pleomorphic appearance with spindle cell admixed with mono and multi-nucleated giant cells on low power magnification 1:10



**Figure 5:** Xanthomatous change due to intracellular lipid droplets in astrocytes on higher magnification 1:40 magnification

supratentorial involvement have been described, cerebellar and spinal involvement has also been described. About 10 cases of cerebellar PXA have been published in the literature. Cerebellar PXA has been noted to be associated with a higher mean age at presentation (35.3 years).<sup>[10]</sup> There is also a higher rate of ganglioma components compared with the supratentorial PXA. The tumor also, usually, involves median cerebellar structures. Six cases of spinal involvement have been described.<sup>[10]</sup> Other atypical PXAs described in the literature are anaplastic PXAs (17 cases) and those with malignant transformation at the time of surgical resection (23 cases).

Imaging studies reveal a contrast-enhancing mass with distinct edges. It may also appear as a cystic mass with an enhancing mural nodule. Calcifications of PXA are rare. There may also be edema around the mass in some cases. On magnetic resonance imaging (MRI), PXA appears as a well-circumscribed mass of variable size in the superficial cortical zone. T1-weighted imaging may show a low or mixed signal lesion whilst T2-imaging may reveal a high or mixed signal lesion. There may also be some cystic components on MRI. The use of MRI has been suggested to be more diagnostic in imaging than CT.<sup>[11-13]</sup>

On histological examination, there is pleomorphic appearance of spindle cells admixed with mono and multi-nucleated giant cells. There is also xanthomatous change due to intracellular lipid droplets. There may also be ganglial components on histological examination. On immunohistochemistry, there is an expression of glial fibrillary acidic protein and S100 protein. More recently the tumor has also been shown to express neuronal markers such as synaptophysin, neurofilament, and class IIIB tubulin. One study found CD34 immunoreactivity in various fractions of tumor cells in 44 out of 60 PXAs investigated.<sup>[14]</sup> Immunohistochemistry studies were however not done because of the unavailability of the service in our setting.

Management of PXA is by surgical resection. The ideal would be gross total resection. When this is not technically feasible,

near total resection (>90% of the tumor) can also be done. There are however some instances where a surgeon has to settle for a subtotal resection. PXA by its nature is a superficial and well-circumscribed tumor rendering it amenable to near total or even gross total resection. The role of chemotherapy and radiotherapy in the management of PXA has not been clearly established.<sup>[12,15]</sup> In one study, Macaulay noted that post-operative radiotherapy delayed recurrence time but did not improve overall survival.<sup>[15]</sup> Other studies have been inconclusive.

While resection is typically curative, PXA may undergo spontaneous malignant transformation compared to other low-grade tumors (e.g. pilocytic astrocytoma). In a comparison of brain tumors, PXA's appear to fare worse than pilocytic astrocytoma and oligodendroglioma, more so in younger patients. Despite that, high-grade PXA patients have significantly better overall survival compared with glioblastoma multiforme. Vigilant long-term follow-up is thus of importance. There have been case reports of recurrence after 18 years. The management of recurrence is surgical excision. However, there may be a need for adjuvant radiation therapy or chemotherapy at tumor recurrence.<sup>[6,16]</sup>

Pleomorphic xanthoastrocytoma has a favorable outcome in most cases. In one series, the largest series to date, the survival rates were 81% at 5 years and 70% at 10 years ( $n = 71$ ).<sup>[17]</sup> A number of factors determine the prognosis. Firstly, extent of resection has been found to be a prognostic factor. Gross total resection is associated with a good prognosis whilst subtotal resection is associated with a high recurrence and poor prognosis. In addition, anaplasia on histological examination is also a poor prognostic sign. With anaplasia, there is a high mitotic index (>5 mitosis/10 high power fields). The presence of necrosis also signifies poor prognosis. At resection, some tumors may already have malignant transformation. Development of malignant transformation occurs in 10-15% of cases.<sup>[18]</sup> This is also associated with high recurrence rate and a poor prognosis.

In this article, PXA of the brain occurred in a black child. PXA should be considered in the differential diagnosis of well-delineated lesions in this population.

### Financial support and sponsorship

Nil.

### Conflicts of interest

There are no conflicts of interest.

### References

1. Giannini C, Scheithauer BW, Burger PC, Brat DJ, Wollan PC, Lach B, *et al.* Pleomorphic xanthoastrocytoma: What do we really know about it? *Cancer* 1999;85:2033-45.
2. Kepes JJ, Rubinstein LJ, Eng LF. Pleomorphic xanthoastrocytoma: A distinctive meningocerebral glioma of young subjects with relatively

- favorable prognosis. A study of 12 cases. *Cancer* 1979;44:1839-52.
3. Giannini CP, Louis DN, Liberski P. Pleomorphic xanthoastrocytoma. In: Louis DN, Wiestler OD, Cavenee WK, editors. *WHO Classification of Tumors of the Central Nervous System*. Lyon: IARC Press; 2007. p. 22-4.
  4. Geddes JF, Swash M. Hugh Cairns, Dorothy Russell and the first pleomorphic xanthoastrocytoma? *Br J Neurosurg* 1999;13:174-7.
  5. Fernandez D, Muranjan MN, Bavdekar SB, Kantharia V, Shenoy A. Pleomorphic xanthoastrocytoma. *Indian Pediatr* 2001;38:297-300.
  6. Perkins SM, Mitra N, Fei W, Shinohara ET. Patterns of care and outcomes of patients with pleomorphic xanthoastrocytoma: A SEER analysis. *J Neurooncol* 2012;110:99-104.
  7. Rao AA, Laack NN, Giannini C, Wetmore C. Pleomorphic xanthoastrocytoma in children and adolescents. *Pediatr Blood Cancer* 2010;55:290-4.
  8. Im SH, Chung CK, Kim SK, Cho BK, Kim MK, Chi JG. Pleomorphic xanthoastrocytoma: A developmental glioneuronal tumor with prominent glioproliferative changes. *J Neurooncol* 2004;66:17-27.
  9. Paulus W, Lisle DK, Tonn JC, Wolf HK, Roggendorf W, Reeves SA, *et al.* Molecular genetic alterations in pleomorphic xanthoastrocytoma. *Acta Neuropathol* 1996;91:293-7.
  10. Gil-Gouveia R, Cristino N, Farias JP, Trindade A, Ruivo NS, Pimentel J. Pleomorphic xanthoastrocytoma of the cerebellum: Illustrated review. *Acta Neurochir (Wien)* 2004;146:1241-4.
  11. Smirniotopoulos JG. The new WHO CNS tumor classification. *Neuroimaging Clinics N Am* 1999;9:595-613.
  12. Gonçalves VT, Reis F, Queiroz Lde S, França Jr M. Pleomorphic xanthoastrocytoma: Magnetic resonance imaging findings in a series of cases with histopathological confirmation. *Arq Neuropsiquiatr* 2013;71:35-9.
  13. Yu S, He L, Zhuang X, Luo B. Pleomorphic xanthoastrocytoma: MR imaging findings in 19 patients. *Acta Radiol* 2011;52:223-8.
  14. Reifenberger G, Kaulich K, Wiestler OD, Blümcke I. Expression of the CD34 antigen in pleomorphic xanthoastrocytomas. *Acta Neuropathol* 2003;105:358-64.
  15. Macaulay RJ, Jay V, Hoffman HJ, Becker LE. Increased mitotic activity as a negative prognostic indicator in pleomorphic xanthoastrocytoma. Case report. *J Neurosurg* 1993;79:761-8.
  16. Fouladi M, Jenkins J, Burger P, Langston J, Merchant T, Heideman R, *et al.* Pleomorphic xanthoastrocytoma: Favorable outcome after complete surgical resection. *Neuro Oncol* 2001;3:184-92.
  17. Nakajima T, Kumabe T, Shamoto H, Watanabe M, Suzuki H, Tominaga T. Malignant transformation of pleomorphic xanthoastrocytoma. *Acta Neurochir (Wien)* 2006;148:67-71.
  18. Dickerman RD, Anderson A, Morgan J, Cohen AJ. Diffuse malignant transformation of pleomorphic xanthoastrocytoma 21 years later: A matter of time? *Acta Neurochir (Wien)* 2006;148:95-7.