

CASE REPORT

Unusual presentation of an intraventricular hydatid cyst as a bleeding cystic tumor: A case report and brief review

Sumyra Khurshid Qadri, Nissar Hussain Hamdani¹, Abdul Rashid Bhat², Mohammad Iqbal Lone

Departments of Pathology, ¹General surgery and ²Neurosurgery, Sher-i-Kashmir Institute of Medical Sciences, Soura, Srinagar, Jammu and Kashmir, India

ABSTRACT

Hydatid cysts constitute only 2% of all intracranial masses, commonly involve parenchyma and very rarely ventricles. Here, we report an unusual case of a primary, isolated intraventricular hydatid cyst that mimicked a tumor and presented as intraventricular hemorrhage with hydrocephalus in a boy, causing a diagnostic dilemma. Although, preoperative modalities like computed tomography, magnetic resonance image and serology generally help in establishing the diagnosis, but hydatid cysts with unusual localizations and atypical imaging findings may complicate the diagnosis and need be considered in the differential diagnosis of all cystic masses in all anatomic locations, especially in endemic areas, so as to reduce the patient morbidity and mortality.

Key words: Cystic tumor, echinococcosis, intraventricular hydatid cyst

Introduction

Hydatidosis or echinococcosis, is a zoonotic disease caused by the infestation of the larval form (hydatid cyst) of tapeworm, *Echinococcus*. It is endemic in many countries including India.^[1-4] Liver is the most frequently involved organ (75%), followed by lungs (15%).^[1,5] Rarely, (1.6-5.2% cases), the central nervous system (CNS) is affected, where the cysts occupy mostly parenchyma and very rarely ventricles.^[1,2,6-12] We report a case of isolated, solitary, primary intraventricular hydatid cyst in a boy that mimicked a bleeding cystic tumor and presented as intraventricular hemorrhage with hydrocephalus. None of the earlier reported cases has such atypical presentation.

Case Report

A 24-year-old male patient presented with complaints of tinnitus and decreased hearing for 1-month, headache and vertigo for

15 days, and fever, altered sensorium, nausea, and vomiting for 2 days. On examination, his general condition was poor. He was febrile, drowsy and disoriented; pupils were bilaterally equal and reactive to light. Fundoscopic examination showed bilateral papilledema. Hematological examination revealed raised erythrocyte sedimentation rate (60 mm/h) and leukocyte count of 18,000 mm³. Both computed tomography (CT) scan [Figure 1] and magnetic resonance image (MRI) head [Figures 2 and 3] were of the impression of an intraventricular cystic tumor, with a speckled calcification with intraventricular hemorrhage and hydrocephalus. Radiological examination of the thorax and abdomen did not reveal any other cyst or tumor. In view of the serious neurological condition of the patient, surgery was performed.

A right parieto-occipital craniotomy with posterior parietal transcortical transventricular approach, with near total removal of mass, was done. The mass was yellow-brown, highly vascular, soft, cystic, suctionable, attached to the choroid plexus in the trigone of the lateral ventricle, extending

Access this article online	
Quick Response Code:	Website: www.asianjns.org
	DOI: 10.4103/1793-5482.145541

Address for correspondence:

Dr. Sumyra Khurshid Qadri, Department of Pathology, Sher-i-Kashmir Institute of Medical Sciences, Srinagar - 190 011, Jammu and Kashmir, India.
E-mail: drsumairaqadri@gmail.com

This is an open access article distributed under the terms of the Creative Commons Attribution-NonCommercial-ShareAlike 3.0 License, which allows others to remix, tweak, and build upon the work non-commercially, as long as the author is credited and the new creations are licensed under the identical terms.

For reprints contact: reprints@medknow.com

How to cite this article: Qadri SK, Hamdani NH, Bhat AR, Lone MI. Unusual presentation of an intraventricular hydatid cyst as a bleeding cystic tumor: A case report and brief review. Asian J Neurosurg 2017;12:324-7.

in almost whole of the lateral ventricle and third ventricle. Intraoperative crush biopsy revealed only blood admixed with some normal brain tissue, and was inconclusive. The mass was very vascular and bleed profusely during surgery. Hence, the patient required substantial blood transfusions both intraoperatively and postoperatively. The histopathological examination of the resected mass revealed multiple laminated membranous bits of hydatid cyst scattered everywhere, with areas of hemorrhage and normal brain tissue [Figure 4]. There was no evidence of any neoplastic pathology, thus, confirming the diagnosis of an intraventricular hydatid disease.

Postoperatively, the patient showed significant neurological improvement. He was given broad spectrum antibiotics, anticonvulsants and steroids. Later on, albendazole was added for 4 months after histopathology revealed hydatid cyst. The patient is on follow-up for the last 3 months, and there is no evidence of any recurrence.

Discussion

In 50-75% of cases, CNS hydatidosis is found in the pediatric and adolescent age groups.^[6] CNS hydatid cysts are commonly

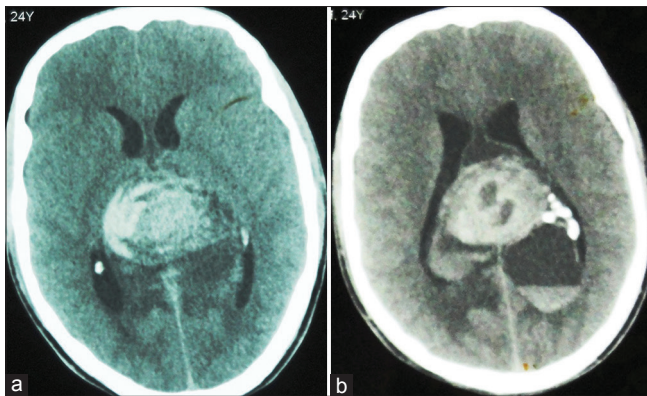


Figure 1: (a) Noncontrast computed tomography brain shows midline, third ventricular hyperdense mass with diversion of the posterior horn of lateral ventricle. (b) Noncontrast CT brain shows intraventricular, heterogeneous hyperdense calcified mass with ventricular bleed blocking foramen of monro and hydrocephalus

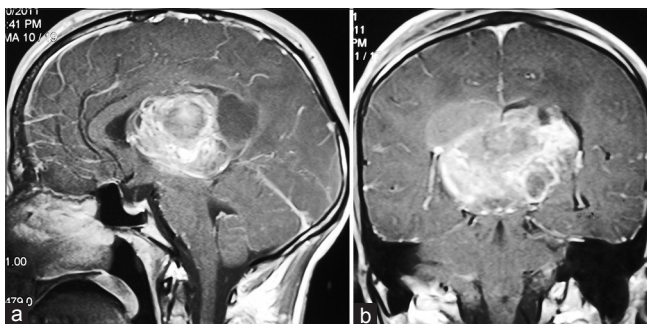


Figure 3: (a) Postcontrast sagittal T1-weighted image shows multiple small cysts within a single large intraventricular enhancing mass. (b) Postcontrast coronal T1-weighted image shows partially enhancing mass with multiple cystic lesions in third and lateral ventricle

parenchymal, located in the supratentorial region, and involve the territory of the middle-cerebral artery, especially, the parietal lobe.^[1-3,6,8] Hematogenous spread of the disease can involve unusual sites in the brain.^[8] A few cases of intracranial hydatid cysts with unusual locations such as parasellar epidural space, sella, cavernous sinus, cerebellum, thalamus and pons, have been reported.^[1] Although involvement of the

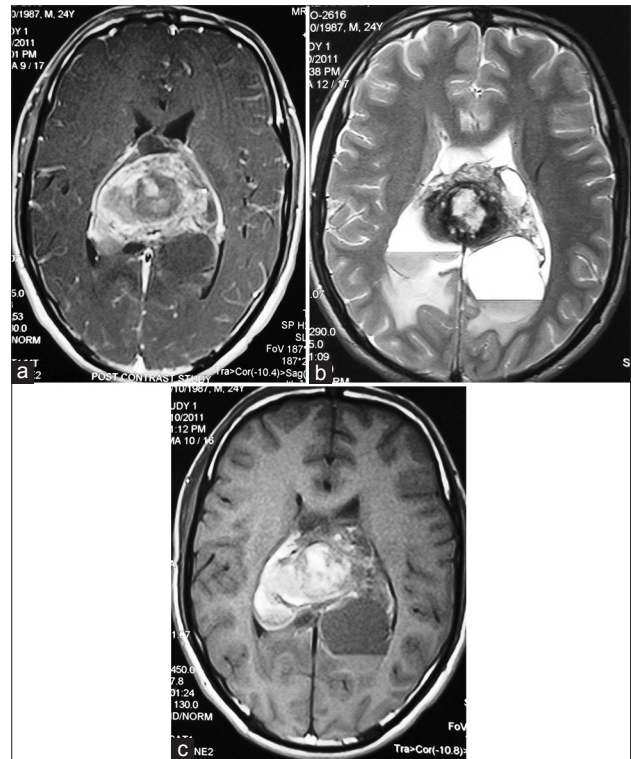


Figure 2: (a) Postcontrast axial T1-weighted image shows multiple intraventricular large cysts with hemorrhage. (b) Axial T2-weighted image shows hyperintense, large, multiple cystic intraventricular lesion with central hypointense lesion locking a hyperintense double cyst. (c) Noncontrast axial T1-weighted image shows midline, intraventricular heterogeneous mass with cystic appearance on the left posterior aspect

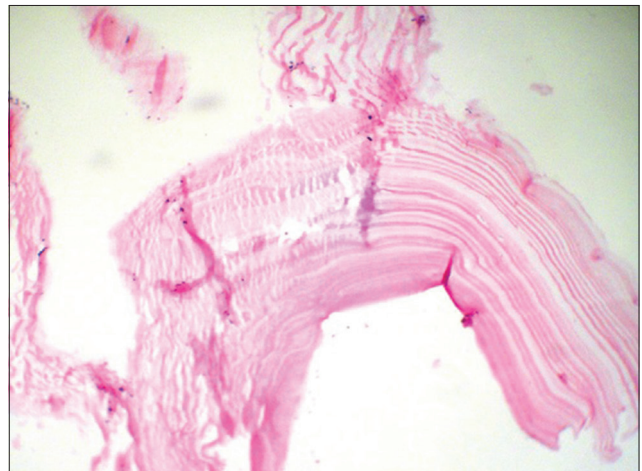


Figure 4: H and E showing eosinophilic, laminated membranes of hydatid cyst

ventricular system is found in 15-30% of neurocysticercosis cases, it is extremely rare in hydatidosis.^[8] Khaldi *et al.* in a large series of 155 cases of brain hydatosis hospitalized between 1965 and 1998, reported only three cases of intraventricular hydatid cysts.^[4]

Hydatid cysts constitute about 2% of all intracranial space occupying lesions even in countries in which the disease is endemic.^[2,3,5] The incidence of intracranial hydatid in India is 0.2%.^[1] Cysts in the CNS are frequently found in association with systemic dissemination particularly to the liver (65%) and lungs (25%). However, isolated involvement of the brain or spinal cord has also been observed, especially in children.^[7] In our patient also, there was no radiological or clinical evidence of hydatid disease elsewhere in the body.

Cerebral hydatid cyst is generally solitary but may be multiple when it ruptures spontaneously or due to trauma or surgery; the cyst is always solitary when the primary site is in the brain.^[2-4] Solitary intraventricular hydatid cyst, as seen in our case, was reported by Kamath *et al.* in a 6-year-old boy.^[1] Hydatid cyst may be unilocular caused by *Echinococcus granulosus* or multilocular caused by *Echinococcus multilocularis*. *E. granulosus* is the more common type, whereas *E. multilocularis* is less common, but more invasive, mimicking a malignancy.^[3]

Depending on the site and the size of the hydatid cyst, patients may present with focal neurological deficit and features of raised intracranial pressure.^[1] In adults, focal neurological deficit such as hemiparesis, hemianopia, speech disorders or epileptic seizures are usually first to appear, while in children the presentation is dominated by the signs of raised intracranial pressure.^[6,13,14] Postural changes may initiate changes in cyst location in the ventricular system, and they may be the cause of hydrocephalus.^[6] Our patient presented with features of raised intracranial pressure.

For the planning of appropriate surgical management and for a better prognosis, it is important to be aware of intracranial hydatosis preoperatively. Imaging modalities like CT and MRI, are not only diagnostically important but also helpful in the treatment. By CT scanning, the most superficial part of the cyst can be identified for a cortical incision, thus minimizing the risk of rupturing the cyst.^[15] In our case, the radiological findings were not typical of a unilocular hydatid cyst and the impression of an intraventricular cystic tumor was made preoperatively.

Spontaneous rupture of cerebral cysts into the ventricles or mass effect of cysts on the cerebrospinal fluid pathways may produce hydrocephalus.^[2] In our case, occurrence of fever, altered sensorium, nausea and vomiting 2 days before admission, superadded on the initial complaints of headache and vertigo suggests the possibility of rupture of hydatid cyst

within the ventricle. Adherence of the cystic mass to choroid the plexus and its high vascularity, confirmed intraoperatively, might have caused intraventricular hemorrhage, and hydrocephalus due to raised intracranial pressure following spontaneous cyst rupture.

To the best of our knowledge, this is the first-case report in which an isolated, solitary, primary intraventricular hydatid cyst in a young male, with no relevant past history and no evidence of hydatid cyst elsewhere in the body, mimicked a bleeding cystic tumor and presented as intraventricular hemorrhage with hydrocephalus.

The clinicians, radiologists and pathologists are required to express a high index of suspicion and familiarity with imaging findings while managing all intracranial cystic masses, so that a proper plan of management is formulated, and hydatid cysts can be excised in toto without rupture, avoiding the complications arising, as a result, of cyst rupture like anaphylactic reaction and dissemination of hydatid cysts. Furthermore, such patients should be carefully followed postoperatively for any recurrence.

Conclusion

Echinococcosis is a common disease in our country that which usually involves liver and lungs. Although, preoperative modalities like CT, MRI and serology, can generally help establish the diagnosis of hydatid disease, but hydatid cysts with unusual localizations and atypical imaging findings may complicate the diagnosis and need be considered in the differential diagnosis of all cystic masses in all anatomic locations, especially, when they occur in endemic areas so as to reduce the patient morbidity and mortality.

Financial support and sponsorship

Nil.

Conflicts of interest

There are no conflicts of interest.

References

1. Kamath SM, Mysorekar VV, Rao SG, Varma RG. Intraventricular hydatid cyst in a child. *Indian J Pathol Microbiol* 2009;52:571-2.
2. Diren HB, Ozcanli H, Boluk M, Kilic C. Unilocular orbital, cerebral and intraventricular hydatid cysts: CT diagnosis. *Neuroradiology* 1993;35:149-50.
3. Polat P, Kantarci M, Alper F, Suma S, Koruyucu MB, Okur A. Hydatid disease from head to toe. *Radiographics* 2003;23:475-94.
4. Khaldi M, Mohamed S, Kallel J, Khouja N. Brain hydatidosis: Report on 117 cases. *Childs Nerv Syst* 2000;16:765-9.
5. Engin G, Acunas B, Rozanes I, Acunas G. Hydatid disease with unusual localization. *Eur Radiol* 2000;10:1904-12.
6. Güvenç G, Özdemir N, Yildirim L. Successful treatment of hydatid cyst into the lateral ventricle with Dowling's technique in an adult patient. *J Neurol Sci Turk* 2011;28:265-9.
7. Benomar A, Yahyaoui M, Birouk N, Vidailhet M, Chkili T. Middle cerebral artery occlusion due to hydatid cysts of myocardial and intraventricular cavity cardiac origin. Two cases. *Stroke* 1994;25:886-8.

8. Evliyaoglu C, Keskil S. Possible spontaneous "birth" of a hydatid cyst into the lateral ventricle. *Childs Nerv Syst* 2005;21:425-8.
9. Maurya P, Singh VP, Prasad R, Bhaikhel KS, Sharma V, Kumar M. Intraventricular hydatid cyst causing entrapped temporal horn syndrome: A case report and review of literature. *J Pediatr Neurosci* 2007;2:20-2.
10. Guzel A, Tatli M, Maciaczyk J, Altinors N. Primary cerebral intraventricular hydatid cyst: A case report and review of the literature. *J Child Neurol* 2008;23:585-8.
11. Valentino V. Combined intraventricular and intracerebral hydatid cysts: report of a case. *Radiology* 1959;73:250-2.
12. Mircevski M, Mircevska D, Boyadziev I, Basevska R. Voluminous intraventricular hydatid cysts in children. *Neurochirurgie* 1985;31:425-8.
13. Rudwan MA, Khaffaji S. CT of cerebral hydatid disease. *Neuroradiology* 1988;30:496-9.
14. Miabi Z, Hashemi H, Ghaffarpour M, Ghelichnia H, Media R. Clinicoradiological findings and treatment outcome in patients with intracranial hydatid cyst. *Acta Med Iran* 2005;43:359-64.
15. Karadag O, Gürelik M, Ozüm U, Göksel HM. Primary multiple cerebral hydatid cysts with unusual features. *Acta Neurochir (Wien)* 2004;146:73-7.