

Single port microsurgical technique for excision of third ventricular colloid cysts

Manish Vaish, Rana Patir, Rahul Prasad, Amit Agrawal¹

Department of Neurosurgery, New Delhi, ¹Department of Neurosurgery, Narayana Medical College Hospital, Chinthareddypalem, Nellore, Andhra Pradesh, India

ABSTRACT

Introduction: Colloid cysts are benign space-occupying lesions that account for 0.5-1.0% of brain tumors and arise from the velum interpositum or the choroid plexus of the third ventricle.

Material and Methods: We are describing a modified surgical technique that combines the positive attributes of being minimalistic, while retaining the effectiveness of microsurgery. In all 20 consecutive symptomatic patients with a preoperative magnetic resonance imaging (MRI) diagnosis of colloid cyst who came to the senior author between 2008 and 2011 were included in the study. The patient was kept supine with the head positioned neutrally in the sagittal plane and neck flexed at 20°. The tube of a 5 ml plastic syringe having an external diameter of 13 mm and an internal diameter of 12.6 mm was cut toward the nozzle end to the appropriate length depending upon the cortical thickness measured on the preoperative MRI.

Results: The average operative time was around 90 min with maximum of 120 min. None of the patients had seizures preoperatively or postoperatively and in all cases antiepileptic medication could be stopped after 3-6 month of surgery. Two patients had short-term memory impairment which returned to near normal by 1-year following surgery.

Conclusion: A volume of 5 ml plastic syringe port technique decreases the operative morbidity and operative time. The wider corridor of working makes the simultaneously maneuverability of two surgical instruments feasible enhancing safety and completeness of excision.

Key words: Approach, colloid cysts, single port, third ventricle

Introduction

Colloid cysts are benign space-occupying lesions that account for 0.5-1.0% of brain tumors and arise from the velum interpositum or the choroid plexus of the third ventricle.^[1-3] These lesions are able to produce symptomatic obstruction of the foramina of monro with resultant hydrocephalus and nonlocalizing symptoms.^[1,4-9] Although since long, it has been recognized that a total removal should be the goal of surgery^[10] the optimal surgical management of colloid cysts continues to be a matter of debate.^[11] Microsurgical excision exposures

more normal brain to surgery related trauma, while endoscopic surgery carries a greater risk of incomplete removal. We are describing a modified surgical technique that combines the positive attributes of being minimalistic while retaining the effectiveness of microsurgery.

Materials and Methods

Patient selection

In all 20 consecutive symptomatic patients with a preoperative magnetic resonance imaging (MRI) diagnosis of colloid cyst who came to the senior author between 2008 and 2011 were included in the study [Table 1]. Twenty cases were operated using a single port fashioned from a 5 ml syringe. There were 7 male and 13 female patients. The age varied between 15 and 59 years with a mean age of 32.9. Fifteen patients had a primary complaint of headache or headache and vomiting. The other symptom included memory loss ($n = 4$), giddiness ($n = 4$), urinary incontinence ($n = 1$) and sudden blackouts ($n = 1$). Eighteen patients had associated hydrocephalus. Two patients underwent preoperative external ventricular drainage (EVD) as an emergency measure. One patient had undergone an emergency ventriculoperitoneal shunt prior to admission for elective surgery. Size of cyst was not measured in all cases. In

Access this article online

Quick Response Code:



Website:

www.asianjns.org

DOI:

10.4103/1793-5482.146599

Address for correspondence:

Dr. Manish Vaish, Senior consultant Neurosurgeon, Fortis hospital, Sector 62 Noida, Uttar Pradesh, India.
E-mail: drmanishvaish@gmail.com

Table 1: Clinical details of the patients

Case	Age	Sex	Presentation	EVD	Navigation	Stay	Outcome
1	39	Female	Headache Vomiting	No	No	3	Good
2	35	Female	Headache Vomiting	No	No	5	Good
3	15	Male	Headache Vomiting	No	No	3	Good
4	41	Female	Unconsciousness	Yes	No	5	Good
5	30	Female	Headache Vomiting	No	No	4	Good
6	18	Male	Headache Vomiting	No	No	3	Good
7	39	Male	Headache Vomiting	No	No	4	Good
8	39	Female	Headache Vomiting	No	No	3	Good
9	25	Female	Headache Vomiting	No	No	3	Good
10	49	Male	Headache Vomiting	No	No	4	Good
11	30	Female	Headache Vomiting	No	No	3	Good
12	23	Male	Headache Vomiting	No	No	3	Good
13	48	Male	Unconsciousness	Yes	No	6	Good
14	15	Female	Headache Vomiting	No	Yes	4	Good
15	59	Female	Giddiness incontinence memory disturbance	No	No	7	Good
16	28	Male	Reduced memory difficulty in writing headache	No	No	5	Good
17	45	Female	Reduced memory	No	No	4	Good
18	18	Female	Headache	No	No	3	Good
19	29	Female	Altered sensorium	Yes	No	3	Good
20	33	Female	Headache reduced memory sudden blackout	No	No	4	Good

EVD – External ventricular drainage

two patients navigation was needed to access normal sized ventricles. Noncontrast computed tomography head was done in all the patients on the first postoperative day and MRI after 3-6 month of surgery.

Technical detail

The patient was kept supine with the head positioned neutrally in the sagittal plane and neck flexed at 20°. All the patients were loaded with standard doses of phenytoin or sodium valproate and continued on maintenance doses for 3-6 month. If the patient was on preoperative EVD, it was blocked 6-8 h prior to surgery. A 2.5 cm diameter frontal craniotomy was made 3 cm anterior to the coronal suture in the midpupillary line. The craniotomy was made either on the nondominant side or in cases of asymmetric ventriculomegaly, on the side of the larger ventricle. Dural

hitch stitches were taken, and dura opened in a cruciate manner. The point of entry was selected away from any major cortical vein. The tube of a 5 ml plastic syringe having an external diameter of 13 mm and an internal diameter of 12.6 mm was cut toward the nozzle end to the appropriate length depending upon the cortical thickness measured on the preoperative MRI [Figure 1]. The syringe was put over a closely fitting teflon trochar and guided into the frontal horn. The hub of the tube prevented the tube from slipping into the ventricle. Where a small ventricle was encountered, image guidance was used (Brainlab neuro-navigation system). The tracking attachment was fixed to the trochar which was then registered for navigation. Operating microscope was brought in place. The ventricle was emptied of cerebrospinal fluid (CSF). A 5 mm interventriculostomy was routinely performed for improving visibility as well as preventing ipsilateral hydrocephalus in advent of scarring at the foramen of monro. The instruments used included no 1 and 2 angled suction cannula, a 12 cm long and 1 mm tipped bipolar cautery, bayonet dissectors and pistol grip fine scissors. The foramen of monro and colloid cyst was visualized. The end of a lumbar puncture needle was used to puncture the cyst wall. The opening was further widened with scissors and the contents emptied. Cyst was then dissected using sharp dissection and bipolar cautery in the usual bimanual manner. Frequently the part of the cyst densely adherent to the third-ventricle roof was managed by coagulating the cyst wall. After excising the cyst the field was thoroughly irrigated, and the port withdrawn slowly to visualize and secure any bleeding point along the tract. Dura was closed primarily, the bone position with miniplates and skin approximated in two layers. The preoperative EVD if present was removed in all cases.

Results

The average operative time was around 90 min with maximum of 120 min. All the patients were kept overnight in the Intensive Care Unit and discharged on postoperative day 2-4. Intraoperatively gross total tumor excision was achieved in all the patients. This included the patients where the cyst was densely adherent to the roof of the third ventricle where the cyst was managed by bipolar coagulation. All of the 20 patients who were operated by this new technique had no residual disease on postoperative MRI after 3-6 month. All the patients showed a reduction of the size of ventricles on post-operative imaging [Figure 2]. Three patients presented to us with altered sensorium or unconsciousness, in these patients EVD was placed on an emergency basis, and all these patients showed improvement in sensorium after CSF diversion. EVD removal following cyst removal did not cause any problem in the postoperative period. None of the patients had seizures preoperatively or postoperatively and in all cases antiepileptic medication could be stopped after 3-6 month of surgery. Two

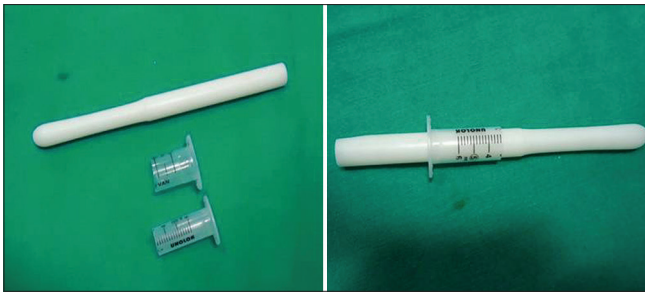


Figure 1: The tube of a 5 ml plastic syringe having an external diameter of 13 mm and an internal diameter of 12.6 mm with teflon trochar

patients had short-term memory impairment which returned to near normal by 1-year following surgery.

Discussion

Colloid cyst of the third ventricle is a relatively rare benign intracranial tumor.^[5,11,12] Early detection and total excision of symptomatic lesions is the mainstay of treatment^[5,11-14] as it carries an excellent prognosis with low risk of recurrence after radical resection.^[5] Their deep midline location makes surgical approach to the colloid cysts challenging.^[5,11,15,16] The larger amount of exposed brain carries with it an increased risk of postoperative morbidity. On the other hand, endoscopy offers superior visualization,^[17-19] which coupled with reduced retraction translates to a reduced potential for injury to the brain. Grondin *et al.*^[20] reviewed the literature since 1980 comparing the outcome results of both approaches. A total of 1039 individual cases, including their own series were reviewed in the study. They found that the incidences of major and minor complications were more in microsurgically treated patients. There was a combined complication rate of 32.2% in the microsurgical group and 8.3% in the endoscopic group which was found to be statistically significant. This maintained statistical significance when classifying complications as major and minor. There was a 3.0% peri-operative mortality associated with microsurgical resection, compared to no deaths in the endoscopic group. There were, however, two features that were more favorable in the microsurgically treated patients. There was a significantly higher rate of gross total resection in the microsurgical group compared with the endoscopic group (96% vs. 87%). Furthermore, the reported recurrence rate was higher in the endoscopic group than in the microsurgical group (3.3% vs. 0.6%). Grondin *et al.*^[20] from the review estimated 3-4% recurrence for endoscopically treated group with a mean time of recurrence of around 5 years. They also found shunt dependency in 1.9% of endoscopically treated and 6.4% of microsurgically treated group.

Operative time and length of hospital stay also have been shown to be significantly reduced with endoscopic approach.^[12,20,21] Grondin *et al.*^[20] in their own series of endoscopically treated patients, the average operative time

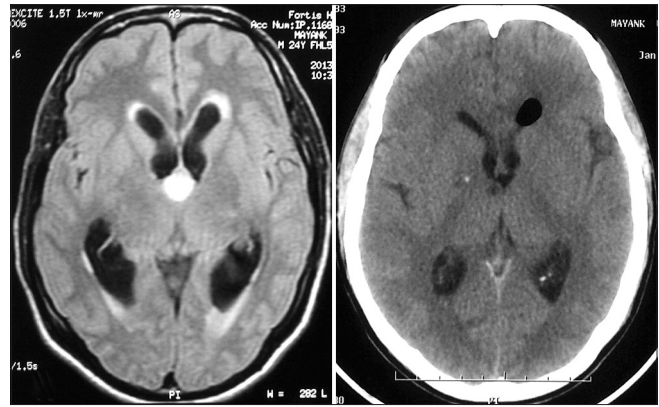


Figure 2: Preoperative and postoperative images showing complete excision the colloid cyst

was 104 min and length of hospital stay was 3.8 days. In King *et al.*^[22] series the average operating time was 94 min, and average total hospital stay was 2.3 days. The advantages of endoscopic surgery in terms of less operative time, short duration of hospital stay, less morbidity and fewer complications, all were achieved by our technique. The average operative time in our technique was 90 min, and average hospital stay was 3.9 days which comparable with the endoscopic surgery results. There were no complications or any postoperative morbidity. The advantages of open microsurgical excision were also achieved in our technique in terms of gross total excision. Endoscopic excision of third ventricular colloid cysts is safe, effective and leads to fewer complications than an open, microsurgical approach and can be recommended as an alternative to open microsurgery.^[12,23] To our knowledge the port diameter is the smallest described for microsurgery. The use of this syringe port technique allows the surgeon to use both hands simultaneously. Wider corridor for working makes maneuverability of two surgical instruments simultaneously feasible. In association to that, the port can itself be toggled a bit in all directions according to the need. The use of a 4 mm endoscope through a similar size port severely constrains the movements of instruments. The use of a port in small size ventricle has not been a difficulty in the era of neuro-navigation.

Conclusion

A volume of 5 ml plastic syringe port technique decreases the operative morbidity and operative time because of the smaller craniotomy, less tissue dissection and elimination of retraction to the brain. The wider corridor of working makes the simultaneously maneuverability of two surgical instruments feasible enhancing safety and completeness of excision.

References

1. Charalampaki P, Filippi R, Welschehold S, Perneczky A. Endoscope-assisted removal of colloid cysts of the third ventricle. *Neurosurg Rev* 2006;29:72-9.

2. Batnitzky S, Sarwar M, Leeds NE, Schechter MM, Azar-Kia B. Colloid cysts of the third ventricle. *Radiology* 1974;112:327-41.
3. Little JR, MacCarty CS. Colloid cysts of the third ventricle. *J Neurosurg* 1974;40:230-5.
4. Pecker J, Guy G, Scarabin J, Vinken P, Bruyn G. Third ventricle tumours, including tumours of the septum pellucidum, colloid cysts and subependymal glomerate astrocytoma. *Tumours of the Brain and Skull, Part II Handbook of Clinical Neurology*. Vol. 17. 1974. p. 440-89.
5. Desai KI, Nadkarni TD, Muzumdar DP, Goel AH. Surgical management of colloid cyst of the third ventricle – A study of 105 cases. *Surg Neurol* 2002;57:295-302.
6. Nitta M, Symon L. Colloid cysts of the third ventricle. A review of 36 cases. *Acta Neurochir (Wien)* 1985;76:99-104.
7. de Witt Hamer PC, Versteegen MJ, De Haan RJ, Vandertop WP, Thomeer RT, Mooij JJ, *et al.* High risk of acute deterioration in patients harboring symptomatic colloid cysts of the third ventricle. *J Neurosurg* 2002;96:1041-5.
8. Byard RW, Moore L. Sudden and unexpected death in childhood due to a colloid cyst of the third ventricle. *J Forensic Sci* 1993;38:210-3.
9. Ryder JW, Kleinschmidt-DeMasters BK, Keller TS. Sudden deterioration and death in patients with benign tumors of the third ventricle area. *J Neurosurg* 1986;64:216-23.
10. Dandy WE. *Benign Tumors in the Third Ventricle of the Brain: Diagnosis and Treatment*. Charles C. Thomas Publisher; 1933.
11. Camacho A, Abernathy CD, Kelly PJ, Laws ER Jr. Colloid cysts: Experience with the management of 84 cases since the introduction of computed tomography. *Neurosurgery* 1989;24:693-700.
12. Horn EM, Feiz-Erfan I, Bristol RE, Lekovic GP, Goslar PW, Smith KA, *et al.* Treatment options for third ventricular colloid cysts: Comparison of open microsurgical versus endoscopic resection. *Neurosurgery* 2007;60:613-8.
13. Bergsneider M. Complete microsurgical resection of colloid cysts with a dual-port endoscopic technique. *Neurosurgery* 2007;60:ONS33-42.
14. Teo C. Complete endoscopic removal of colloid cysts: Issues of safety and efficacy. *Neurosurg Focus* 1999;6:e9.
15. Schirmer CM, Heilman CB. Complete endoscopic removal of colloid cyst using a nitinol basket retriever. *Neurosurg Focus* 2011;30:E8.
16. Zohdi A, El Kheshin S. Endoscopic approach to colloid cysts. *Minim Invasive Neurosurg* 2006;49:263-8.
17. Decq P, Le Guerinel C, Brugières P, Djindjian M, Silva D, Kéravel Y, *et al.* Endoscopic management of colloid cysts. *Neurosurgery* 1998;42:1288-94.
18. Schroeder HW, Gaab MR. Endoscopic resection of colloid cysts. *Neurosurgery* 2002;51:1441-4.
19. Chen CC, Chung HC, Lee HC, Cho DY. Single-port endoscopic removal of intraventricular hemorrhage or tumor of the brain: A technical note. *Mid Taiwan J Med* 2008;13:100-6.
20. Grondin RT, Hader W, MacRae ME, Hamilton MG. Endoscopic versus microsurgical resection of third ventricle colloid cysts. *Can J Neurol Sci* 2007;34:197-207.
21. Mishra S, Chandra PS, Suri A, Rajender K, Sharma BS, Mahapatra AK. Endoscopic management of third ventricular colloid cysts: Eight years' institutional experience and description of a new technique. *Neurol India* 2010;58:412-7.
22. King WA, Ullman JS, Frazee JG, Post KD, Bergsneider M. Endoscopic resection of colloid cysts: Surgical considerations using the rigid endoscope. *Neurosurgery* 1999;44:1103-9.
23. Stachura K, Libionka W, Moskala M, Krupa M, Polak J. Colloid cysts of the third ventricle. Endoscopic and open microsurgical management. *Neurol Neurochir Pol* 2009;43:251-7.

How to cite this article: Vaish M, Patir R, Prasad R, Agrawal A. Single port microsurgical technique for excision of third ventricular colloid cysts. *Asian J Neurosurg* 2014;9:189-92.

Source of Support: Nil, **Conflict of Interest:** None declared.

Announcement

iPhone App



Download
**iPhone, iPad
application**



A free application to browse and search the journal's content is now available for iPhone/iPad. The application provides "Table of Contents" of the latest issues, which are stored on the device for future offline browsing. Internet connection is required to access the back issues and search facility. The application is Compatible with iPhone, iPod touch, and iPad and Requires iOS 3.1 or later. The application can be downloaded from <http://itunes.apple.com/us/app/medknow-journals/id458064375?ls=1&mt=8>. For suggestions and comments do write back to us.