

CASE REPORT

Diffuse neurofibroma of scalp

Sushil Kumar, S. Bhaskar¹, Amit Handa, Bharat Jindal²

Departments of Neurosurgery, St. Stephen's Hospital, Tis Hazari, ²Plastic Surgery, St. Stephen's Hospital, Tis Hazari, Delhi, ¹Neurosurgery, Ram Manohar Lohia Hospital, New Delhi, India

ABSTRACT

A 22-year-old man presented with a large, soft, compressible swelling in the right occipito-parietal region. Fine needle aspiration cytology revealed blood only. The lesion was excised and histopathology studies revealed it to be a diffuse neurofibroma.

Key words: Computed tomography, diffuse neurofibroma, scalp

Introduction

A diffuse neurofibroma is a variant of neurofibroma, most commonly involving the head and neck. It occurs in young adults. We came across such a case recently and it is being reported here because of its rarity and unusual features.

Case Report

A 22-year-old male presented with history of a slowly progressive painless swelling in the right parieto-occipital region since the last eight years. There was history of preceding trauma. On examination there was a large, 14 × 12 cms, non tender, compressible swelling with ill defined margins [Figure 1]. The swelling involved the skin and no bony abnormality could be felt underneath. There was no bruit over the mass. There were no café-au-lat spots over the body. FNAC done at another hospital revealed blood only. A computed tomography revealed a hypodense lesion, without enhancement after contrast administration [Figure 2]. According to the clinical and CT scan findings, a provisional diagnosis of subcutaneous venous hemangioma was made. At surgery, running sutures were passed around the swelling and a grayish pink soft vascular tissue was separated from the pericranium and galea. At places, the lesion was found to be infiltrating the skin. Redundant skin was excised. Post operatively, the skin

necrosed at places and was treated with antibiotics and dressings. Histopathology showed elongated cells arranged in haphazard fashion. Wagner Meissner bodies and pigment laden macrophages were seen [Figure 3]. Interspersed adnexal structures were present. Fibro-adipose tissue with collagen, and spindle cells bearing wavy nuclei were also seen. Some nerve bundles were found in the tumor. The final histopathological diagnosis was subcutaneous diffuse neurofibroma.

Discussion

Neurofibromas are well-known benign tumors of the peripheral nerve sheath. According to their growth patterns, they may be categorized as local, plexiform and diffuse types. Diffuse neurofibromas occur most commonly among children and young adults. They have a slight predilection for trunk, head and neck and the limbs and may become very large as seen in our case. A majority of the diffuse neurofibromas (90%) are isolated lesions, not associated with neurofibromatosis type I.^[1,2] In 10% of the patients, diffuse neurofibromas may have neurofibromatosis.^[3] Diffuse

Access this article online	
Quick Response Code:	Website: www.asianjns.org
	DOI: 10.4103/1793-5482.146633

Address for correspondence:

Dr. Amit Handa, St. Stephen's Hospital, Tis Hazari, Delhi - 110 054, India. E-mail: dramithanda@yahoo.com

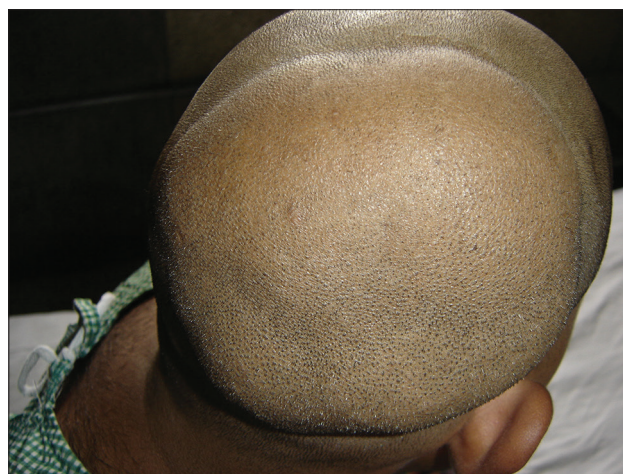

Figure 1: Photograph showing a large parieto-occipital swelling of the scalp

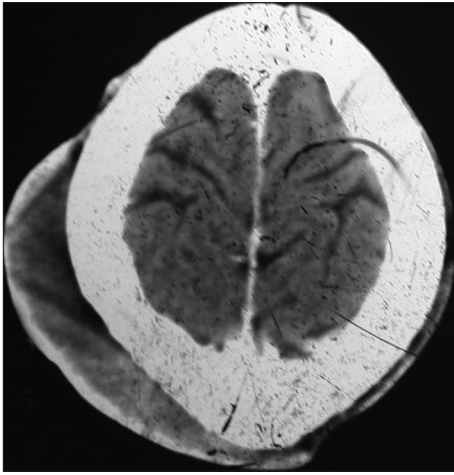


Figure 2: Computed tomography showing hypodense extra-calvarial mass with no enhancement

neurofibromas are poorly circumscribed non-encapsulated tumors and typically involve the subcutaneous tissue down to the level of the fascia.^[1] They are ill-defined and infiltrate the dermis and connective tissue sparing the skin appendages as seen in our patient as well.^[2,4]

The lesion has also been termed paraneurofibroma, indicating the extension of the tumor beyond the confines of the perineurium.^[5] Intracranial extension of the extracranial variety has also been reported.^[6] These lesions are highly vascular and because of their infiltrative nature preclude total excision. Lin *et al.* (2000) suggested ways to control bleeding: (i) Hypotensive anesthesia. (ii) Preliminary suture around the tumor and (iii) Ligation of the feeding vessels.^[7] The latter two ways were used by us to control the bleeding. Rarely, the neurofibroma may suddenly increase in size due to hemorrhage^[8] Pre-operative angiography and superselective embolization prevent massive bleeding but it does not provide satisfactory results because these tumors tend to revascularize quickly.^[9] Tung *et al.* (1997) found that ligation of the external carotid artery failed to control the massive bleeding. Kwak *et al.* (2006) suggested serial excision of the lesion to overcome the massive bleeding, which can occur despite pre-operative embolization and ligation of the feeder vessels. In our patient, as the lesion did not show enhancement on contrast CT, we did not contemplate pre-operative embolization and preferred to carry out single stage surgery, with the use of running suture around the lesion along with ligation of the feeding vessels. Reconstruction of the defect caused by wide excision of the lesion can be accomplished by expanded myo-cutaneous flaps and tissue expanders.^[10] Recurrence and potential development of neurofibromatosis warrants at least a yearly follow-up. Histopathology studies reveal that the lesion is usually composed of elongated, spindle shaped cells with round nuclei, within a loose matrix of fine fibrillary collagen. The presence of Meissner bodies is a characteristic feature

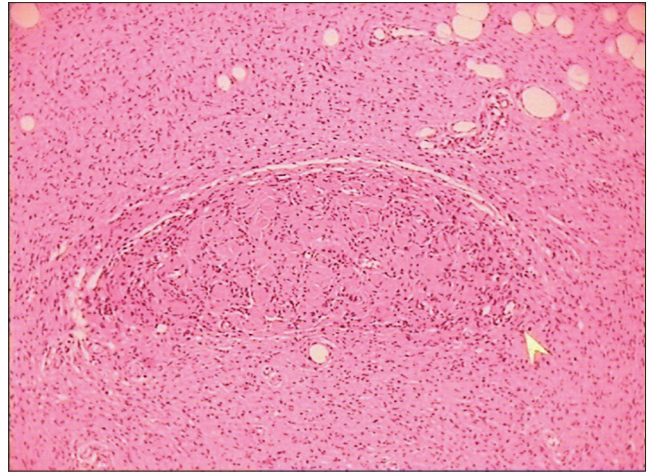


Figure 3: Microphotograph showing elongated cells arranged haphazardly, Wagner Meissner bodies and pigment laden macrophages (H and E, ×100)

but they may not always be present. It may be difficult to diagnose the condition clinically, as it may be mimicked by a hemangioma or cutaneous lymphoma and hence these entities should be considered in the differential diagnosis. Our case presented with a large progressively increasing swelling with a provisional diagnosis of a hemangioma. CT Scans usually show a hypodense lesion on pre-contrast images and marked enhancement after contrast administration.^[11] However, in the present case there was no enhancement with contrast. Localized thickening of the skin is due to tumor infiltration of the dermal layer.

Conclusion

Diffuse neurofibroma of the scalp should be kept in the differential diagnosis of any diffuse scalp swelling. Because of their highly vascular nature due care should be taken during excision.

References

- Huang GS, Huang CW, Lee HS, Chang WC, Lee CH, Lee NH *et al.* On the AJR view box. Diffuse neurofibroma of the arm: MR characteristics. *AJR Am J Roentgenol* 2005;184:1711-2.
- van Zuren EJ, Posma AN. Diffuse neurofibroma on the lower back. *J Am Acad Dermatol* 2003;48:938-40.
- Weiss SW, Goldblum JR. Benign tumors of peripheral nerves. In: Enzinger and Weiss, editors. *Soft tissue tumors*, 4th ed. St. Louis MO: Mosby: 2001. p. 1132-40.
- Khan AK, Deb S, Ray DK, Mandal SN, Mukhopadhaya S, Mandal S. Diffuse neurofibroma of scalp. *Neurol India* 2002;50:516-7.
- Chowdary RP, Little BW. Large vascular plexiform neurofibroma of scalp: Excision and coverage with free tissue transfer. *Ann Plast Surg* 1990;24:75-9.
- Ergun SS, Emel E, Karabekir S, Buyukbabani N. Extracranial diffuse neurofibroma with intracranial extension. *Plast Reconstr Surg* 2000;105:801-3.
- Lin YC, Chen HC. Rare complication of massive hemorrhage in neurofibromatosis with arteriovenous malformation. *Ann Plast Surg* 2000;44:221-4.
- Kwak SW, Han YM, Park YS. Diffuse neurofibroma presenting

- with spontaneous intracranial hemorrhage. J Korean Neurosurg Soc 2006;39:459-63.
9. Tung TC, Chen YR, Chen KT, Chen CT, Bendor-Samuel R. Massive intratumor hemorrhage in facial plexiform neurofibroma. Head Neck 1997;19:158-62.
 10. Park JH, Kim JR, Shin SJ, Lee NH, Lee HS, Lim YJ. Use of tissue expansion to allow reconstruction of the back after wide resection of a diffuse neurofibroma. J Plast Surg Hand Surg 2011;45:244-7.
 11. de Varebeke SJ, De Schepper A, Hauben E, Declau F, Van Marck E, Van de Heyning PH. Subcutaneous diffuse neurofibroma of the neck: A case report. J Laryngol Otol 1996;110:182-4.

How to cite this article: Kumar S, Bhaskar S, Handa A, Jindal B. Diffuse neurofibroma of scalp. Asian J Neurosurg 2014;9:237.

Source of Support: Nil, **Conflict of Interest:** None declared.

