

CASE REPORT

Choroid plexus papilloma of posterior third ventricle: A case report and review of literature

Mishra Arvind, B. K. Ojha, Chandra Anil, S. K. Singh, Chandra Nagesh, Srivastava Chhitij

Department of Neurosurgery, Chhatrapati Sahuji Maharaj Medical University, Lucknow, India

ABSTRACT

Choroid plexus papillomas (CPPs) are rare intracranial neoplasms, especially in the third ventricle. The most common site of presentation of these lesions is in the fourth ventricle in adults and lateral ventricles in children. We report a male child with a posterior third ventricular CPP who presented with the symptoms of increased intracranial pressure. Magnetic resonance imaging revealed hydrocephalus related to a mass in the posterior third ventricle, occluding the aqueduct of Sylvius. After endoscopic third ventriculostomy, tumor was approached through the infratentorial-supracerebellar approach and completely excised. Pathological examination revealed a typical CPP. This entity should be considered an extremely rare cause of a lesion in the posterior third ventricle.

Key words: Choroid plexus papilloma, hydrocephalus, third ventricle

Introduction

Choroid plexus tumors are rare intraventricular tumors, accounting for less than 1% of all intracranial tumors and 2-4% of brain tumors in children.^[1,2] The frequent locations are the lateral ventricle in infants and children and the fourth ventricle in adults.^[2,3] The third ventricle is a rare site for a CPP; only a limited number of choroid plexus papillomas (CPPs) have been reported at this location.^[4-6] They present challenges to operative management in terms of the young age at typical presentation, propensity for CSF overproduction, and extreme vascularity which can lead to significant blood loss during surgery and incomplete resection of these tumors.^[7-9] We present a case of posterior third ventricular choroid plexus papilloma which was completely excised by the Krause approach.

Case Report

We admitted a 6-year-old male child who presented with moderate to severe holocranial headache associated with vomiting for 15 days. On physical examination, child was

conscious, oriented and without any neurological deficit. Bilateral papilledema was present. Contrast computed tomography (CT) scan [Figure 1] and magnetic resonance imaging [Figure 2] demonstrated gross ventriculomegaly and a homogeneously enhancing mass lesion in posterior third ventricle. Based on the radiographic appearance of this lesion, a presumptive diagnosis of choroid plexus papilloma was made. Endoscopic third ventriculostomy (ETV) was done to relieve hydrocephalus and child was prepared for surgical excision of tumor. At surgery, a midline sub occipital craniotomy was performed and the tumor was approached through infratentorial supracerebellar approach. A cauliflower-like mass was observed in the posterior third ventricle with an attachment to the choroid plexus of the third ventricle. The tumor was moderately vascular, non-suckable. Gross total removal of tumor was achieved. An external ventricular drain was placed. The patient tolerated the procedure well. Postoperatively, the patient did not develop any neurological deficits. The postoperative contrast-enhanced CT scan showed intraventricular air in bilateral frontal horns and no residual tumor within the third ventricle [Figure 3]. Histopathology was consistent with the diagnosis of choroid plexus papilloma [Figure 4].

Discussion

Choroid plexus papilloma is one of the neoplasms frequently observed to occur primarily within the ventricular system, but it rarely involves the third ventricle. In childhood, 80% of CPP arise in the lateral ventricle, 16% in the fourth ventricle, and 4% in the third ventricle. The incidence of third-ventricular choroid plexus papillomas is higher in the first decade (29.5%) of life, with a female predominance, although overall these tumors are more common in male subjects.^[3,10,11]

Access this article online

Quick Response Code:



Website:

www.asianjns.org

DOI:

10.4103/1793-5482.146637

Address for correspondence:

Dr. Arvind Mishra, Department of Neurosurgery, C.S.M. Medical University, Lucknow, India. E-mail: arvindmishrams@yahoo.co.in

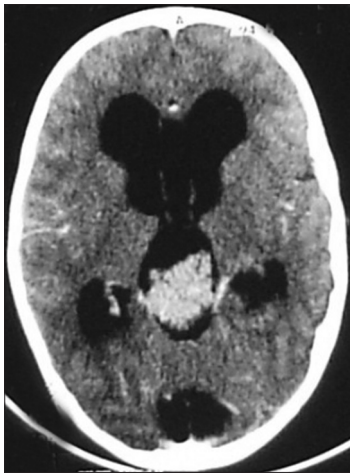

Figure 1: Preoperative contrast CT scan showing homogeneously enhancing mass in posterior third ventricle with hydrocephalus

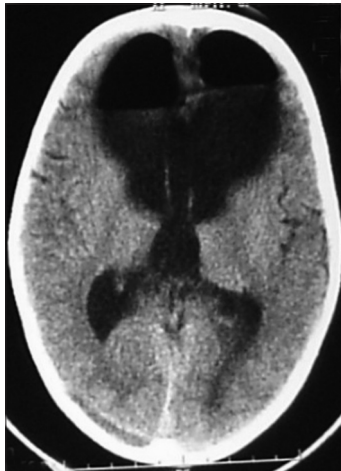


Figure 3: Postoperative contrast CT scan showing no residual tumor in posterior third ventricle with persistent hydrocephalus and pneumocephalus

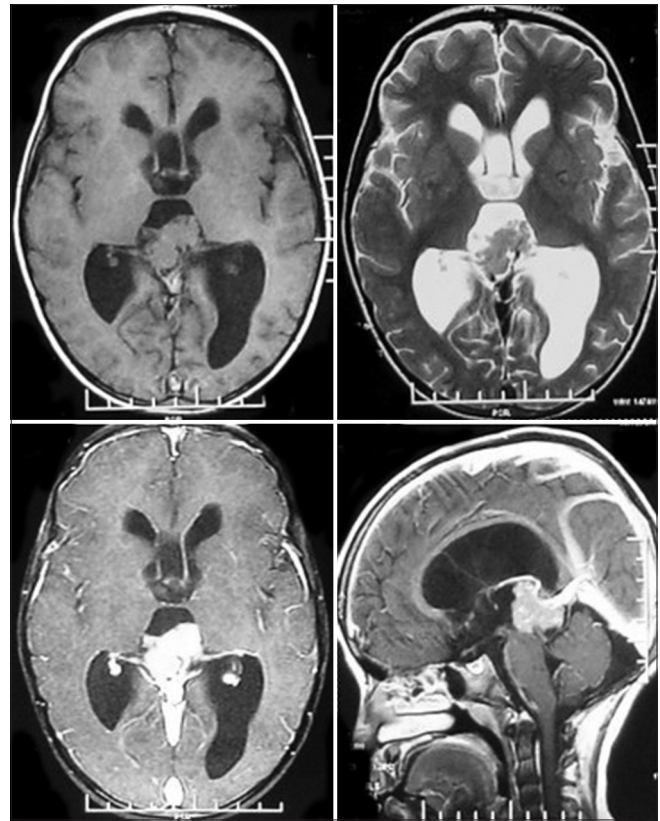


Figure 2: Preoperative T1, T2, and gad MRI showing intraventricular tumor with homogeneous enhancement in posterior third ventricle with obstructive hydrocephalus

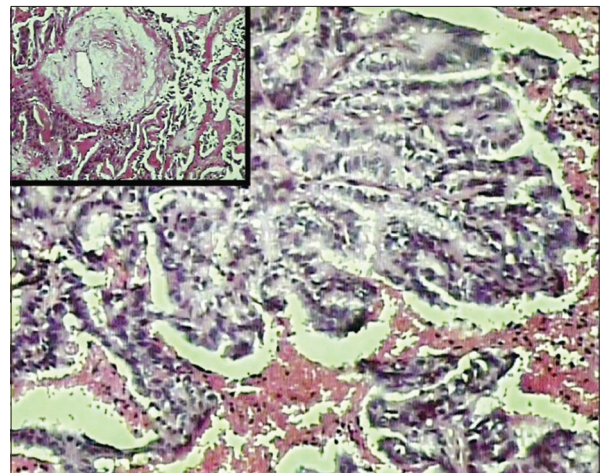


Figure 4: Choroid plexus papilloma showing a single layer of orderly cuboidal to columnar epithelial cells resting on distinct fibrovascular cores (H&E, 40x). Inset shows hyalinized blood vessel (H&E, 40x)

Choroid plexus papillomas are histologically benign neoplasms derived from neuroectoderm, assigned a WHO Grade I; Grade II designation is reserved for atypical CPPs. Resection of these tumors is often curative, with little chance of recurrence following gross-total resection. These tumors present special management challenges due to several unique characteristics, including the young age at presentation, potential for CSF overproduction and the inherent vascularity of these lesions.^[2,7,12] The vascularity of these lesions is often quite robust and varies somewhat with the intraventricular location of the tumor; they can often be supplied by a rich anastomotic bed of choroidal blood vessels. Due to the rich vascular supply of these tumors, endovascular embolization as a preoperative adjunct has been used in an attempt to reduce blood loss intraoperatively.^[9]

The treatment of choice of CPP is surgical excision of the tumor. Total excision should be the aim and is usually achievable as many as 96% of cases. Accomplishing a complete resection is hampered by the typically large size and vascularity of

these tumors in young children, who have a proportionally small circulating blood volume. Overall mortality rates from complications related to surgery have ranged from 0% to 25% and mortality rates attributed to blood loss have been reported to be as high as 12%.^[2,7,12,13]

Various surgical approaches have been described for posterior third ventricular tumors. We usually prefer infratentorial

supracerebellar approach for posterior third ventricle tumor as it offers the advantage of a direct midline approach to a midline tumor, advantage of the effect of gravity in sitting position and deep venous structures lie dorsal to tumor while using this approach. But the disadvantage of this approach is a narrow operative corridor which can cause problems in resecting large vascular tumors. As the prevention of bleeding is a major consideration during surgical excision of these lesions in pediatric patients, a technique of gentle, repetitive bipolar coagulation of the tumor surface under constant irrigation (to shrink the tumor and remove it in totality) is preferred to its piecemeal excision.

CPPs have an excellent long-term survival after only gross total resection, ranging from 90% to 100%. Adjuvant therapy is used for malignant tumors and those that have shown leptomeningeal spread.^[7,12]

References

1. Buckle C, Smith JK. Choroid plexus papilloma of the third ventricle. *Pediatr Radiol* 2007;37:725.
2. Ogiwara H, Dipatri AJ Jr, Alden TD, Bowman RM, Tomita T. Choroid plexus tumors in pediatric patients. *Br J Neurosurg* 2012;26:32-7.
3. Kroppenstedt SN, Golfinos J, Sonntag VK, Spetzler RF. Pineal region lesion masquerading choroid plexus papilloma: Case report. *Surg Neurol* 2003;59:124-7; discussion 127.
4. Nakano I, Kondo A, Iwasaki K. Choroid plexus papilloma in the posterior third ventricle: Case report. *Neurosurgery* 1997;40:1279-82.
5. Pawar SJ, Sharma RR, Mahapatra AK, Lad SD, Musa MM. Choroid plexus papilloma of the posterior third ventricle during infancy and childhood: Report of two cases with management morbidities. *Neurol India* 2003;51:379-82.
6. Razzaq AA, Chishti KN. Giant choroid plexus papilloma of the third ventricle. *J Pak Med Assoc* 2003;53:573-5.
7. Krishnan S, Brown PD, Scheithauer BW, Ebersold MJ, Hammack JE, Buckner JC. Choroid plexus papillomas: A single institutional experience. *J Neurooncol* 2004;68:49-55.
8. Tsumoto T, Nakai E, Uematsu Y, Nakai K, Itakura T. Choroid plexus papilloma in the posterior third ventricle in infancy: A case report. *No Shinkei Geka* 1999;27:673-8.
9. Wind JJ, Bell RS, Bank WO, Myseros JS. Treatment of third ventricular choroid plexus papilloma in an infant with embolization alone. *J Neurosurg Pediatr* 2010;6:579-82.
10. Carson BS, Weingart JD, Guarnieri M, Fisher PG. Third ventricular choroid plexus papilloma with psychosis. Case report. *J Neurosurg* 1997;87:103-5.
11. Karim A, Fowler M, McLaren B, Cardenas R, Patwardhan R, Nanda A. Concomitant choroid plexus papillomas involving the third and fourth ventricles: A case report and review of the literature. *Clin Neurol Neurosurg* 2006;108:586-9.
12. Menon G, Nair SN, Baldawa SS, Rao RB, Krishnakumar KP, Gopalakrishnan CV. Choroid plexus tumors: An institutional series of 25 patients. *Neurol India* 2010;58:429-35.
13. Sarkar C, Sharma MC, Gaikwad S, Sharma C, Singh VP. Choroid plexus papilloma: A clinicopathological study of 23 cases. *Surg Neurol* 1999;52:37-9.

How to cite this article: Arvind M, Ojha BK, Anil C, Singh SK, Nagesh C, Chhitij S. Choroid plexus papilloma of posterior third ventricle: A case report and review of literature. *Asian J Neurosurg* 2014;9:238-9.

Source of Support: Nil, **Conflict of Interest:** None declared.

