

CASE REPORT

Recurrent primary retro-bulbar hydatid cysts

Jayendra Kumar, C. B. Sahay, Anil Kumar

Department of Neurosurgery, Rajendra Institute of Medical Sciences, Ranchi, Jharkhand, India

ABSTRACT

Retro-bulbar hydatid cysts are extremely uncommon, while nonorbital forms are frequently encountered disease in underdeveloped countries. Most of these are situated in the superolateral and superomedial angle of the orbit. We report a case of recurrent primary hydatid cysts of the orbit, situated in different locations in the orbit. A 35-year-old female patient was admitted to Department of Neurosurgery with proptosis, ptosis and watering from left eye. She also complained for headache with excruciating pain in left eye and loss of vision in left eye. Neurological examination revealed limited ocular mobility in all directions. Visual acuity was reduced to finger counting at 2-feet distance. Papilledema was found in ophthalmic examination. This case was considered as recurrence of primary infection because there was no previous history of hydatid disease and no finding of liver and lung cysts on radiological examinations. Treatment of orbital hydatid cyst, early diagnosis, surgical excision and systemic use of albendazole are suggested.

Key words: Ocular mobility, papilledema, proptosis, ptosis, retro-bulbar hydatid cyst, visual acuity

Introduction

Hydatid disease is a parasitic infestation by a tapeworm, *Echinococcus granulosus*. The incidence of hydatid disease greatly varies in different geographical areas. It is endemic in the middle-East as well as the other part of the world including India, Africa, Australia, Turkey, and Southern part of Europe. Its incidence is also common in the part of the world where sheep are raised.^[1] Hydatidosis can involve almost every organ or tissue, especially liver and lung via portal circulation. Primary host of *E. granulosus* is dogs and sheep or cattle are an intermediate host. Humans are the accidental host and affected either by direct contact with these animals or by contamination from plants or water. The most common symptoms in orbital hydatid cyst are slowly progressive unilateral proptosis, with or without pain, visual deterioration, periorbital pain, headache and disturbance in ocular mobility. Ultrasonography (USG), computed tomography (CT)-scan and magnetic resonance imaging (MRI) are imaging technique for hydatid cyst disease.

At present, MRI is preferred diagnostic tool to rule out the other cystic lesion.

We present an extremely rare case of multiple recurrent primary hydatid cyst of orbit located in a different location that removed via simple orbitotomy with Dowling technique.^[2]

Case Report

A 35-year-old female patient was admitted in Department of Neurosurgery with complain of headache, excruciating pain in left eye and visual deterioration. There was proptosis and ptosis [Figure 1] of left eye, which was not responded to any systemic antibiotic. There was no history of trauma and systemic illness. There was a history of operation in left eye for hydatid cyst 9-year ago. On examination, there was proptosis of left eye, which was nontender, irreducible, nonpulsatile and no bruit was audible. The globe was displaced medially and inferiorly. Neurological examination revealed the restriction of ocular movement in all direction. In ophthalmic examination, visual acuity reduced to finger counting at distance of 2-feet and papilledema present in funduscopy. Examination of right eye was within normal limit. Routine blood investigations were normal except eosinophilia. CT-scan of head including orbit revealed multiple hypodense, nonenhancing cystic lesion in the left orbit [Figure 2]. X-ray chest, USG abdomen, electrocardiography, CT-cranium and thorax were normal. Patient underwent surgery via a left simple orbitotomy approach. Layers were separated using hypertonic saline-soaked cotton swab. After reaching in cavity, it was rinsed with hypertonic saline. Multiple hydatid cysts were visible. Visible cysts were removed by hydro dissection (Dowling' technique). Approximately, 15-cysts were removed,

Access this article online

Quick Response Code:



Website:

www.asianjns.org

DOI:

10.4103/1793-5482.146647

Address for correspondence:

Dr. Jayendra Kumar, Department of Neurosurgery, Rajendra Institute of Medical Sciences, Ranchi - 834 009, Jharkhand, India.
E-mail: drjayendra00@gmail.com

and cavity was washed with normal saline and wound closed in layers. Postoperative period was uneventful. Patient was discharged on 10th postoperative day with advice of albendazole (400 mg) BD for 2 months and monthly follow-up. Two month of follow-up, patient doing well and her ocular mobility and vision improved. On physical examination, no proptosis was detected. Follow-up CT-scan of the head including orbit revealed no cystic lesion except granulation tissue [Figure 3].

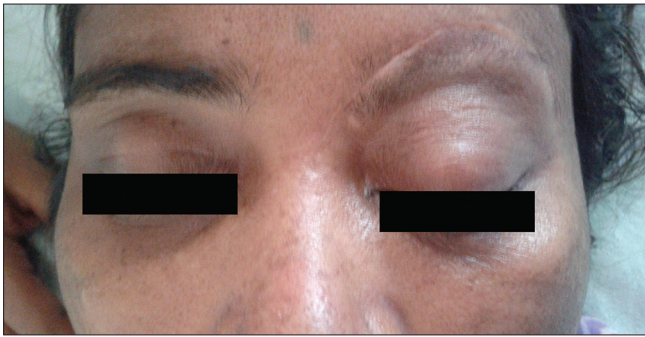

Figure 1: Ptosis and proptosis as well as scar mark of previous incision

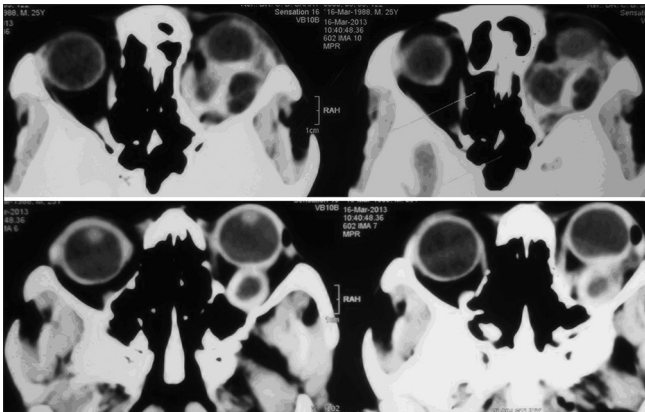


Figure 2a and b: Multiple retro-orbital hydatid cyst displacing the eyeball downwards

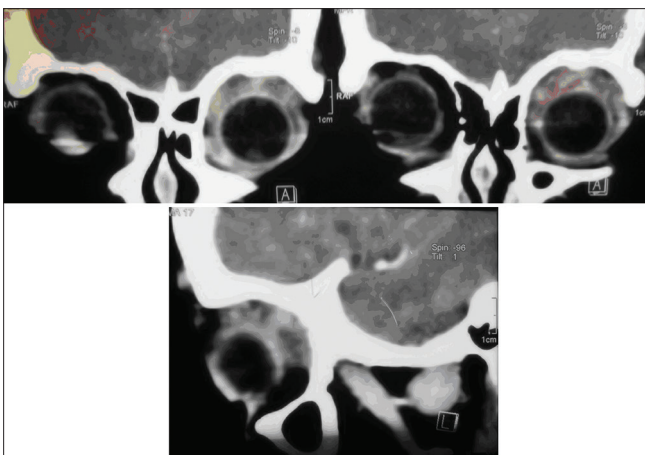


Figure 3a and b: Postoperative picture showing granulation tissue and no hydatid cyst

Discussion

In the human, the liver and lungs are the most common site of hydatid cyst development but may involve almost every organ or tissue via portal and systemic circulation.^[3] In 2-3% of cases, central nervous system involvement occur,^[1] but hydatid manifestation of the orbit comprises <1%.^[4] Orbital hydatid cysts are solitary lesion in majority of cases, but there are reports in the literature of multiple intraorbital cysts occurring in <5% of the patients with orbital hydatid cysts.^[5] From the literature, orbital hydatids are situated in the superolateral and superomedial angle of the orbit, lying in or close to the muscle cone.^[6-8] Inferiorly located cysts are very rare finding. The most common symptoms in orbital hydatid cysts are slowly progressive unilateral proptosis with or without pain, diplopia, headache, visual deterioration, periorbital pain.^[9] USG, CT-scan and MRI are diagnostic imaging technique. Orbital MRI has proved to be preferred diagnostic tool to rule out other lesion. In spite of that, its use is limited because of the high cost in an endemic area. Various surgical approaches have been used to expose the orbital mass. An understanding of microanatomy of the orbit and proper surgical approaches are very important in preventing surgical complication during intraorbital hydatid cysts excision. We used Dowling technique^[2] of hydro dissection in which normal saline irrigation is used with mild force between cyst wall and orbital interface in order to deliver cyst intact. This is often possible because the adhesion around the cyst wall is minimal. Cyst rupture is rather common and may result into severe anaphylactic reaction, incomplete removal or secondary implantation.^[10] Albendazole treatment is useful, especially if it begins 14-18 days before surgery, and it used as an adjunctive therapy to surgery.^[1,2] We use albendazole to decrease the risk of relapse.

Conclusion

1. Early diagnosis, surgical excision, and systemic use of albendazole promptly improved the ocular symptoms, and permanent visual deterioration was prevented
2. The clinicians should always include the diagnosis of hydatid cyst in the differential diagnosis of orbital mass and proptosis.

References

1. Altinörs N, Bavbek M, Caner HH, Erdogan B. Central nervous system hydatidosis in Turkey: A cooperative study and literature survey analysis of 458 cases. *J Neurosurg* 2000;93:1-8.
2. Carrea R, Dowling E Jr, Guevara JA. Surgical treatment of hydatid cysts of the central nervous system in the pediatric age (Dowling's technique). *Childs Brain* 1975;1:4-21.
3. Braunwald E, Fauci AS, Kasper DL, Hauser SL, Longo DL, Jameson JL. Cestodes. In: *Harrison's Principles of Internal Medicine*. 15th ed. New York: McGraw-Hill Medical Publishing Div. 2001. p. 1248-51.
4. Turgut AT, Turgut M, Kosar U. Hydatidosis of the orbit in Turkey: Results from review of the literature 1963-2001. *Int Ophthalmol* 2004;25:193-200.

5. Jimenénez-Mejías ME, Alarcón-Cruz JC, Márquez-Rivas FJ, Palomino-Nicás J, Montero JM, Pachón J. Orbital hydatid cyst: Treatment and prevention of recurrences with albendazole plus praziquantel. *J Infect* 2000;41:105-7.
6. Chana HS, Klauss V, Shah A. Orbital hydatid disease in Kenya. *Am J Trop Med Hyg* 1986;35:991-4.
7. Lerner SF, Gomez Morales A, Croxatto JO. Hydatid cyst of the orbit. *Arch Ophthalmol* 1991;109:285.
8. Talib H. Orbital tumours in Iraq. *Ann R Coll Surg Engl* 1972;51:31-40.
9. Sami A, Achouri M, Harouch M, Choukry M, Ouboukhlik A, Elkamar A, *et al.* Intra-orbital hydatid cysts 10 cases. *Neurochirurgie* 1995;41:398-402.
10. Nahri GE. A simplified technique for removal of orbital hydatid cysts. *Br J Ophthalmol* 1991;75:743-5.

How to cite this article: Kumar J, Sahay CB, Kumar A. Recurrent primary retro-bulbar hydatid cysts. *Asian J Neurosurg* 2014;9:242.

Source of Support: Nil, **Conflict of Interest:** None declared.

