

## CASE REPORT

# Anterior petrosal approach for brainstem cavernoma

B. Mare Pandurang, N. Churi Omkar, K. Misra Basant

Department of Neurosurgery and Gamma Knife Radiosurgery, P D Hinduja National Hospital and Medical Research Centre, V S Marg, Mahim, Mumbai, India

## ABSTRACT

Brainstem cavernomas (BC) comprise about 5-18% of intracranial vascular malformations. The annual hemorrhage rate varies depending on the study design ranging from as low as 0.25% per patient-year in a retrospective study<sup>[2]</sup> to 1.6-3.1% per patient-year in prospective studies.<sup>[4,5]</sup> The annual event rate is significantly higher in deep (brainstem, diencephalon) and infratentorial cavernomas when compared to their counterparts in other locations.<sup>[5]</sup> The management of BC can be conservative or surgical depending upon the mode of clinical presentation. Surgical excision of a BC is a challenge because of critical anatomy. We present a case of BC, which was totally excised with anterior petrosal approach. Anterior petrosal approach has been used for excision of BC in only 17 cases until now.<sup>[6]</sup> The use of preoperative diffusion tensor imaging, tractography, intra-operative navigation, and cranial nerve monitoring will help in reducing the morbidity.

**Key words:** Brainstem cavernoma, neuro navigation, petrosal approach, surgery, tractography

## Introduction

Brainstem cavernomas (BC) are benign vascular malformations comprising about 5-18% of intracranial vascular malformations and generally present with focal neurological deficit. Female gender, hemorrhagic presentation and deep location increase the risk of hemorrhage.<sup>[1-6]</sup> The annual hemorrhage rate varies depending on the study design ranging from as low as 0.25% per patient-year in a retrospective study<sup>[2]</sup> to 1.6-3.1% per patient-year in prospective studies.<sup>[4,5]</sup> Owing to their eloquent location, the incidence of postoperative morbidity is significant. Anterior petrosal approach has been used for excision of BC in only 17 cases until now.<sup>[6]</sup> Use of diffusion tensor imaging (DTI), tractography, intraoperative navigation, and cranial nerve monitoring along with precise anatomical knowledge will help in selecting the approach and reducing the morbidity.

## Case Report

A 22-year-old male presented with a history of sudden onset right-sided weakness and diplopia associated with headache and vomiting 2 months prior to admission. Clinical examination revealed Medical Research Council grade IV/V power on right side and left abducens palsy. Plain computed tomographic (CT) scan of brain showed a hyperdense well-defined lesion in left half of pons. MRI Brain revealed a hyperintense lesion in T1-weighted and T2-weighted sequences with a well-defined hypointense rim [Figure 1]. Preoperative tractography was done to track the corticospinal tracts in relation to the lesion and were found to be displaced posteromedially in left half of pons [Figure 2]. Based on the tractography and more ventral location of cavernoma, anterior petrosal approach was planned.

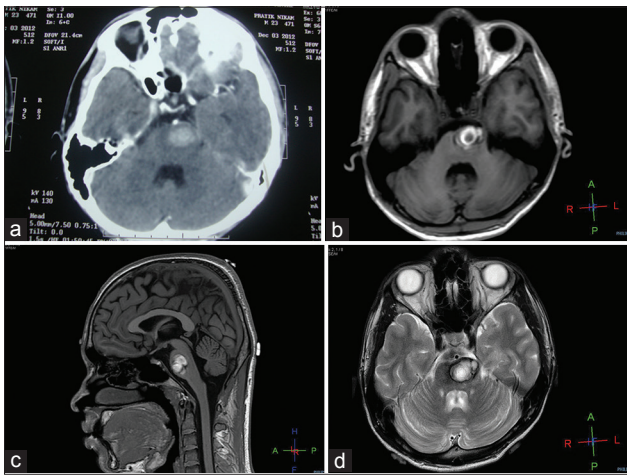
Patient was placed supine with head turned to right side. Lumbar drain was placed to drain cerebrospinal fluid. Left temporozygomatic craniotomy was performed. Extradural anterior petrosectomy was carried out before dural incision. Tentorium was cut posterior to trochlear nerve. After incising the tentorium, anterolateral surface of brainstem was seen but without any xanthochromia. Hence, cavernoma was localized with navigation. Small horizontal incision was taken in anterolateral portion of pons and complete excision of cavernoma was done. Intraoperative brainstem auditory evoked response (BAER) and facial nerve monitoring did not show any disturbance.

Postoperative imaging showed complete excision of the lesion with preservation of the corticospinal tracts [Figure 3].

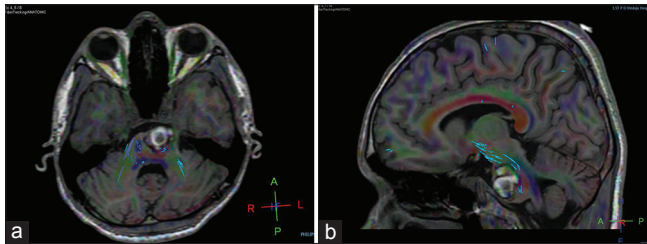
Access this article online	
Quick Response Code:	Website: www.asianjns.org
	DOI: 10.4103/1793-5482.146649

### Address for correspondence:

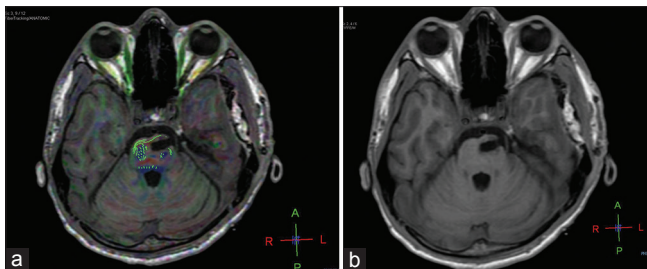
Dr. Basant K Misra, Department of Neurosurgery and Gamma Knife Radiosurgery, P D Hinduja National Hospital and Medical Research Centre, V S Marg, Mahim, Mumbai - 400 016, India.  
E-mail: basantkmisra@gmail.com



**Figure 1:** (a) Plain computed tomographic scan showing hyperdense lesion in left half of pons. (b) Magnetic resonance imaging (MRI) T1-weighted axial image showing hyperintense lesion. (c) MRI T1-weighted sagittal images showing hyperintense lesion. (d) MRI T2-weighted image showing hyperintense lesion with hemosiderin ring



**Figure 2:** (a and b) Preoperative diffusion tensor imaging images showing posteromedial displacement of corticospinal tracts (red) in the left half of pons



**Figure 3:** Postoperative tractography (a) and magnetic resonance imaging T1-weighted images (b) Complete excision of cavernoma and preservation of corticospinal tracts

Postoperative hearing and face was normal. The patient improved symptomatically with complete resolution of diplopia and weakness over 2 months.

## Discussion

Brainstem cavernoma follows a more aggressive clinical course due to its eloquent location. Symptomatic lesions reaching up to the pial or ependymal surface are treated surgically. While Tarnaris *et al.* proposed that conservative management for BC have a better long-term outcome,<sup>[8]</sup> majority of the authors

believe that surgical excision of accessible symptomatic BC will have a better long-term outcome.<sup>[6,9-12]</sup> Multiple approaches have been proposed and utilized for BC – the most common being supracerebellar infratentorial, occipital transtentorial and retrosigmoid.

Petrosal approaches have been infrequently used for BC. Spetzler *et al.* popularized the use of petrosal approaches for BC.<sup>[13]</sup> These approaches provide a better ventral exposure than any other approach. Until now, petrosal approach has been reported in 65 cases of BC and anterior petrosal approach was utilized in only 17.<sup>[6]</sup> In these 17 cases fourteen had the standard Kawase<sup>[14]</sup> approach whereas other three were operated through an intradural anterior petrosectomy.<sup>[15]</sup>

In the present case, the anterior petrosal approach was used based on the location of the cavernoma in the anterolateral part of the pons, the relationship of the pyramidal tracts posterior to the cavernoma and our experience with the anteropetrosal approach for other lesions.<sup>[16]</sup>

Modalities like frameless stereotaxy, BAER, SSEP, intra-operative cranial nerve mapping and neuronavigation can be used to localize the lesion as well as critical neurovascular structures and reduce the morbidity. Preoperative relationship and status of corticospinal tracts in relation to brainstem cavernoma helps in predicting postoperative motor outcome.<sup>[17]</sup> In the present, case preoperative DTI was used to localize the corticospinal tracts and helped in planning the surgical approach.

The anterior petrosal approach provides a surgical corridor-superiorly till the oculomotor nerves, inferiorly till the mid-clivus, laterally till the internal acoustic meatus, and medially, till the contralateral abducens nerve. Once pons is reached, the cavernoma is approached via the peritrigeminal area, which lies between the pyramidal tracts and the trigeminal nerve, with the anterolateral surface of pons as the base, and the apex being the mesencephalic and sensory nuclei of trigeminal nerve. The safe entry zones for brainstem are through lateral mesencephalic sulcus, the peritrigeminal area, and the inferior olivary nucleus.<sup>[18]</sup>

The advantages of anterior petrosal approach in the present case are lesser retraction and damage to the cerebellum and temporal lobe, reduced injury to VII-XI nerves and decreased risk to the temporal venous channels. The approach provides a dry surgical field and the reduced risk of cerebrospinal fluid leak owing to the extradural drilling.

In the present case, we did not come across any complications. Various potential complications/disadvantages associated with this approach are– traction injury to temporal lobe, injury to vein of Labbe, traction injury to GSPN (Greater Superficial petrosal nerve), risk of injury to cochlea, semicircular canals and petrous internal carotid artery. However the incidence of these complications is very low.<sup>[19]</sup> A case report of delayed

facial palsy (facial palsy developing more than 72 h after surgery) has been reported after anterior petrosal approach.<sup>[20]</sup>

## References

1. Aiba T, Tanaka R, Koike T, Kameyama S, Takeda N, Komata T. Natural history of intracranial cavernous malformations. *J Neurosurg* 1995;83:56-9.
2. Del Curling O Jr, Kelly DL Jr, Elster AD, Craven TE. An analysis of the natural history of cavernous angiomas. *J Neurosurg* 1991;75:702-8.
3. Gross BA, Lin N, Du R, Day AL. The natural history of intracranial cavernous malformations. *Neurosurg Focus* 2011;30:E24.
4. Kondziolka D, Lunsford LD, Kestle JR. The natural history of cerebral cavernous malformations. *J Neurosurg* 1995;83:820-4.
5. Porter PJ, Willinsky RA, Harper W, Wallace MC. Cerebral cavernous malformations: Natural history and prognosis after clinical deterioration with or without hemorrhage. *J Neurosurg* 1997;87:190-7.
6. Washington CW, McCoy KE, Zipfel GJ. Update on the natural history of cavernous malformations and factors predicting aggressive clinical presentation. *Neurosurg Focus* 2010;29:E7.
7. Gross BA, Dunn IF, Du R, Al-Mefty O. Petrosal approaches to brainstem cavernous malformations. *Neurosurg Focus* 2012;33:E10.
8. Tarnaris A, Fernandes RP, Kitchen ND. Does conservative management for brain stem cavernomas have better long-term outcome? *Br J Neurosurg* 2008;22:748-57.
9. Abla AA, Turner JD, Mitha AP, Lekovic G, Spetzler RF. Surgical approaches to brainstem cavernous malformations. *Neurosurg Focus* 2010;29:E8.
10. Bertalanffy H, Benes L, Miyazawa T, Alberti O, Siegel AM, Sure U. Cerebral cavernomas in the adult. Review of the literature and analysis of 72 surgically treated patients. *Neurosurg Rev* 2002;25:1-53.
11. Samii M, Eghbal R, Carvalho GA, Matthies C. Surgical management of brainstem cavernomas. *J Neurosurg* 2001;95:825-32.
12. Chen L, Zhao Y, Zhou L, Zhu W, Pan Z, Mao Y. Surgical strategies in treating brainstem cavernous malformations. *Neurosurgery* 2011;68:609-20.
13. Spetzler RF, Daspit CP, Pappas CT. The combined supra- and infratentorial approach for lesions of the petrous and clival regions: Experience with 46 cases. *J Neurosurg* 1992;76:588-99.
14. Kawase T, Toya S, Shiobara R, Mine T. Transpetrosal approach for aneurysms of the lower basilar artery. *J Neurosurg* 1985;63:857-61.
15. Steiger HJ, Hänggi D, Stummer W, Winkler PA. Custom-tailored transdural anterior transpetrosal approach to ventral pons and retroclival regions. *J Neurosurg* 2006;104:38-46.
16. Misra BK. Management of central skull base tumors. In: Sindou M, editor. *Practical Handbook of Neurosurgery*. New York: Springer; 2009. p. 115-27.
17. McLaughlin N, Kelly DF. Corticospinal tractography as a prognosticator for motor improvement after brainstem cavernoma resection. *Br J Neurosurg* 2013;27:108-10.
18. Recalde RJ, Figueiredo EG, de Oliveira E. Microsurgical anatomy of the safe entry zones on the anterolateral brainstem related to surgical approaches to cavernous malformations. *Neurosurgery* 2008;62:9-15.
19. Tomio R, Toda M, Yoshida K, Borghei-Razavi H. Anterior petrosal approach. *J Neurosurg* 2014;120:1249-50.
20. Guthikonda B, Pensak ML, Theodosopoulos PV. Delayed facial palsy after the anterior petrosal approach: Case report and review of the literature. *Neurosurgery* 2010;66:E845-6.

**How to cite this article:** Pandurang BM, Omkar NC, Basant KM. Anterior petrosal approach for brainstem cavernoma. *Asian J Neurosurg* 2014;9:243.

**Source of Support:** Nil, **Conflict of Interest:** None declared.