

## CASE REPORT

# Exophytic pontine glioblastoma multiforme presenting as cerebellopontine angle mass

Sukhdeep Singh Jhawar, Garewal Singh Sarvpreet, T. N. Shadangi

Department of Neurosurgery, Christian Medical College and Hospital, Ludhiana, Punjab, India

## ABSTRACT

Exophytic pontine glioblastoma multiforme (GBM) is a highly malignant tumor of posterior fossa, which is quite rare and such tumor presenting as cerebellopontine (CP) angle mass is even rarer. Here, we describe a 12-year-old boy who presented with imbalance on walking and facial nerve paresis. Magnetic resonance imaging of the brain revealed an irregular ring enhancing mass lesion of the CP angle, which was initially thought to be a tuberculoma, but was later confirmed to be a GBM. Clinical and radiological differentiation of uncommon lesions of CP angle in children is discussed with brief review of pertaining literature.

**Key words:** Cerebellopontine angle, exophytic, brainstem, glioblastoma multiforme, tuberculoma

## Introduction

Glioblastoma multiforme (GBM) are highly aggressive malignant tumors of the supratentorial region. Posterior fossa GBMs are quite uncommon. Most commonly they arise from cerebellar hemispheres in posterior fossa.<sup>[1]</sup> Histologically verified brainstem GBMs are rarely reported in literature as the indications for biopsy or surgery remained controversial. Most of the brainstem glioma present as diffuse involvement of pons or midbrain except few, which present as dorsal or ventral exophytic masses. Brainstem GBM presenting as laterally exophytic cerebellopontine (CP) angle mass is very rare.<sup>[2]</sup> Large proportion of CP angle masses is extra-axial mainly comprising of acoustic schwannoma, meningioma and epidermoid.<sup>[3]</sup> Intra axial masses growing into CP angle can be commonly confused with more common extra-axial mass lesions as they have similar clinical presentation. Here we report a rare case of laterally exophytic brainstem GBM presenting as CP angle mass in a 12-year-old boy. The mass was closely mimicking brainstem tuberculoma on neuroimaging. Clinical and radiological differentiation of CP

angle masses in children is discussed with brief review of pertaining literature.

## Case Report

A 12-year-old male child presented with history of imbalance on walking with tendency to sway to right side since 1 month. Since last 7 days, patient started having headache with vomiting. On neurological examination, patient was having right sided lower motor type facial paresis with numbness. There was also hearing loss in right ear with right sided lateral rectus palsy. Cerebellar signs were present bilaterally (right > left). Magnetic resonance (MR) imaging of the brain revealed a heterogeneous irregular mass lesion with few cystic areas involving right side of pons, midbrain and middle cerebellar peduncle [Figure 1]. The lesion was extending into right CP angle laterally and causing mass effect on right cerebellar lobe and fourth ventricle. Right side of pons and midbrain was distorted. Post gadolinium images showed irregular ring like enhancement of the margins with perilesional edema [Figure 1b-d]. A differential diagnosis of brainstem tuberculoma or exophytic ependymoma was considered. In view of exophytic nature, doubtful diagnosis

### Access this article online

#### Quick Response Code:



#### Website:

www.asianjns.org

#### DOI:

10.4103/1793-5482.148801

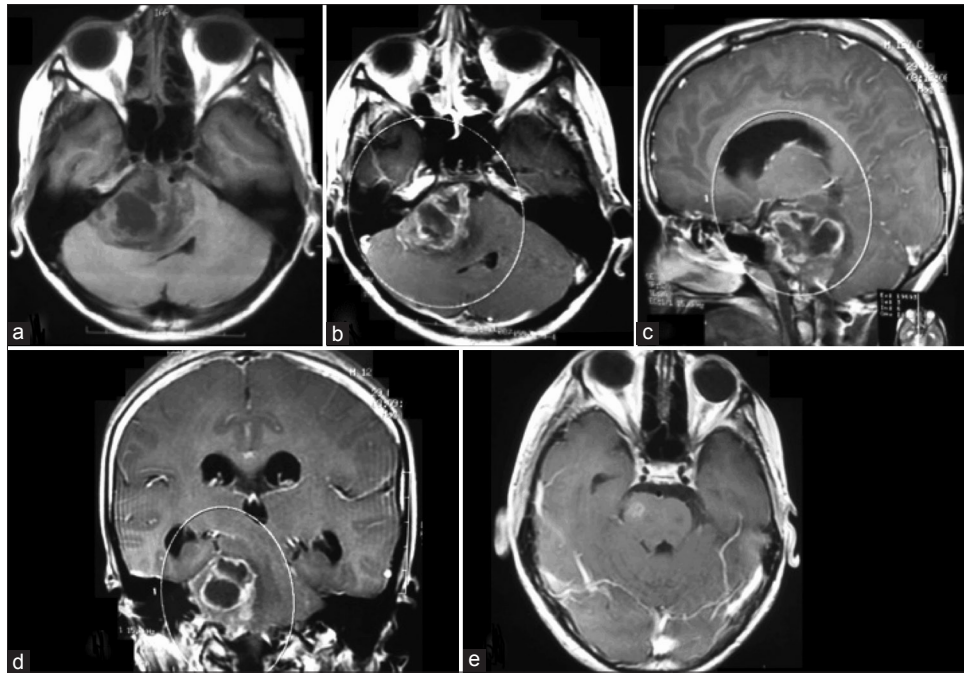
### Address for correspondence:

Dr. Sukhdeep Singh Jhawar, Department of Neurosurgery, Christian Medical College and Hospital, Ludhiana - 141 008, Punjab, India.  
E-mail: drssjhawar@gmail.com

This is an open access article distributed under the terms of the Creative Commons Attribution-NonCommercial-ShareAlike 3.0 License, which allows others to remix, tweak, and build upon the work non-commercially, as long as the author is credited and the new creations are licensed under the identical terms.

**For reprints contact:** reprints@medknow.com

**How to cite this article:** Jhawar SS, Sarvpreet GS, Shadangi TN. Exophytic pontine glioblastoma multiforme presenting as cerebellopontine angle mass. Asian J Neurosurg 2017;12:302-4.



**Figure 1:** (a) T1-weighted axial magnetic resonance (MR) image of brain showing ill-defined hypo to iso intense irregular lesion with cystic areas arising from right side of pons and extending into right cerebellopontine (CP) angle. (b) Post gadolinium axial image showing irregular ring like enhancement of the wall with perilesional edema. (c) Post contrast sagittal image showing irregular enhancing wall. (d) Post contrast coronal image showing the extent of involvement of CP angle. (e) Post contrast axial postoperative image showing small residual tumor in right side of pons

and mass effect on brain stem a decision to operate was taken. Patient underwent right retro sigmoid suboccipital craniectomy with near total excision of the tumor. The tumor was grayish white in color. It was firm to soft in consistency with gelatinous rubbery areas. Few cystic areas with clear fluid were present. Tumor was densely stuck to VII/VIII nerve complex but was separated meticulously. Medially lesion was indistinctly merging into right side of pons where small part of tumor was left behind. Post operatively patient had worsening of facial paresis. Postoperative MR imaging showed small residual tumor involving right side of pons [Figure 1e]. Histopathological examination showed the lesion to be GBM comprising of neoplastic astrocytes with nuclear pleomorphism, hyperchromatism and frequent mitosis. Tumor cells were arranged in sheets with areas of hemorrhages, palisading necrosis, micro vascular proliferation and multinucleated giant cells. Patient received adjuvant radiotherapy. At 1 year follow up, patient was having mild residual paresis of facial nerve. There was no regrowth of small residual tumor on fresh MR scanning.

## Discussion

Cerebellopontine angle mass lesions are more commonly found in adults where they account for 10-15% of all intracranial lesions.<sup>[3]</sup> However in children CP angle is an uncommon location for intracranial lesions.<sup>[4]</sup> Although benign lesions are more frequent but histology varies widely. Intrinsic lesion arising from vicinity and growing mainly into CP

angle are very rare but needs to be differentiated from more common extra axial lesions, especially in children. Laterally exophytic brainstem glioma needs to be differentiated from medulloblastoma and ependymoma.

There can be a substantial overlap in clinical features of intra-axial and extra-axial lesions of CP angle.<sup>[2]</sup> They all cause symptoms by involvement of cranial nerves V to XII. But a rapid progression with early signs of hydrocephalus suggests parenchymal lesion as compared to extra-axial mass. Brainstem signs with long tract involvement also suggest intrinsic lesions but predominantly exophytic lesions may be hard to differentiate clinically. As seen in the present case, a short history is more suggestive of malignant etiology rather than benign lesion.

Magnetic resonance imaging remains the investigation of choice for posterior fossa mass lesions in children. MR findings of posterior fossa GBM are similar to those of supratentorial GBM.<sup>[5]</sup> On precontrast MR, tumor and surrounding edema generally demonstrated prolonged T1 and T2 relaxation times, low signal on T1-weighted, and high signal on T2-weighted images. On contrast enhanced MR studies, solid components usually show marked ring-like enhancement in most cases, usually with irregularly thickened walls and central necrosis.

Other posterior fossa tumors that show similar contrast enhancement include primitive neuroectodermal tumor of the posterior fossa or medulloblastoma, ependymoma,

pilocytic astrocytoma, hemangioblastoma and tuberculoma.<sup>[5]</sup> Primitive neuroectodermal tumor most often occurs in the midline within the posterior fossa and frequently causes marked hydrocephalus and peritumoral edema. They often enhance homogeneously but may also have cystic changes and heterogeneous enhancement. Medulloblastoma can be seen in the cerebellar hemisphere, especially in older patients. Ependymoma is, usually, seen in close relation to the fourth ventricle, but can extend inferiorly and laterally via the foramina of Magendie and Luschka, respectively. Peritumoral edema is minimal. Pilocytic astrocytoma, often seen in children, shows cystic components with mural nodules with little or no surrounding edema. Extensive contrast enhancement is sometimes seen. However, ring enhancement is uncommon. Hemangioblastoma may be sometimes multicentric and may have cystic change with a mural nodule but, usually, also shows vascular flow voids in and around the mass. Tuberculomas of brainstem can rarely have similar ring-like enhancement, and preoperative diagnosis is always not possible. MR spectroscopy can be helpful in such cases.

As glioblastoma is quite rare in this age group and in this location, a diagnosis of tuberculoma was considered as the first diagnosis. An image-guided biopsy was a valid option. However considering exophytic nature and mass effect on surrounding structures a decision of gross total excision was taken, as this will also give him best symptomatic relief and chance for disease-free survival. A biopsy is a better option if lesion is totally intra-axial with no chance of gross total

excision. A CP angle surgery is quite safe and offers a survival advantage as seen in the present case.

## Conclusion

This case demonstrates that exophytic brainstem GBM growing into CP angle although rare, can resemble clinically and radiologically other common lesions like ependymoma and tuberculoma. Hence, a histological confirmation is warranted in such cases as surgical and adjuvant treatment differs widely in all these lesions.

## Financial support and sponsorship

Nil.

## Conflicts of interest

There are no conflicts of interest.

## References

1. Berger MS, Edwards MS, LaMasters D, Davis RL, Wilson CB. Pediatric brain stem tumors: Radiographic, pathological, and clinical correlations. *Neurosurgery* 1983;12:298-302.
2. Ahn MS, Jackler RK. Exophytic brain tumors mimicking primary lesions of the cerebellopontine angle. *Laryngoscope* 1997;107:466-71.
3. Bonneville F, Sarrazin JL, Marsot-Dupuch K, Iffenecker C, Cordoliani YS, Doyon D, *et al.* Unusual lesions of the cerebellopontine angle: A segmental approach. *Radiographics* 2001;21:419-38.
4. Kasliwal MK, Gupta DK, Mahapatra AK, Sharma MC. Multicentric cerebellopontine angle glioblastoma multiforme. *Pediatr Neurosurg* 2008;44:224-8.
5. Kuroiwa T, Numaguchi Y, Rothman MI, Zoarski GH, Morikawa M, Zagardo MT, *et al.* Posterior fossa glioblastoma multiforme: MR findings. *AJNR Am J Neuroradiol* 1995;16:583-9.