

CASE REPORT

Anal extrusion of migrated ventriculo-peritoneal shunt catheter: An unusual complication and review of literature

Avijit Sarkari, Sachin A. Borkar, A. K. Mahapatra

Department of Neurosurgery, All India Institute of Medical Sciences, New Delhi, India

ABSTRACT

Authors present an unusual case of anal extrusion of peritoneal end of ventriculo-peritoneal shunt in a 2-year-old male child. Pertinent literature is reviewed regarding this rare complication of a very commonly performed neurosurgical procedure.

Key words: Abdominal, anal extrusion of peritoneal catheter, complications, ventriculo-peritoneal shunt

Introduction

Ventriculo-peritoneal (VP) shunt is universally accepted; most commonly performed cerebrospinal fluid (CSF) diversion procedure for hydrocephalus. However, the procedure is associated with wide variety of complications, neurological, and non-neurological, which can occur in immediate perioperative period or on follow-up. The reported incidence of abdominal complications is 10-30%.^[1] Various abdominal complications include mechanical blockage of distal shunt catheter, formation of abdominal pseudocyst, inguinal hernia, intestinal obstruction, and spontaneous bowel perforation.^[2-7] Bowel perforation caused by a peritoneal catheter is a rare complication. Perforation has been reported with virtually every possible hollow viscera in the abdomen.^[8-12] The migration of lower end of catheter is a rare problem with a reported incidence of about 10%.^[13,14] Authors report a rare case of anal extrusion of a migrated ventriculo-peritoneal shunt catheter in a 2-year-old male child with myelomeningocele and associated hydrocephalus.

Case Report

The child was a follow-up case of cervical myelomeningocele

with Chiari II malformation and hydrocephalus. Patient was operated in November 2010 at the age of 14 months. Low pressure ventriculoperitoneal shunt (Chhabra shunt) followed by excision and repair of myelomeningocele was carried out at that time. Child was doing well before he was brought with extrusion of shunt catheter through anus [Figure 1]. There was no history of fever or failure to thrive. On examination, there was no evidence of meningitis or peritonitis. Computerized tomography (CT) scan of the head showed ventricular end of catheter in-situ with well decompressed ventricles [Figure 2]. Contrast CT did not show any evidence of intracerebral abscess. Ultrasound abdomen was negative for any intra-abdominal collection. Patient was operated- previous abdominal incision opened, shunt catheter was cut at the abdominal wound level and gently pulled out by the extruded anal portion. Rest of the shunt assembly including the ventricular end was removed by an incision at the head end. CT head was done 24 hours later. It did not show increase in ventricular size and patient was asymptomatic. So, a fresh VP shunt was not put. The CSF examination did not reveal any evidence of meningitis and CSF culture was sterile. Patient was managed with broad spectrum antibiotics for about a week. There was no evidence of peritonitis. Oral feed was gradually introduced which the child tolerated well and was discharged on 7th post-operative day. Child was again brought to casualty after about a month with complaints of vomiting and persistent crying. CT head showed hydrocephalus for which a low-pressure Chhabra ventriculo-peritoneal shunt was done. The patient is currently on regular follow-up, and was well at last follow-up four months after shunt placement.

Access this article online	
Quick Response Code:	Website: www.asianjns.org
	DOI: 10.4103/1793-5482.150002

Address for correspondence:

Dr. Sachin A. Borkar, Department of Neurosurgery, Room No 720, 7th Floor, CN center, All India Institute of Medical Sciences, Ansarinagar, New Delhi - 110 029, India.
E-mail: sachin.aiims@gmail.com

Discussion

Ventriculo-peritoneal shunt is the most commonly performed procedure for the management of hydrocephalus. A wide variety of complications can occur anywhere along its course

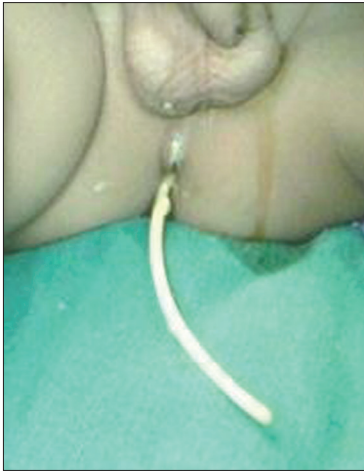


Figure 1: Clinical photograph showing anal extrusion of ventriculoperitoneal shunt

from the ventricle cranially to the peritoneal cavity caudally.^[1] Bowel perforation and anal extrusion of a peritoneal catheter is an unusual complication which was first reported by Wilson and Bertrand in 1966.^[15] Till date, to the best of our knowledge, 56 cases of transanal prolapse of distal ventriculoperitoneal shunt catheter have been reported till date.^[8,15-18] Akyuz *et al.*,^[19] hypothesized that the catheter tip adheres to the wall of viscera and a constant pressure of the abutting tip along with local inflammatory reaction leads to erosion of the visceral wall and entrance of tip in the lumen. The peristaltic activity of gut carries it all the way down to the anus. Since the inflammation is usually a localized phenomenon, rarely there are any obvious signs of peritonitis.^[8,16-18] Various other mechanisms have been suggested, including poor general condition of the patient with weakening of the intestinal wall and the stiff end of the shunt tube causing perforation. Because of weak bowel musculature, children are more susceptible to intestinal perforation. We have used Chhabra shunt, the peritoneal end of which is quite soft. Use of modern soft supple catheters made up of silicone, which may incite a lesser foreign body reaction, has been said to have decreased the incidence of such complications.^[19] Use of trocar for placing the abdominal catheter is a blind procedure and has also been found as a causative factor.^[20]

The diagnosis is obvious if the shunt tube is found extruding through the anus. The presentation can be in the form of meningitis and the presence of gram-negative or anaerobic unusual organisms should raise the suspicion for further investigations like abdominal CT or upper and lower gastrointestinal tract endoscopy.^[21,22] Presence of pneumocephalus on CT head is an indicator of bowel perforation.^[23]

Contrast-enhanced CT scan of the head should always be done to look for cerebral abscess that may develop due to retrograde migration of infection to the cranial cavity. The management includes prompt removal of shunt and institution of broad

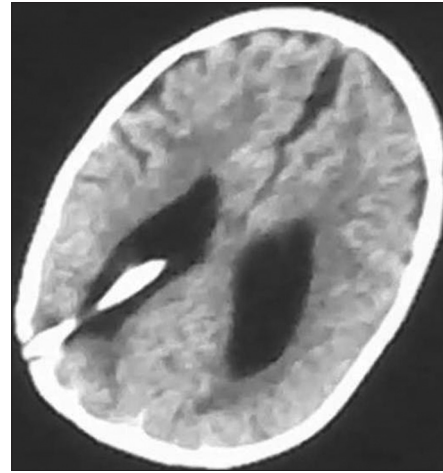


Figure 2: CT head showing shunt tip in situ with well-decompressed ventricles. Note the sulci can be seen well

spectrum antibiotics.^[18] Cerebral decongestants should be started and a further replacement of shunt on opposite side, if indicated, is to be done after two successive cultures of CSF are sterile. Removal of abdominal extruded end may not require a formal laparotomy. Mobilization of shunt catheter from adhesions of abdominal wound with gentle pull out and dedicated observation for any signs of peritonitis may avoid a major abdominal surgery as in our case.^[24] The patient requires a regular follow-up as such patient may develop delayed peritonitis or shunt malfunction at a later date. To avoid contamination of the tract, the distal end should not be pulled back into the abdominal cavity.

Conclusion

Most bowel perforations complicating ventriculo-peritoneal shunting are due to local inflammatory process rather than technical error in catheter placement. Detection is often delayed and abdominal symptoms overlooked until the patient develops shunt malfunction, retrograde cranial infection, or the shunt protrudes through anus. All these conditions should be aggressively managed so as to decrease the morbidity and mortality. Limited initial surgical effort with adequate antibiotic coverage may avoid a major laparotomy for such complication.

References

1. Bryant MS, Bremer AM. Abdominal complications of ventriculo-peritoneal shunts. Case report and review of literature. *Am Surg* 1988;54:50-5.
2. Agha FP, Amendola MA, Shirazi KK, Amendola BE, Chandler WF. Abdominal complications of ventriculoperitoneal shunts with emphasis on the role of imaging methods. *Surg Gynecol Obstet* 1983;156:473-8.
3. Burchianti M, Cantini R. Peritoneal cerebrospinal fluid pseudocysts: A complication of ventriculoperitoneal shunts. *Childs Nervous System* 1988;4:286-90.
4. Celik A, Ergun O, Arda MS, Yurtseven T, Ersahin Y, Balik E. The incidence of inguinal complications after ventriculoperitoneal shunt for hydrocephalus. *Childs Nerv Syst* 2005;21:44-7.

5. Farrel RJ, Krige JE, Beningfield SJ, Terblanche J. Pyogenic liver abscess following infection of a ventriculoperitoneal shunt. *Am J Gastroenterol* 1994;89:140.
6. Hlaviv ML, Mapstone TB, Gauderer MW. Small bowel obstruction secondary to incomplete removal of a ventriculoperitoneal shunt: Case report. *Neurosurgery* 1990;26:526-8.
7. Snow RB, Lavyne MH, Fraser RA. Colonic perforation by ventriculoperitoneal shunts. *SurgNeurol* 1986;25:173-7.
8. Jindal A, Kansal S, Mahapatra AK. Unusual complication--VP shunt coming out per rectum and brain abscess. *Indian J Pediatr* 1999;66:463-5.
9. Oi S, Shose Y, Oshio T, Matsumoto S. Intra gastric migration of a ventriculoperitoneal shunt catheter. *Neurosurgery* 1987;21:255-7.
10. Oshio T, Kirino A, Go M, Bando Y, Manabe Y, Nakagawa Y. Recurrent perforation of viscus due to ventriculoperitoneal shunt in a hydrocephalic child. *J PediatrSurg* 1991;26:1404-5.
11. Patel CD, Maltloub H. Vaginal perforation as a complication of ventriculoperitoneal shunt. A report of seven cases and review of the literature. *Surg Neurol* 1973;3:265-9.
12. Thippavong S, Kellenberger CJ, Rutka JT, Manson DE. Hepatic and colonic perforation by an abandoned ventriculoperitoneal shunt. *Pediatr Radio* 2004;134:750-2.
13. Borkar SA, Satyarthee GD, Khan RN, Sharma BS, Mahapatra AK. Spontaneous extrusion of migrated ventriculoperitoneal shunt catheter through chest wall: a case report. *Turk Neurosurg* 2008;18:95-8.
14. Kast J, Duong D, Nowzari F, Chaddock WM, Schiff SJ. Time related patterns of ventricular shunt failure. *Childs Nerv Syst* 1996;10:524-8.
15. Wilson CB, Bertrand V. Perforation of bowel complicating peritoneal shunt for hydrocephalus. Report of two cases. *Am Surg* 1966;32:601-3.
16. de Aquino HB, Carelli EF, Borges Neto AG, Pereira CU. Nonfunctional abdominal complications of the distal catheter on the treatment of hydrocephalus: An inflammatory hypothesis? Experience with six cases. *Childs Nerv Syst* 2006;22:1225-30.
17. Hai A, Rab AZ, Ghani I, Huda MF, Quadir AQ. Perforation into gut by ventriculoperitoneal shunts: A report of two cases and review of the literature. *J Indian Assoc Pediatr Surg* 2011;16:31-3.
18. Sathyanarayana S, Wylen EL, Baskaya MK, Nanda A. Spontaneous bowel perforation after ventriculoperitoneal shunt surgery: case report and a review of 45 cases. *Surg Neurol* 2000;54:388-96.
19. Akyuz M, Ucar T, Goksu E. A thoracic complication of ventriculoperitoneal shunt: Symptomatic hydrothorax from intrathoracic migration of a ventriculo-peritoneal shunt catheter. *Br J Neurosurg* 2004;18:171-3.
20. Nebi Y, Nejmi K, Cahide Y, Huseyin C, Sevil AY. Anal protrusion of ventriculo-peritoneal shunt catheter: report of two infants. *J Pediatr Neurol* 2004;2:241-4.
21. Abdel WM. E.Coli meningitis as an indicator of intestinal perforation by V-P shunt tubes. *Neurosurg Rev* 1998;21:194-7.
22. Park CK, Wang KC, Seo JK, Cho BK. Transoral protrusion of a peritoneal catheter: a case report and literature review. *Childs Nervous System* 2000;16:184-9.
23. Shetty PG, Fatterpekar GM, Sahani DV, Shroff MM. Pneumocephalus secondary to colonic perforation by VP shunt. *Br J Radiol* 1999;72:704-5.
24. Yousfi MM, Jackson NS, Abbas M, Zimmerman RS, Fleischer DE. Bowel perforation complicating ventriculoperitoneal shunt: creport and review. *Gastrointest Endosc* 2003;58:144-8.

How to cite this article: Sarkari A, Borkar SA, Mahapatra AK. Anal extrusion of migrated ventriculo-peritoneal shunt catheter: An unusual complication and review of literature. *Asian J Neurosurg* 2016;11:459.

Source of Support: Nil, **Conflict of Interest:** None declared.

