

CASE REPORT

Post-burn spontaneous brain fungation caused by infiltrating Marjolin's ulcer of scalp

Vishal Bhasme, Manish Agrawal, N. C. Poonia, H. Bagaria, Pranay Chakotiya¹

Departments of Neurosurgery and ¹Plastic Surgery, SMS Medical College, Jaipur, Rajasthan, India

ABSTRACT

Marjolin's ulcer is a well-recognized, rare, long-term complication of post-burn scar and other chronically irritating local skin conditions. Its infiltration into the skull bones and the underlying dura causing complete destruction is very rare and quiet exceptional. We present an unusual case of spontaneous brain fungation through the scar tissue present over the scalp as a result of flame burn 18 years back. Patient was treated surgically, but expired after 10 days. Though we were not able to save the patient, its presentation was so unique that we want to report this case.

Key words: Brain fungation, Marjolin's ulcer, scalp, squamous cell carcinoma

Introduction

Marjolin's ulcer is a malignant, ulcerating neoplasm occurring in cicatricial tissue.^[1] This malignancy arises in burned, constantly injured, or chronically inflamed skin. Pathologies such as osteomyelitis, decubitus ulcers, chronic fistulas, frost bite, chronic venous failure, vaccination sites, skin graft donor sites, and chronically traumatized skin are numbered among the etiological factors. Despite these numerous risk factors, this oncological syndrome is rarely diagnosed and commonly mistaken, thus it may often be overlooked.^[2] Owing to the behavior of the lesion and late presentation, the treatment results are often disappointing. Though it is known as a plastic surgical problem, when it invades the dura and brain, it becomes of neurosurgical interest.^[3]

Case Report

An 18-year-old male patient presented with a large 10 × 12 × 10 cm fungating mass over scalp in the midline, more toward the left side [Figure 1]. There was past history

of flame burn over face and scalp around 15 years back when he was a kid. He had been treated with dressings at home by his local medical practitioner. The wound had been closed by scarring during a period of months. The area had remained unchanged until last 2 months, had developed an ulceration over the scar tissue, and there was a serosanguinous discharge since then. Due to personal neglect and a low socioeconomic status, no treatment was taken. Since last 15 days, he had developed a purulent discharge; over last 4-5 days, he had developed a very soft swelling over the scalp which was gradually increasing in size. Neurologically, the patient was normal previously but was now bedridden with increased spasticity in both upper and lower limbs with no power in the lower limbs and 2/5 power in both upper limbs.

On examination, the swelling was very soft, which was probably a brain tissue protruding out through the scalp and the bony defect. Computed tomography (CT) scan confirmed that there was a bony defect present of size about 8 × 6 cm and the brain matter was fungating out. There were areas of intra cerebral hematomas inside the fungating brain tissue [Figure 2a-d]. CT angiography was also done to know about the major blood vessels. Superior sagittal sinus going through the defect was already thrombosed [Figure 2c].

This is an open access article distributed under the terms of the Creative Commons Attribution-NonCommercial-ShareAlike 3.0 License, which allows others to remix, tweak, and build upon the work non-commercially, as long as the author is credited and the new creations are licensed under the identical terms.

For reprints contact: reprints@medknow.com

Access this article online	
Quick Response Code:	Website: www.asianjns.org
	DOI: 10.4103/1793-5482.150220

Address for correspondence:

Dr. Manish Agrawal, 9, Vasundara Colony, Lane No. 4, Tonk Road, Jaipur - 302 004, Rajasthan, India.
E-mail: manishagarwal30@gmail.com

How to cite this article: Bhasme V, Agrawal M, Poonia NC, Bagaria H, Chakotiya P. Post-burn spontaneous brain fungation caused by infiltrating Marjolin's ulcer of scalp. Asian J Neurosurg 2017;12:256-8.

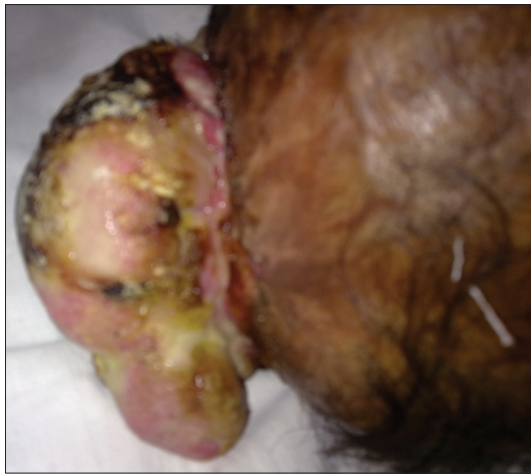

Figure 1: Fungating brain tissue with scarred skin

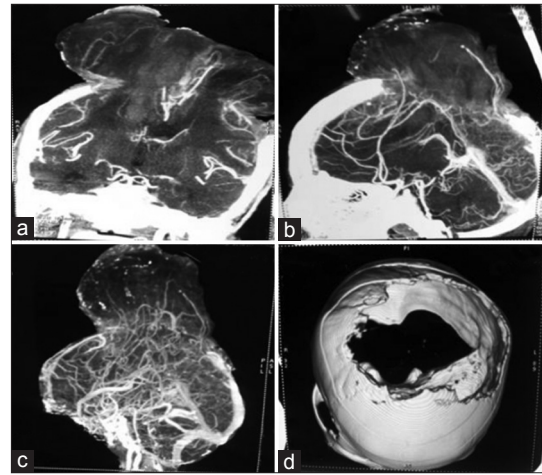


Figure 2: (a and b) Fungating brain through the bony and skin defect along with intra cerebral hematoma and blood vessels seen; (c) thrombosed superior sagittal sinus; (d) the bony defect

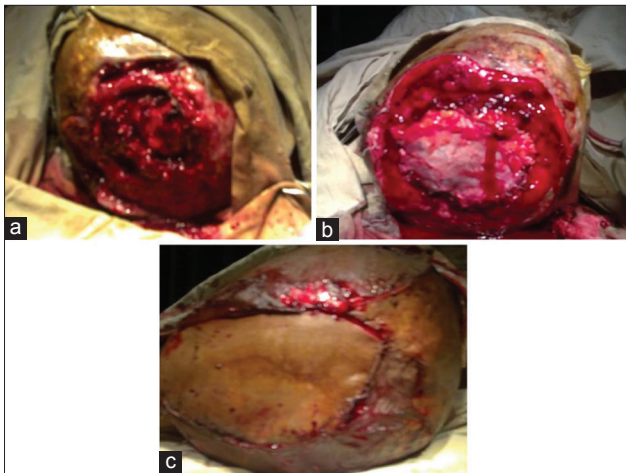


Figure 3: Intraoperative: (a) Excised herniating brain; (b) duraplasty done using fascia lata; (c) skin closure done using forehead transposition flap with split skin grafting

The patient was subjected to surgery for resection of the protruding necrotic brain matter with freshening of the defect with duraplasty using fascia lata of right thigh with forehead transposition flap. The forehead donor site was covered with the split skin graft harvested from the left thigh [Figure 3a-c].

Histopathology of the specimen taken from the margins of the defect revealed well-differentiated squamous cell carcinoma, while that from the excised brain tissue showed marked edema, dense infiltration with acute and chronic inflammatory cells, granulation tissue, and abscess formation. At one focus, there was an area of well-differentiated metastatic squamous cell carcinoma.

Postoperatively [Figure 4], initially the patient recovered well, but later he dramatically deteriorated and expired within 10 days.

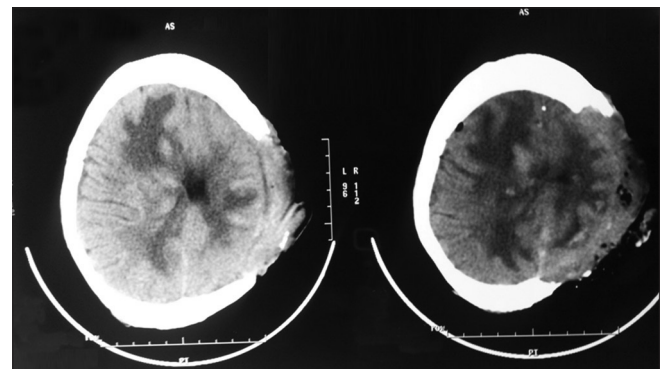


Figure 4: Post-operative non contrast computed tomography head

Discussion

Malignant degeneration of burn scars has been reported as early as in the 1st century by Celsus.^[4] Today, the term “Marjolin’s ulcer” is generally used for squamous cell carcinoma arising in posttraumatic scars. However, squamous cell carcinoma has recently been reported to arise from other skin lesions also such as Fournier’s gangrene.^[5] There have been some case reports of burn scar carcinomas of the scalp,^[6-8] a localization not as common as the lower extremity but still making up approximately 14% of burn scar carcinomas.^[9]

Two variants of Marjolin’s ulcer have been described: An acute form in which the cancer occurs within 1 year of the injury and a chronic form in which malignant changes are more than 1 year from the date of injury.^[10]

Approximately 2% of burn scars undergo malignant transformation. Sites that remain ungrafted or where grafts have failed are more vulnerable for developing malignancy. These grafts often develop chronic and recurrent ulcerations before undergoing malignant transformation.

The tissue progresses through the stages of atrophy, pseudoepitheliomatous hyperplasia, and finally carcinoma.^[1] Surgical excision is the recommended modality of treatment.

In conclusion, appropriate and expeditious initial wound management of scar ulcers will facilitate wound healing and minimize the risks of malignant transformation.

As the scalp is well vascularized, in this location, there is a lower incidence of Marjolin's ulcer when compared to the other sites. Invasion of the skull, dura mater, and the brain is quite exceptional, and has only been reported in a limited number of cases.^[3]

Financial support and sponsorship

Nil.

Conflicts of interest

There are no conflicts of interest.

References

1. Andrew Wong A, Michael M. Johns MM. Marjolin's Ulcer ulcer Arising arising in a Previously previously Grafted grafted Burn burn of the Scalpscalp. *Otolaryngol Head Neck Surg* 2003;128:915-6.
2. Ochenduszkiewicz U, Matkowski R. Marjolin's ulcer: Malignant neoplasm arising in scars. *Rep Pract Oncol Radiother* 2006;11:135-8.
3. Sengul G, Hadi-Kadioglu H. Penetrating Marjolin's ulcer of scalp involving bone, dura mater and brain caused by blunt trauma to the burned area. *Neurocirugia (Astur)* 2009;20:474-7.
4. Marjolin NJ. Ulcère. *Dictionnaire de Medecine* 1828;21:31.
5. Chintamani, Shankar M, Singhal V, Singh JP, Bansal A, Saxena S. Squamous cell carcinoma developing in the scar of Fournier's gangrene—case report. *BMC Cancer* 2004;4:16.
6. Ozek C, Celik N, Bilkay U, Akalin T, Erdem O, Cagdas A. Marjolin's ulcer of the scalp: Report of 5 cases and review of the literature. *J Burn Care Rehabil* 2001;22:65-9.
7. Ozek C, Cankayali R, Bilkay U, Guner U, Gundogan H, Songur E, *et al.* Marjolin's ulcers arising in burn scars. *J Burn Care Rehabil* 2001;22:384-9.
8. Clements B, Lewis H, Lewis H, McKinstrey S, Gray J, Byrnes D. A late, fatal complication of a high energy thermal injury to the scalp. *Ann Plast Surg* 1995;35:650-3.
9. Kowal-Vern A, Criswell BK. Burn scar neoplasms: A literature review and statistical analysis. *Burns* 2005;31:403-13.
10. Gupta SK, Sandhir RK, Jaiswal AK, Kumar S. Marjolin's ulcer of the scalp invading calvarial bone, dura and brain. *J Clin Neurosci* 2005;12:693-6.
11. Horton CE, Crawford HH, Love HG, Loeffler RA. The malignant potential of burn scar.