

CASE REPORT

Conquering the odds: Cirroid aneurysm with holocranial feeders-staged embolization, excision and grafting

Sunil Munakomi, Binod Bhattarai, Iype Cherian

Department of Neurosurgery, College of Medical Sciences, Bharatpur, Nepal

ABSTRACT

Arteriovenous malformation (AVM) of the scalp is an uncommon entity. Its management is difficult because of its high shunt flow, complex vascular anatomy, and possible cosmetic complications. The etiology of scalp AVMs that is, cirroid aneurysm may be spontaneous or traumatic. Clinical symptoms frequently include pulsatile mass, headache, local pain, tinnitus; and less frequently, hemorrhage and necrosis. Selective angiography is the most common diagnosis method. Surgical excision is especially effective in AVMs and the most frequently used treatment method. Here, we present one such case where staged embolization, excision, and subsequent grafting was done.

Key words: Arteriovenous malformation, scalp cirroid aneurysm, treatment

Introduction

An arteriovenous malformation (AVM) of the scalp is an abnormal fistulous connection between the feeding arteries and draining veins, without an intervening capillary bed within the subcutaneous layer.^[1,2] AVM of the scalp is a rare lesion.^[2,3] Its management is difficult because of its high shunt flow, complex vascular anatomy, and possible cosmetic complications.^[3,4] The origin of AVM of the scalp is still uncertain, but trauma is an important factor in most of the patients.^[3,4] Clinical symptoms frequently include pulsatile mass, headache, local pain, tinnitus; and less frequently, hemorrhage and necrosis.^[3,5,6] Surgical treatment is particularly indicated in order to rule out bleeding and for the resolution of cosmetic problems, and in case of tinnitus and headache.^[4,6,7]

Case Report

A 38-year-old female presented with the complaint of slowly progressive swelling over scalp since last 20 years. There

was no history of trauma, loss of consciousness, headache vomiting, altered sensorium or weakness of body parts. Surgical intervention was tried twice but abandoned due to heavy bleeding on both the occasions. On examination, there was a swelling of size $12 \times 4 \text{ cm}^2$ in the forehead and the scalp, which was slightly compressible with audible bruit over the swelling [Figures 1 and 2]. Magnetic resonance imaging (MRI) [Figure 3] and computed tomography (CT) revealed multiple dilated and tortuous vessels over the scalp in frontal and both temporal and parietal region with multiple collaterals. Right transverse, sigmoid and the jugular bulb were asymmetrically prominent. Angiography revealed cirroid aneurysm with feeders from external (superficial temporal, retroauricular and occipital), internal carotid (parasiting vessels from the callosomarginal arteries) and the left P2 VIA left vertebral arteries. Patient had undergone angiographic embolization of the feeders from the external carotid arteries [Figures 4 and 5] as a staged procedure. Care was taken to digitally compress the varix edges to prevent inadvertent embolic particle to enter the intracranial venous system. Ligation of remaining feeders and excision of varix with primary suturing of the scalp defect [Figure 6] was done 10 days later. Patient was started with Low molecular weight heparin and dextran to prevent propagating thrombus in the deep sinuses. Postembolization and excision, CT scan showed no evidence of intracranial propagation of thrombus. Patient was subsequently taken up for skin grafting over the defect in the scalp due to ischemic edges of the defect [Figure 7]. The patient made an uneventful recovery. Postoperative angiography showed only feeders from left occipital branch supplying the scalp.

Access this article online

Quick Response Code:



Website:

www.asianjns.org

DOI:

10.4103/1793-5482.161167

Address for correspondence:

Dr. Sunil Munakomi, Department of Neurosurgery, College of Medical Sciences, Bharatpur, Nepal.

E-mail: sunilmunakomi@gmail.com

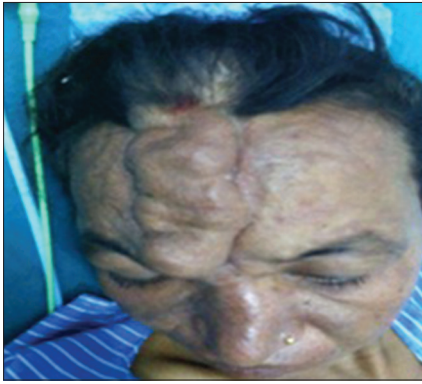

Figure 1: Clinical picture

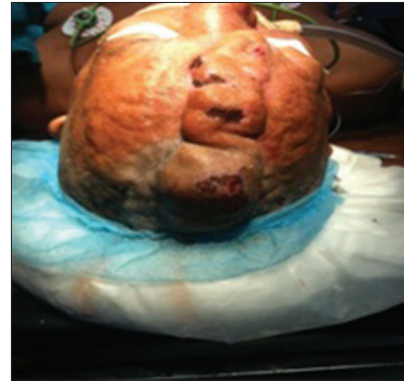

Figure 2: Intraoperative picture

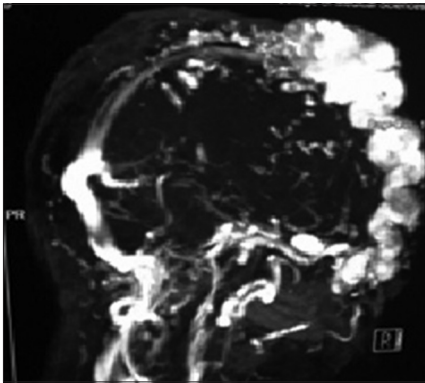


Figure 3: Magnetic resonance angiography

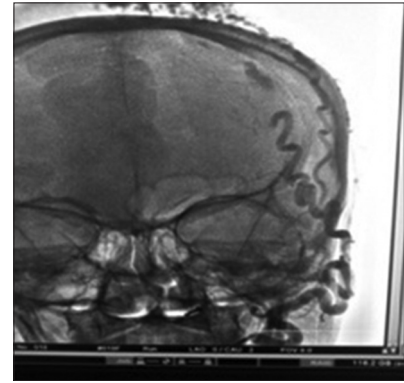


Figure 4: Feeders from external carotid artery

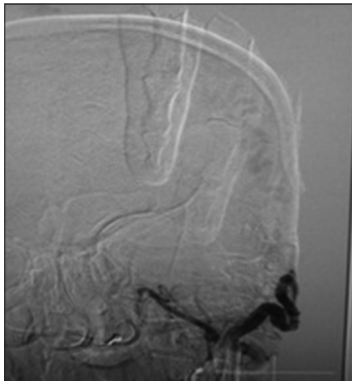


Figure 5: Postembolisation

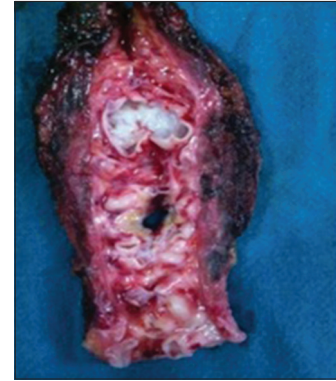

Figure 6: Excised varix

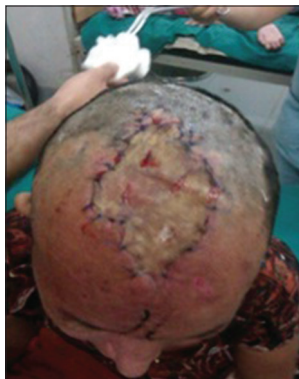

Figure 7: Postskin grafting

Discussion

Arteriovenous malformation of the scalp is an uncommon entity.^[1,2] Various names are used to describe the vascular malformations of the scalp, including aneurysm cirsoides, aneurysma serpentinum, plexiform angioma, arteriovenous fistula, and AVM.^[3-5] The most frequent sites of involvement are frontal, temporal, and parietal regions.^[3,5,6] The origin of the main feeder is in the subcutaneous tissue of the scalp. The origin of these main feeders, most frequently, arises from the external carotid, occipital, and supraorbital arteries. The superficial temporal artery is frequently involved in the traumatic cirsoid aneurysm.^[5-7] The etiology of these lesions

remains controversial. The etiology of scalp AVMs may be spontaneous or traumatic.^[4,8] They generally develop in the trauma background and in patients over 30-year-old. Spontaneous AVM of the scalp may present at birth, but in most patients, it is asymptomatic until adulthood.^[3,8,9] Trauma, pregnancy, or hormonal change causes deterioration of the symptoms. Traumatic AVM of the scalp develops months or years after the scalp trauma. About 10–20% of scalp AVMs develop following penetrating or nonpenetrating trauma to the scalp.^[7,8,10] Their clinical signs are associated with the size of the AVM. The patients may present with headache, numbness, and/or hemorrhage. Others may present with local symptoms such as scalp lesions. Hemorrhage is generally uncommon and may develop in the event of large vascular malformations. Recurrent hemorrhage, which rapidly deteriorates the neurological status, may be seen in some of the patients.^[1,3,8] The quality of the neuro-radiological diagnosis is important for the surgical procedure to be performed, and cranial angiography is of great significance for diagnosis and treatment selection. Selective angiography should be carried out the differential diagnosis of the associated vascular lesions, such as aneurysms, sinus pericranii, venous malformation, and cavernous hemangioma.^[2,8,10] Brain MRA is also of significance for establishing a diagnosis. Scalp AVMs are most frequently confused with hemangioma and cavernomas. No arteriovenous shunt is present in such pathologies, and they are seen as well-demarcated lesions. AVMs show flow void signs on MRI due to the rapid flow in the lesions.^[1,8,10] Surgical excision is especially effective in AVMs, and is the most frequently used treatment method.^[4,7,11] AVM is generally located in the periosteal and temporal fascia or under the galea. Thus, the preoperative radiological evaluation should be used for the assessment of feeding arteries, drainage vessels, numbers of fistulas, connected vascular structures, and shunt flow volume in order to prevent any possible complications.^[3,5,7] One of the substantial complications during the operation is hemorrhage. Hemorrhage may be prevented with preoperative embolization, clamping, and suturing of feeding vessels. Scalp flap is removed with pericranium, which particularly prevents rupture.^[5,7,11] The AVM may not always be related to the cranium. Infection and sepsis as well as hemorrhage and necrosis may be seen as complications.^[1,5,10] Endovascular treatment may be applied in order to decrease the hemorrhage and facilitate the surgical treatment or in the direct treatment of AVMs.^[4,7,11] Embolization of preoperative nidus and feeders especially prevents massive hemorrhage. Embolization and endovascular treatment may not be sufficient in the treatment of large scalp AVMs. Incomplete surgical resection is also insufficient for the treatment. This may cause scalp hemorrhage and necrosis in elderly patients.^[7,8,10] Despite these treatments, recurrence

due to feeding collaterals may develop. The most important step is total surgical excision without causing scalp necrosis and excessive blood loss. Furthermore, a better cosmetic result may be obtained.^[1,3,10] However, when not possible, a feasible option could be achieved by free graft of the scalp defect over healthy granulation tissue.

Conclusion

The objective of scalp AVM treatment is to eliminate the clinical complaints affecting the patient's cosmesis. Treatment options include surgery, endovascular/percutaneous embolization, electrothrombosis, and combined approaches. Definitive treatment may be provided with embolization in those patients with appropriate angiographic characteristics. In the event of scalp necrosis and excessive blood loss, total excision is the fundamental treatment selection. In this case a staged embolization, excision and grafting was thought as the best feasible option.

References

1. Senoglu M, Yasim A, Gokce M, Senoglu N. Nontraumatic scalp arteriovenous fistula in an adult: Technical report on an illustrative case. *Surg Neurol* 2008;70:194-7.
2. Muthukumar N, Rajagopal V, Manoharan AV, Durairaj N. Surgical management of cirroid aneurysms. *Acta Neurochir (Wien)* 2002;144:349-56.
3. Shenoy SN, Raja A. Scalp arteriovenous malformations. *Neurol India* 2004;52:478-81.
4. Massimi L, De Bonis P, Esposito G, Novegno F, Pettorini B, Tamburrini G, *et al.* Vertex scalp mass as presenting sign of a complex intracranial vascular malformation. *J Neurosurg Pediatr* 2009;3:307-10.
5. Heilman CB, Kwan ES, Klucznik RP, Cohen AR. Elimination of a cirroid aneurysm of the scalp by direct percutaneous embolization with thrombogenic coils. Case report. *J Neurosurg* 1990;73:296-300.
6. Burrus TM, Miller GM, Flynn LP, Fulgham JR, Lanzino G. NeuroImages. Symptomatic left temporal arteriovenous traumatic fistula. *Neurology* 2009;73:570.
7. Gupta AK, Purkayastha S, Bodhey NK, Kapilamoorthy TR, Krishnamoorthy T, Kesavadas C, *et al.* Endovascular treatment of scalp cirroid aneurysms. *Neurol India* 2008;56:167-72.
8. Fisher-Jeffes ND, Domingo Z, Madden M, de Villiers JC. Arteriovenous malformations of the scalp. *Neurosurgery* 1995;36:656-60.
9. Li F, Zhu S, Liu Y, Chen Y, Chi L, Chen G, *et al.* Traumatic arteriovenous fistula of the superficial temporal artery. *J Clin Neurosci* 2007;14:595-600.
10. Matsushige T, Kiya K, Satoh H, Mizoue T, Kagawa K, Araki H. Arteriovenous malformation of the scalp: Case report and review of the literature. *Surg Neurol* 2004;62:253-9.
11. Tiwary SK, Khanna R, Khanna AK. Craniofacial cirroid aneurysm: 2-stage treatment. *J Oral Maxillofac Surg* 2007;65:523-5.

How to cite this article: Munakomi S, Bhattarai B, Cherian I. Conquering the odds: Cirroid aneurysm with holocranial feeders-staged embolization, excision and grafting. *Asian J Neurosurg* 2015;10:259-61.

Source of Support: Nil, **Conflict of Interest:** None declared.