

CASE REPORT

Isolated unilateral oculomotor nerve palsy due to head trauma

Ali Kemal Erenler, Anıl Yalçın¹, Ahmet Baydin²

Department of Emergency Medicine, Çorum Education and Research Hospital, Hitit University, Çorum, ¹Department of Emergency Medicine, Samsun Education and Research Hospital, ²Department of Emergency Medicine, Ondokuz Mayıs University, Samsun, Turkey

ABSTRACT

Unilateral oculomotor nerve palsy is a rare and challenging condition for both emergency department (ED) physicians and neurosurgeons. In this report, we present you a case of head trauma with oculomotor nerve palsy whose initial neuroimaging findings were normal. A 50-year-old female presented to our ED due to head trauma secondary to fall from height. On her physical examination, ptosis, minimal lateral deviation, and dilated pupilla unresponsive to the light were determined in the left eye. A computed tomography and magnetic resonance imaging were performed and both were found to be normal. Patient was consulted with an ophthalmologist and any sign of direct trauma to the eye was not determined. Then, the patient was consulted with a neurosurgeon and hospitalized. In some rare instances, minor traumas to the head may result in isolated oculomotor nerve palsy without accompanying findings. Neurosurgeons and ED physicians must be careful about this rare condition.

Key words: Emergency department, oculomotor nerve palsy, trauma

Introduction

Cranial nerve palsies often accompany head trauma. Such a damage requires major trauma and is usually associated with neurological deficits, basilar skull fracture, orbital injury or subarachnoid bleeding.^[1,2] However, isolated cranial nerve palsies may occur due to minor trauma in some instances.^[3] In this report, we present you a 50-year-old female patient who has fallen from the height and presented with signs and symptoms of isolated unilateral oculomotor nerve palsy.

Case Report

A 50-year-old female patient with no past medical history was admitted to our emergency department (ED) due to fall from height in the house. The patient suffered a dropped left upper eyelid and double vision immediately after falling. On

admission, vital signs of the patient were normal. On physical examination, ecchymotic lesions on left temporal region of the head and left orbital were observed. On neurological examination, the patient was oriented and cooperated. Abnormal findings were ptosis of the left eye, minimal deviation of the eye ball laterally, and dilated nonreactive pupil at the same side [Figure 1]. Examination of the right eye was normal with normal range of movements with normal size and reactivity of the pupil. Other system examinations were normal. Trauma X-rays were performed and found to be normal. Furthermore, a computed tomography (CT) scan of the brain was performed in order to exclude a possible bleeding or fracture and reported to be normal [Figure 2]. Furthermore, a magnetic resonance imaging (MRI) was performed and reported by the radiologists as normal [Figure 3]. Blood samples of the patient were obtained and laboratory results were normal. Because the left orbital was ecchymotic, a consultation with an ophthalmologist was performed and a possible direct injury to the eye was excluded. Patient was then consulted with a neurosurgeon and hospitalized with a diagnosis of isolated third nerve palsy.

Discussion

Oculomotor nerve palsy may occur due to cerebrovascular diseases, infiltration, tumor, and severe head injury. Incidence of isolated unilateral third nerve palsy has been reported to be 0–15%.^[1,4,5] The oculomotor nerve innervates the following extraocular muscles of either eye: Superior rectus, inferior rectus, medial rectus, inferior oblique, levator palpebrae, ciliary

Access this article online

Quick Response Code:



Website:
www.asianjns.org

DOI:
10.4103/1793-5482.161169

Address for correspondence:

Dr. Ali Kemal Erenler, Department of Emergency Medicine, Çorum Education and Research Hospital, Hitit University, Çorum, Turkey.
E-mail: akerenler@hotmail.com

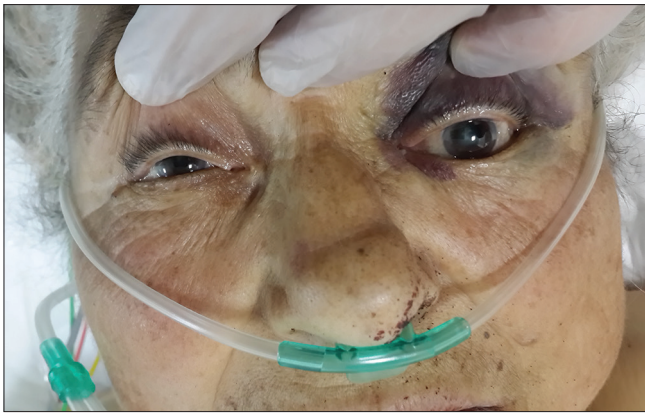

Figure 1: Photograph of the patient with left ptosis of the eyelid, minimal lateral deviation of the eye and dilation of the pupil

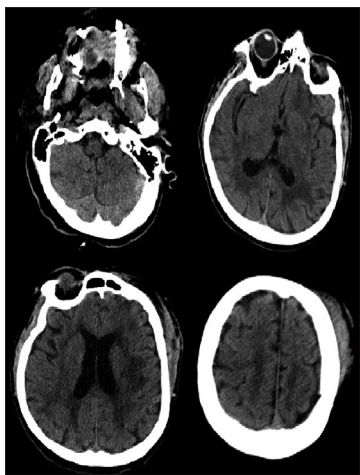


Figure 2: Computed tomography of the patient was reported to be normal

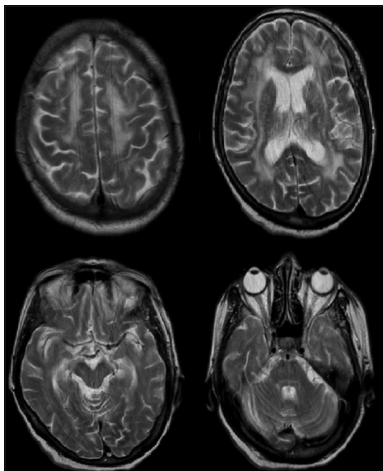


Figure 3: T2-weighted magnetic resonance imaging of the patient was found to be normal

muscle, and iris sphincter. Unilateral oculomotor nerve palsy presents with pupillary dilation and ptosis with the involved eyeball usually infraducted and abducted.^[6]

In our case, accordingly, initial neurological examination of the patient revealed indicators of unilateral isolated oculomotor nerve palsy such as ptosis, minimal lateral deviation of the eye and unresponsive, dilated pupil.

Possible mechanism of the third nerve palsy secondary to head trauma is nerve avulsion usually at the posterior petroclinoid ligaments where the nerve is stretched because of the downward displacement of the brainstem at the time of impact.^[7-9]

Even though it is reported in the literature that the trauma required to damage the oculomotor nerve usually is severe and associated with other neurologic deficits, basilar skull fracture, orbital injury or subarachnoid hemorrhage,^[1,2,10] similar to our case, there are also reports of unilateral isolated palsy of the third cranial nerve after minor trauma.^[6,11]

Brain CT and CT angiography is recommended in acutely traumatized patients with oculomotor nerve palsy to rapidly evaluate blood, bone, supratentorial structure, and vascular anomaly. Cerebral MRI is also indicated because CT scans may fail to detect abnormalities in the midbrain and the oculomotor nerve itself.^[3] However, in our case, both CT and MRI of the brain were found to be normal. Both of the imaging studies remained inadequate and the diagnosis was based on the clinical signs and symptoms of the patient. In the ED setting, we could not perform a CT angiography.

Prognosis of traumatic oculomotor palsy is poor and full recovery is uncommon.

Chen *et al.* reported a similar case and the patient was discharged from the ED for follow-up. After 4 months, oculomotor nerve was partially recovered.^[6] In another report by Najafi and Mehrbod, after a 6-month follow-up, there was a partial recovery.^[11] In our case, neurosurgeons preferred to hospitalize the patient for follow-up examinations and imagings. In the follow-up, possible reasons for oculomotor nerve palsy such as aneurysms and cavernous sinus problems were ruled out. Patient received steroid therapy during hospitalization. After several days, patients were discharged for a close follow-up with minimal recovery.

Conclusion

Isolated unilateral oculomotor nerve palsy is a rare condition usually associated with major trauma accompanying many abnormalities secondary to trauma. However, in some instances, minor traumas may cause unilateral oculomotor nerve palsy without any additional injuries. In such patients, neuroimaging studies may also be normal. A detailed neurological examination is essential for patients with head trauma regardless of its severity.

References

1. Memon MY, Paine KW. Direct injury of the oculomotor nerve in craniocerebral trauma. *J Neurosurg* 1971;35:461-4.
2. Nagaseki Y, Shimizu T, Kakizawa T, Fukamachi A, Nukui H. Primary internal ophthalmoplegia due to head injury. *Acta Neurochir (Wien)* 1989;97:117-22.
3. Kim E, Chang H. Isolated oculomotor nerve palsy following minor head trauma: Case illustration and literature review. *J Korean Neurosurg Soc* 2013;54:434-6.
4. Tiffin PA, MacEwen CJ, Craig EA, Clayton G. Acquired palsy of the oculomotor, trochlear and abducens nerves. *Eye (Lond)* 1996;10:377-84.
5. Elston JS. Traumatic third nerve palsy. *Br J Ophthalmol* 1984;68:538-43.
6. Chen CC, Pai YM, Wang RF, Wang TL, Chong CF. Isolated oculomotor nerve palsy from minor head trauma. *Br J Sports Med* 2005;39:e34.
7. Bruce BB, Biousse V, Newman NJ. Third nerve palsies. *Semin Neurol* 2007;27:257-68.
8. Hanse MC, Gerrits MC, van Rooij WJ, Houben MP, Nijssen PC, Sluzewski M. Recovery of posterior communicating artery aneurysm-induced oculomotor palsy after coiling. *AJNR Am J Neuroradiol* 2008;29:988-90.
9. Chen PR, Amin-Hanjani S, Albuquerque FC, McDougall C, Zabramski JM, Spetzler RF. Outcome of oculomotor nerve palsy from posterior communicating artery aneurysms: Comparison of clipping and coiling. *Neurosurgery* 2006;58:1040-6.
10. Aygun D, Doganay Z, Baydin A, Akyol M, Senel A, Nural MS, *et al.* Posttraumatic pneumocephalus-induced bilateral oculomotor nerve palsy. *Clin Neurol Neurosurg* 2005;108:84-6.
11. Najafi MR, Mehrbod N. Isolated third nerve palsy from mild closed head trauma. *Arch Iran Med* 2012;15:583-4.

How to cite this article: Erenler AK, Yalçın A, Baydin A. Isolated unilateral oculomotor nerve palsy due to head trauma. *Asian J Neurosurg* 2015;10:265-7.

Source of Support: Nil, **Conflict of Interest:** None declared.