

CASE REPORT

Late prevertebral abscess with sinus following anterior cervical corpectomy and fusion

Swapnil D. Bhise, Ambarish A. Mathesul, Pravin Deokate, Ajay S. Chandanwale, Girish D. Bartakke

Department of Orthopaedics, B J Govt Medical College and Sassoon General Hospitals, Pune, Maharashtra, India

ABSTRACT

Anterior cervical discectomy/corpectomy and fusion is performed in degenerative, traumatic and neoplastic etiologies of the cervical spine. This procedure is highly successful and associated with fewer complications. The rates of early and late postoperative infection have been reported to be between 0.1% and 1.6%, the late infections are being very rare. We report a rare case of a 30-year-old HIV negative, non-diabetic male who developed a late prevertebral cervical abscess with discharging sinus over posterior triangle of neck 3 years after an anterior cervical C6 corpectomy with fibular grafting and buttress screw fixation performed elsewhere for traumatic fracture C6 vertebra. The abscess was drained using radical neck dissection approach with complete excision of sinus track and removal of the infected implant. On culture, the organism was found to be beta-hemolytic streptococci, for which appropriate antibiotics were administered postoperatively. The sinus tract completely healed in 3 months time. Late infection as a complication of anterior cervical spine surgeries is rare and is associated with esophageal perforation, implant migration, seeding of the deep prevertebral space with oropharyngeal flora, or from surgical site/bacteremia or with Zenker's diverticulum. Few cases have been reported till date, but none have presented with a sinus tract. We present a case of delayed prevertebral abscess after cervical spine instrumentation that followed abnormal path causing sinus tract to be developed in the site (the posterior triangle of the neck) other than previous incision site. Exploring both triangles of the neck using radical neck dissection approach was essential for complete excision of sinus tract, removal of screw and debridement.

Key words: Prevertebral cervical abscess, radical neck dissection, sinus tract

Introduction

Anterior cervical spine fusion procedures are widely used for stabilization and fixation of the vertebral column in degenerative, neoplastic and traumatic conditions. Cloward's and Smith–Robinson's techniques are well-known fusion procedures of the cervical spine.^[1,2] This procedure is highly successful and complication rate reported is very low. The infection rate associated with this surgery is 0.1–1.6%.^[3] Most infection following these surgeries occurs in the early postoperative period, most of them arise due to poor wound

care and inadequate sterility. The late infection is rare and is associated with esophageal perforation, loose implants, Zenkers diverticulum, bacteremia seeding, or seeding from other infective sites.^[4-11]

We report a unique case of a HIV negative, nondiabetic 30-year-old male patient who developed a late prevertebral cervical abscess with discharging sinus in the right posterior triangle of neck 3 years after anterior corpectomy and instrumented fusion. Investigations showed evidence of sinus with prevertebral abscess without vertebral body involvement. A radical neck dissection approach was taken, complete excision of the sinus tract with the removal of infected implant and adequate debridement was done. Culture sensitive antibiotics to the organism beta-hemolytic streptococci were started this resulted in sinus tract healing and treatment of infection.

Case Report

A 30-year-old man was operated 3 years back at other center for traumatic fracture C6 vertebrae. As per the notes patient had presented with grade three power in both the upper and lower limbs, however, had not received any steroids. Using Cloward's anterior cervical approach-aC6 corpectomy, and fusion was attempted with fibular bone graft and buttress

Access this article online	
Quick Response Code:	Website: www.asianjns.org
	DOI: 10.4103/1793-5482.161172

Address for correspondence:

Dr. Ambarish A. Mathesul, Niranjana, Shri Datta Hospital, Opposite Stella Maris High School, Mahavir Nagar, Wadgaon Sheri, Pune - 411 014, Maharashtra, India.
E-mail: math.amb123@gmail.com

screw fixation. The postoperative period was uneventful, and he had received antibiotics and rehabilitation as per surgeon protocol. Patient was asymptomatic for 3 years during which he had recovered neurologically and was ambulatory. The patient presented to us with a 4 months discharging sinus over the posterior triangle of neck and fever on and off.

He had no complaints of neurological weakness, dysphagia, abnormal neck swelling, loss of appetite, loss of weight and any past history of tuberculosis or tuberculosis contact. A differential diagnosis of tuberculosis infection was made as a posterior triangle of the neck is the most common site for a cold abscess in the neck, also India being a tuberculous endemic country.^[12] Hematological investigations showed raised erythrocyte sedimentation rate (ESR) 45, C-reactive protein (CRP) positive and HIV negative. He was investigated with the plain radiograph of the cervical spine, sinogram for the sinus, and computerized tomography (CT) of the neck. Radiographs showed an unusual single screw fixation with evidence of fusion without any vertebral destruction or lysis which was confirmed with CT scan [Figures 1-3]. The images showed prominent screw head anterior to the bodies supposedly irritating the esophagus, however, esophageal endoscopy was normal. Magnetic resonance imaging was not done as the patient had a metallic implant. Sinogram showed a prevertebral collection near the vicinity of the screw draining in the right posterior neck triangle through sinus track mostly posterior to vessels and sternocleidomastoid. Chest radiographs were normal, and there was no evidence of matted lymphadenopathy elsewhere. The pus culture report from the sinus discharge was negative. After discussing the case with an ear, nose and throat (ENT) surgeon, a decision for surgical debridement and implant removal was taken. Radical neck dissection approach (Crile's approach) was taken as this facilitates in addressing the problems of both the posterior triangle as well as the vertebral bodies.^[13] Subplatysmal flaps were raised. Sternocleidomastoid was separated from the carotid sheath. The carotid sheath was separated from trachea esophageal complex. Inferior thyroid artery was ligated. Prevertebral fascia and muscles were dissected, and the screw was identified and removed. Sinus track was identified and dissected along with a pad of fat in the posterior triangle of the neck behind the sternocleidomastoid and prevertebral muscle and excised up to the vertebral origin. Sinus track was completely epithelized till the vertebra. There was no esophageal perforation. There was bony union, no loose sequestrum or vertebral osteomyelitis. The screw was removed [Figure 4]. The surgical bed was thoroughly debrided and washed with saline, the specimen was sent for high power field, culture sensitivity for bacteria and acid fast bacilli, Zeihl–Neilson staining and histopathology for tuberculosis. The wound was loosely closed in layers over negative suction drain [Figure 5]. Postoperative patient was on Ryle's tube for 5 days and intravenous antibiotics (cefuroxime 1.5 g twice daily for 5 days with amikacin 500 mg twice daily for

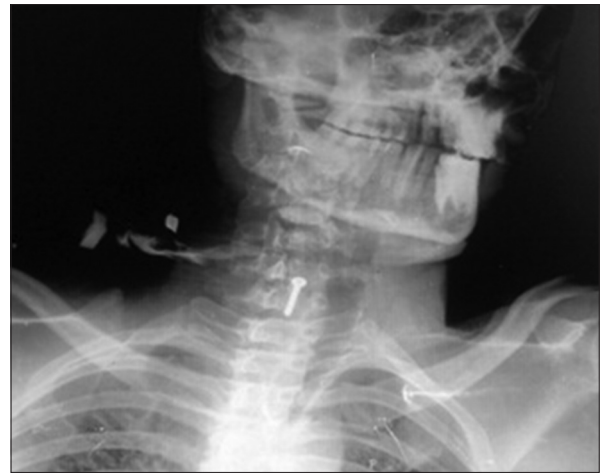

Figure 1: Sinogram showing the path of the sinus track (anteroposterior view)

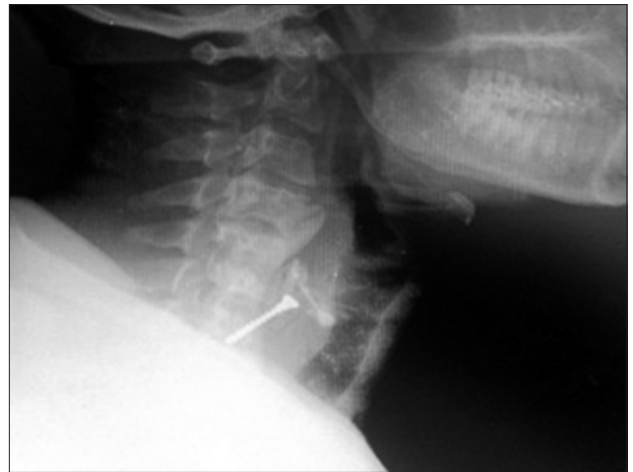

Figure 2: Sinogram lateral view

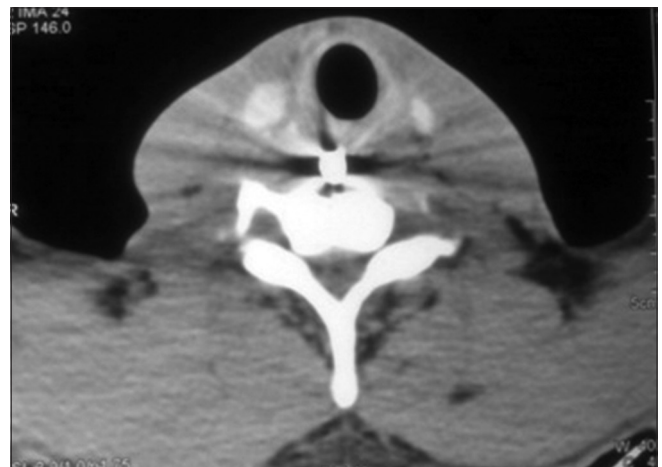


Figure 3: Computerized tomography scan showing the prominent screw head of the implant

5 days) was given. The culture report showed beta-hemolytic streptococci sensitive to linezolid, rest all reports were negative. These were given intravenous for 2 weeks and then

oral for next 3 weeks. Sinus track was healed completely in 3 months time [Figure 6].

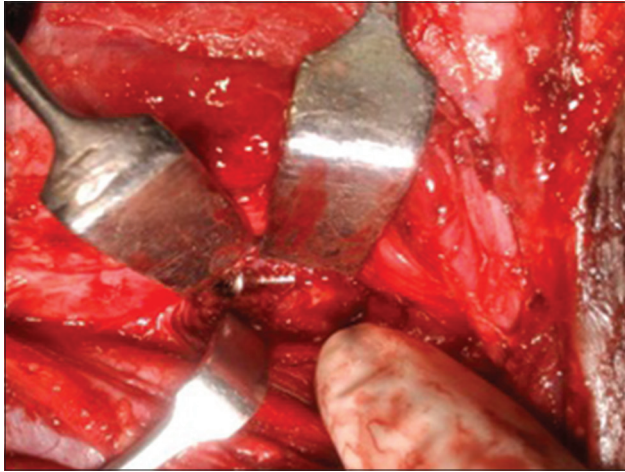


Figure 4: Intra-operative image showing trachea-esophageal complex and carotid vessel with the screw

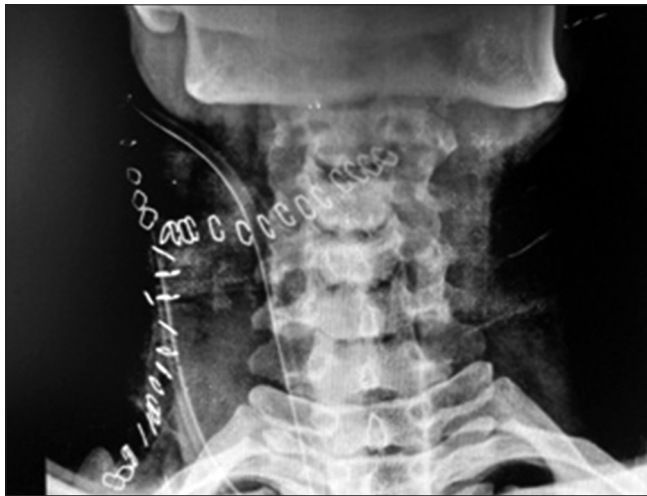

Figure 5: Postoperative radiograph after screw removal and wound closure

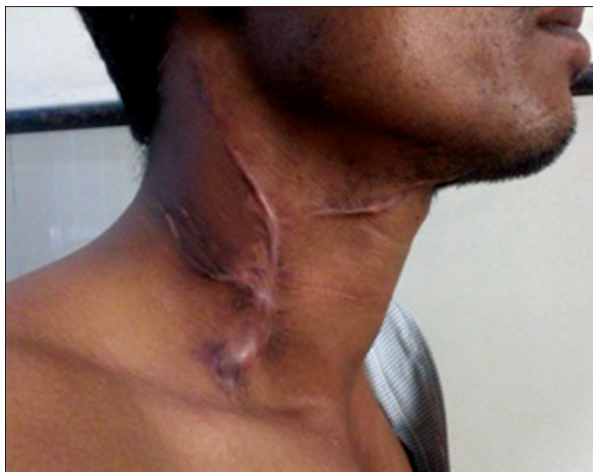

Figure 6: Healed wound and sinus

Discussion

Anterior cervical discectomy/corpectomy and fusion surgery is most commonly performed cervical spine procedures in last few decades.^[10,14] This procedure is performed using the anterior surgical approach described by Cloward and Smith-Robinson.^[1,2,15] The common indications for these procedure include degenerative cervical disc disease, trauma, and tumors. With recent advances in better implant designs and fixation techniques and post-operative rehabilitation the successful outcome (early spine stability, early patient mobilization, improved union rate and reduced hospital stay) has been markedly improved.^[3,4,14]

Though highly successful in terms of outcomes, the complications associated with these procedures can at times be devastating.^[16-18] The complications include Intra operative injuries: To recurrent laryngeal nerve, sympathetic trunk, thoracic duct, pharyngeal or esophageal perforation, lung injury, dural laceration, cerebrospinal fluid leakage, spinal cord contusion, nerve root injury, vascular injuries like: Vertebral artery laceration, carotid artery or jugular vein injury, postoperative complication like: Epidural and wound hematoma, aneurysm formation, respiratory insufficiency, postoperative infection: Superficial and/or deep wound infection, epidural abscess, spondylodiscitis, meningitis, late failure of fixation, deformity, instability and pseudoarthrosis.^[3]

Various studies have reported an overall complication rate ranging from 0.45% to 19.8%, while the infection rate reported is between 0.1% and 1.6%. Most of these infections occur in the early postoperative period with poor wound care and bacteria seeding being the prime cause.^[3,4]

Late infections are uncommon and are associated with esophageal perforation, seeding of the deep prevertebral space with oropharyngeal flora, Zenker's diverticulum, implant migration, or bacterial seeding from a different surgical site/bacteremia.^[5-7,9-11]

In case of late infection with dysphagia high index of suspicion of esophageal perforation has to be kept in mind. Earlier reports show complications like the elimination of screws through the mouth, the gastrointestinal tract, extrusion of the graft and the whole fixation device.^[5,19-21] Clinical symptoms associated with wound infections include neck pain, dysphagia, fever, localized induration, elevated white blood cells count, ESR, and CRP.

Talmi *et al.* have documented six cases of early postoperative prevertebral cervical abscess in quadriplegic patients.^[21] Vrouenraets *et al.* published two cases of esophageal perforation, occurring one at the immediate postoperative period and the other several years after spinal fusion, with severe bleeding from erosion of the common carotid artery.^[22]

Gaudinez *et al.* have reported a large series of esophageal perforation related to cervical fusion procedures. In 34 of 44 cases, the fusion was undertaken for the treatment of cervical fractures, 28 with plate and screws. Cervical osteomyelitis or neck abscess developed in 22 cases. Forty-two patients required surgical repair of the esophageal injury.^[23]

Late infection with prevertebral abscess without esophageal injury is rare, literature search have revealed only two such cases. One report described an acute presentation, which was treated with prompt surgery while other was a delayed presentation.^[4,10] Both cases had no perforation. Two other cases resulted as a result of Zenker's diverticulum.^[9,24,25]

Our case is unique as we report a case of late prevertebral abscess presenting with a sinus in the posterior triangle of the neck, the patient was non-diabetic, -HIV, negative and all investigations were negative for tuberculosis. He also had minimal dysphagia, and esophageal endoscopy revealed no perforation.

Diagnostic studies included complete cell blood count, ESR, CRP, chest radiograph, plain radiographs of the neck and CT to see for the presence of osteomyelitis or prevertebral abscess. Sinogram also was carried out to see the extent of sinus. Sinus that developed, in this case, was in a posterior triangle, and the previous operative scar was anteriorly. So to approach the screw and the infected sinus track, we took radical neck dissection approach with the help of ENT surgeon so that both anterior and posterior triangle of the neck was approached in the same sitting.

In cases of prevertebral cervical abscess due to esophageal perforation, the infecting organisms are usually those belonging to the normal bacterial flora of the pharyngo-esophageal tract and include several types of staphylococci, streptococci, neisseriae, clostridium, etc. Often, the infection is of mixed bacterial nature.^[26]

In our patient, the causative organism was beta-hemolytic streptococcus. An aggressive approach of surgical radical neck dissection approach with sinus tract excision and removal of the implant along with appropriate antibiotics healed the abscess and sinus tract completely.

The main reason for infection was a possibly low-grade infection at the implant site and subsequent development of a prevertebral abscess. The abscess that developed followed the least resistance path, which was damaged with previous surgery while dissecting vertebral margin laterally and that could be one of the reasons for discharging sinus developing in the posterior triangle of the neck. In literature, there is no such report of prevertebral abscess draining in the posterior triangle of the neck and causing chronic discharging sinus.

Conclusion

We report a case of delayed prevertebral abscess after cervical spine instrumentation that followed abnormal path causing sinus track to be developed in the site other than previous incision site (in the posterior triangle of the neck). Hence exploring both triangles of neck using radical neck dissection approach was essential for complete excision of sinus track and removal of the screw.

References

1. Cloward RB. The anterior approach for removal of ruptured cervical disks. *J Neurosurg* 1958;15:602-17.
2. Smith GW, Robinson RA. The treatment of certain cervical-spine disorders by anterior removal of the intervertebral disc and interbody fusion. *J Bone Joint Surg Am* 1958;40-A: 607-24.
3. Fountas KN, Kapsalaki EZ, Nikolakakos LG, Smisson HF, Johnston KW, Grigorian AA, *et al.* Anterior cervical discectomy and fusion associated complications. *Spine (Phila Pa 1976)* 2007;32:2310-7.
4. Christiano LD, Goldstein IM. Late prevertebral abscess after anterior cervical fusion. *Spine (Phila Pa 1976)* 2011;36:E798-802.
5. Geyer TE, Foy MA. Oral extrusion of a screw after anterior cervical spine plating. *Spine (Phila Pa 1976)* 2001;26:1814-6.
6. Lu DC, Theodore P, Korn WM, Chou D. Esophageal erosion 9 years after anterior cervical plate implantation. *Surg Neurol* 2008;69:310-2.
7. Pompili A, Canitano S, Caroli F, Caterino M, Crecco M, Raus L, *et al.* Asymptomatic esophageal perforation caused by late screw migration after anterior cervical plating: Report of a case and review of relevant literature. *Spine (Phila Pa 1976)* 2002;27:E499-502.
8. Solerio D, Ruffini E, Gargiulo G, Camandona M, Raggio E, Solini A, *et al.* Successful surgical management of a delayed pharyngo-esophageal perforation after anterior cervical spine plating. *Eur Spine J* 2008;17 Suppl 2:S280-4.
9. Summers LE, Gump WC, Tayag EC, Richardson DE. Zenker diverticulum: A rare complication after anterior cervical fusion. *J Spinal Disord Tech* 2007;20:172-5.
10. Violon P, Patay Z, Braeckeveldt J, Pirotte B, Kentos A, Brotchi J, *et al.* An atypical infectious complication of anterior cervical surgery. *Neuroradiology* 1997;39:278-81.
11. von Rahden BH, Stein HJ, Scherer MA. Late hypopharyngo-esophageal perforation after cervical spine surgery: Proposal of a therapeutic strategy. *Eur Spine J* 2005;14:880-6.
12. Sharma SK, Mohan A. Tuberculosis: From an incurable scourge to a curable disease – Journey over a millennium. *Indian J Med Res* 2013;137:455-93.
13. Mazzaferrri EL, Kloos RT. Clinical review 128: Current approaches to primary therapy for papillary and follicular thyroid cancer. *J Clin Endocrinol Metab* 2001;86:1447-63.
14. Jin SW, Kim SH, Choi JI, Ha SK, Lim DJ. Late infection from anterior cervical discectomy and fusion after twenty years. *Korean J Spine* 2014;11:22-4.
15. Espersen JO, Buhl M, Eriksen EF, Fode K, Klaerke A, Krøyer L, *et al.* Treatment of cervical disc disease using Cloward's technique. I. General results, effect of different operative methods and complications in 1,106 patients. *Acta Neurochir (Wien)* 1984;70:97-114.
16. Bertalanffy H, Eggert HR. Complications of anterior cervical discectomy without fusion in 450 consecutive patients. *Acta Neurochir (Wien)* 1989;99:41-50.
17. Fielding JW. Complications of anterior cervical disk removal and fusion. *Clin Orthop Relat Res* 1992;284:10-3.
18. Spanu G, Marchionni M, Adinolfi D, Knerich R. Complications following anterior cervical spine surgery for disc diseases: An analysis of ten years experience. *Chir Organi Mov* 2005;90:229-40.
19. Ruoff KL. *Streptococcus anginosus* ("Streptococcus milleri"): The unrecognized pathogen. *Clin Microbiol Rev* 1988;1:102-8.
20. Schultz KD Jr, McLaughlin MR, Haid RW Jr, Comey CH, Rodts GE Jr,

- Alexander J. Single-stage anterior-posterior decompression and stabilization for complex cervical spine disorders. *J Neurosurg* 2000;93:214-21.
21. Talmi YP, Knoller N, Dolev M, Wolf M, Simansky DA, Keller N, *et al.* Postsurgical prevertebral abscess of the cervical spine. *Laryngoscope* 2000;110:1137-41.
 22. Vrouenraets BC, Been HD, Brouwer-Mladin R, Bruno M, van Lanschoot JJ. Esophageal perforation associated with cervical spine surgery: Report of two cases and review of the literature. *Dig Surg* 2004;21:246-9.
 23. Gaudinez RF, English GM, Gebhard JS, Brugman JL, Donaldson DH, Brown CW. Esophageal perforations after anterior cervical surgery. *J Spinal Disord* 2000;13:77-84.
 24. Frot-Martin B, Carlier RY, Morand-Blot V, Faye A, Bernard L, Vallée C. Zenker's diverticulum associated with multilevel cervical osteomyelitis. *Spine (Phila Pa 1976)* 2001;26:E193-7.
 25. Sood S, Henein RR, Girgis B. Pharyngeal pouch following anterior cervical fusion. *J Laryngol Otol* 1998;112:1085-6.
 26. Wong DT, Fehlings MG, Massicotte EM. Anterior cervical screw extrusion leading to acute upper airway obstruction: Case report. *Spine (Phila Pa 1976)* 2005;30:E683-6.

How to cite this article: Bhise SD, Mathesul AA, Deokate P, Chandanwale AS, Bartakke GD. Late prevertebral abscess with sinus following anterior cervical corpectomy and fusion. *Asian J Neurosurg* 2015;10:272-6.

Source of Support: Nil, **Conflict of Interest:** None declared.