

CASE REPORT

Symptomatic lumbosacral perineural cysts: A report of three cases and review of literature

Mayur Sharma, Vernon Velho, Rahul Mally, Shadma W. Khan

Department of Neurosurgery, Grant Medical College and Sir J. J. Group of Hospitals, Mumbai, Maharashtra, India

ABSTRACT

Lumbosacral perineural cysts (Tarlov's cysts) are nerve root cysts, which are usually asymptomatic and are detected incidentally on imaging. These cysts are rare with an incidence of 4.6%. We report three cases of Lumbosacral Tarlov's cysts, which presented with cauda equina syndrome and radicular pain syndrome. Two of our patients had symptoms of cauda equina syndrome, and one had acute sciatica. Complete excision of the cyst was achieved in two patients and marsupialization of the cyst was done in another patient due to its large size and dense adherence to the sacral nerve roots. All the patients were relieved of the radicular pain with no new neurological deficit following surgery. Symptomatic lumbosacral Tarlov's cyst is a rare lesion, and the presentation can be low back pain, cauda equina syndrome or sciatica. Therefore, this entity should be kept in the differential diagnosis of patients presenting with these symptoms. Complete Surgical excision of these symptomatic cysts is the treatment of choice to achieve a cure.

Key words: cyst, lumbosacral, perineural, symptomatic

Introduction

Lumbosacral perineural cyst (Tarlov's cyst) is a nerve root cyst, which arises between the layers of the perineurium and endoneurium near the dorsal root ganglion. The incidence of Tarlov's cyst is approximately 4.6%. These cysts are usually asymptomatic and are incidental on imaging done for some other indication. Symptomatic cysts are rare and the presentation can be low back pain, cauda equina syndrome or sciatica. We report three such cases which presented with the cauda equina syndrome (two cases) and radicular pain syndrome (one case).

Case Reports

Case 1

A 42-year-old male patient admitted with a history of low back pain of 2 weeks duration. The pain was sudden in onset

and radiating to the left lower limb. There was associated numbness on the medial aspect of the left lower limb. There was no history of trauma or lifting heavy weights. On examination, power was normal in both lower limbs. Pain and temperature sensations were diminished along left L4 dermatome by 50%. Reflexes were normal in both lower limbs and plantars were downgoing bilaterally. Magnetic resonance imaging (MRI) (T2-weighted) of the lumbosacral spine showed a well-defined cystic lesion along the traversing left L4 nerve root suggestive of Tarlov's cyst [Figure 1]. Electromyography and nerve conduction studies were suggestive of left L4 radiculopathy. The patient was operated on by left L3 hemilaminectomy and medial facetectomy. The cyst was anterolateral to the nerve root during intraoperative excision. The cyst was thin-walled, translucent and the content was clear jelly-like fluid. Complete excision of the cyst was achieved.

Case 2

A 48-year-old female presented with low back pain of 2 years duration. The pain was associated with numbness in both the lower limbs for the last 2 years. Patient also noticed weakness in both lower limbs for 1½ years (more in the left lower limb compared to the right lower limb). The weakness was gradual in onset and progressive involving both the proximal and distal muscle groups. She also noticed bladder incontinence with urgency for the last 6 months. On examination, higher mental functions were normal. Nutrition was normal in both lower limbs. Power was reduced in both lower limbs. The patient was able to move the muscles of the right thigh, right leg, right foot and left thigh against resistance

Access this article online

Quick Response Code:



Website:

www.asianjns.org

DOI:

10.4103/1793-5482.161177

Address for correspondence:

Dr. Mayur Sharma, Department of Neurosurgery,
Grant Medical College and Sir J. J. Group of Hospitals, Byculla,
Mumbai - 400 008, Maharashtra, India.
E-mail: drmayursharmaneuro@gmail.com

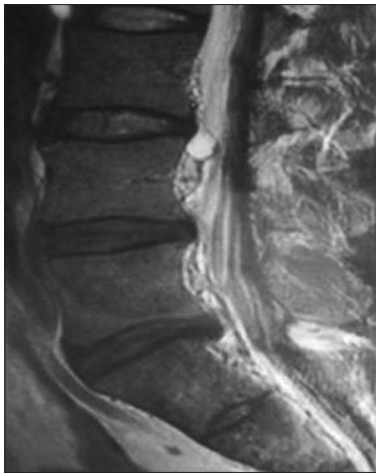


Figure 1: Magnetic resonance imaging scan (T2-weighted sequence, sagittal view) of the lumbosacral spine showing a well-defined cystic lesion along the traversing left L4 nerve root suggestive of perineural cyst

(4/5 according to Medical Research Council Scale). However in the distal left lower limb, the patient was able to move the muscles against gravity but no movement was possible against resistance (3/5 according to Medical Research Council Scale). Pain and temperature sensations were absent along left L5, S1, S2 dermatome. Ankle reflex was absent on the left side. The rest of the reflexes were normal. Plantars were downgoing bilaterally. MRI (T2-weighted) of the lumbosacral spine showed an intraspinal meningeal cyst extending from L5 to S4, extending into right neural foramina from L5 to S3 and into left neural foramina from S1 to S3 with pressure erosion of the surrounding bone [Figure 2]. L5-S2 laminectomy was performed in the prone position. The cyst had both extradural and an intradural component with a pin point communication with the subarachnoid space. Marsupialization of the cyst was performed, and the communication was sealed using fibrin glue. Multiple sacral nerve roots were seen in the wall of the cyst, and the content of the cyst was clear suggestive of cerebrospinal fluid (CSF).

Case 3

A 28-year-old female presented with pain in both lower limbs for the last 2 years. The pain was more in the left lower limb and aggravated since last 6 months. It was associated with numbness on the lateral aspect of left lower limb. On examination, higher mental functions were normal. Power was normal at both knees and hips but the power of both extensor hallucis longus/flexor hallucis longus was reduced and movement was possible only against less than normal resistance (4/5 according to Medical Research Council Scale). Pain and temperature sensations were diminished along left L5-S1 dermatome by 50%. Ankle reflex was diminished on the left side. The rest of the reflexes were normal, and both the plantar reflexes were down going. X-ray of the lumbosacral spine was suggestive of spondylolysis of pars interarticularis

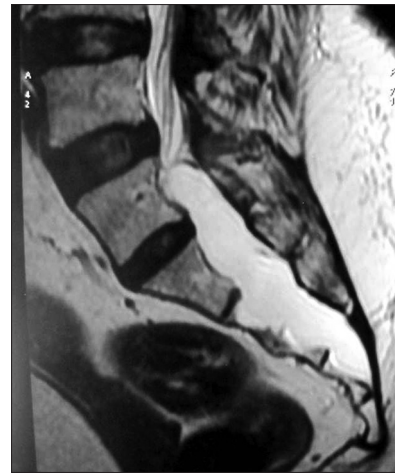

Figure 2: Magnetic resonance imaging scan (T2-weighted sequence, sagittal view) of the lumbosacral spine showing an intraspinal meningeal cyst extending from L5 to S4, extending into right neural foramina from L5 to S3 and left neural foramina from S1 to S3 with pressure erosion of the surrounding bone

of L5. MRI (T2-weighted) of the lumbosacral spine showed a well-defined cystic lesion along the traversing left L5-S1 nerve root similar to case 1 [Figure 3]. Electromyography and nerve conduction studies were suggestive of chronic partial denervation with reinnervation in left L5 and S1 dermatome. Left L4-S1 laminectomy was done, and complete excision of the cyst was achieved. The cyst was thin walled and translucent. The content of the cyst was CSF.

Histopathological examination [Figure 4] case 2 of the cyst wall in all the cases revealed fibro-collagenous tissue intermingled with the nerve fascicles. Fibroblastic proliferation with mononuclear infiltration was occasionally seen. These histopathological features were consistent with the classical description of Tarlov's cyst in the literature. All the patients were relieved of the radicular pain with no new neurological deficit following surgery. Patient with a complex sacral perineural cyst (case 2) developed postoperative CSF leak which was managed conservatively and healed within a period of 10 days. There are no recurrences in all the three cases till the recent follow-up.

Discussion

A perineural cyst is a nerve root cyst which arises between the layers of the perineurium and endoneurium near the dorsal root ganglion. The arachnoid membrane of the nerve root in the spinal dura mater is continuous with the cyst wall. The main part of the cyst wall is formed by the nerve fibers or reticulum. These cysts were first described by Tarlov in 1938 when he reported five such cases as an incidental finding during the autopsy.^[1,2] The prevalence of Tarlov's cyst is about 4.6% in the general adult population with back pain.^[1,3] About 70% of the cysts are asymptomatic, 17% have additive effects on other pathological entities and only 13% are symptomatic.^[1]

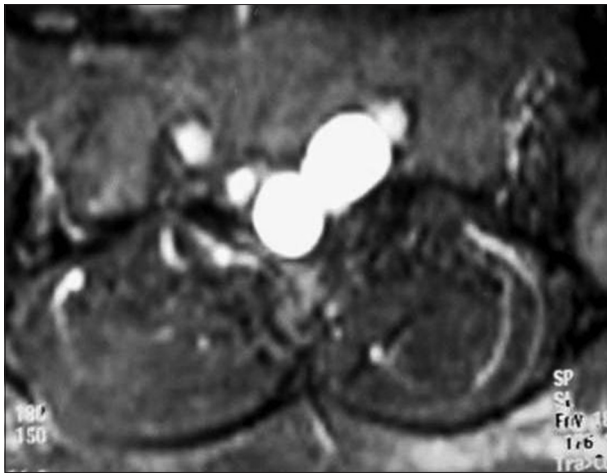

Figure 3: Magnetic resonance imaging scan (T2 weighted sequence, axial view) of the lumbosacral spine showing a well-defined cystic lesion along the traversing left L5-S1 nerve root suggestive of perineural cyst

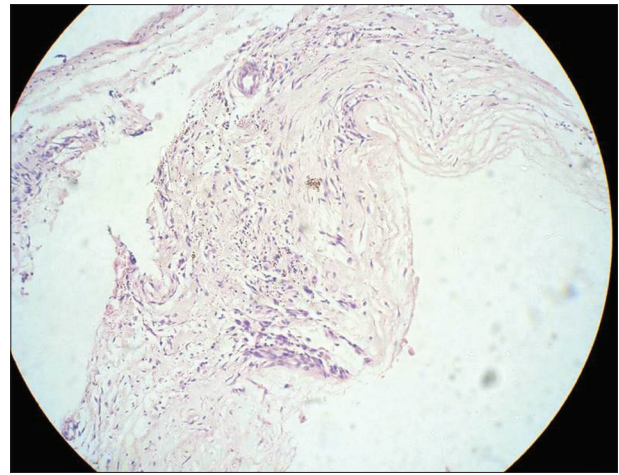


Figure 4: Histopathological examination showing the fibrocollagenous tissue intermingled with the nerve fascicles. Occasional mononuclear infiltration can also be seen

They are more common in females,^[3,4] which corroborates to our report (two females and one male).

The common clinical presentation of these cysts includes low back pain, radicular pain or cauda equina syndrome depending on their location, size and relationship to the surrounding nerve roots. In our study, two patients presented with the cauda equina syndrome and one with sciatica. Sacral tenderness may also be present in some cases. Symptoms are usually exacerbated by standing, walking, or coughing and relieved by bed rest. The cysts often extend circumferentially around the involved nerves and can cause bony erosion along with compression and impingement on the surrounding structures. Sometimes these cysts can be multiple.^[2] Plain Radiographs may reveal the characteristic bony erosion of the neural foramina and the spinal canal.^[5] Computed tomography (CT) scan of the lumbosacral spine may show a cystic lesion at the foramina isodense to the CSF.^[6] MRI is the investigation of choice for the diagnosis of perineural cysts. These cysts are hypointense on T1-weighted images, hyperintense on T2-weighted images and show no enhancement with gadolinium contrast.^[7] Myelography shows the characteristic delayed filling of the cyst 1 h after the injection of contrast medium.^[8]

The pathogenesis of Tarlov's cyst is unclear. Tarlov suggested that the hemorrhage into the subarachnoid space causes accumulation of red blood cells, which subsequently lead to the blockage of the venous drainage in the perineurium and epineurium. These engorged veins subsequently rupture and form the cyst. There was the history of trauma in four out of his seven patients in his seminal article.^[1] These cysts are congenital in origin due to the proliferation of arachnoid within the nerve root sleeve according to other reports.^[9] Treatment of Tarlov's cyst is indicated when they are symptomatic, and there is contentious debate regarding the single modality

of treatment. Tarlov proposed complete excision of the cyst along with the posterior nerve root and ganglion with good outcomes.^[2] Caspar described the microsurgical excision of the cyst combined with duraplasty and plication of the cyst wall.^[4] CT scan guided aspiration of the cyst was also described as an effective method to relieve radicular pain.^[3] Other management options include obliterating the cyst using percutaneous fibrin glue, cyst-arachnoid shunt, cyst-peritoneal shunt, or a lumboperitoneal shunt.^[10,11] The complications associated with surgical excision are CSF fistula, infection, and neurological deficits.

Conclusion

Symptomatic Tarlov's cysts are rare lesions. The common presenting symptoms include low back pain, cauda equina syndrome or sciatica. Therefore, these cysts should be kept in the differential diagnosis of patients presenting with such symptoms. Surgical excision of the symptomatic cysts is the treatment of choice to achieve a cure.

Acknowledgment

We would like to thank our Dean, Sir J. J. group of hospitals for allowing us to publish the hospital record.

References

1. Langdown AJ, Grundy JR, Birch NC. The clinical relevance of Tarlov cysts. *J Spinal Disord Tech* 2005;18:29-33.
2. Tarlov IM. Spinal perineurial and meningeal cysts. *J Neurol Neurosurg Psychiatry* 1970;33:833-43.
3. Paulsen RD, Call GA, Murtagh FR. Prevalence and percutaneous drainage of cysts of the sacral nerve root sheath (Tarlov cysts). *AJNR Am J Neuroradiol* 1994;15:293-7.
4. Caspar W, Papavero L, Nabhan A, Loew C, Ahlhelm F. Microsurgical excision of symptomatic sacral perineurial cysts: A study of 15 cases. *Surg Neurol* 2003;59:101-5.
5. Taveras JM, Wood EH. *Diagnostic Neuroradiology*. 2nd ed., Vol. 2. Baltimore: Williams and Wilkins; 1976. p. 1139-45.

6. Tabas JH, Deeb ZL. Diagnosis of sacral perineural cysts by computed tomography. *J Comput Tomogr* 1986;10:255-9.
7. Rodziewicz GS, Kaufman B, Spetzler RF. Diagnosis of sacral perineural cysts by nuclear magnetic resonance. *Surg Neurol* 1984;22:50-2.
8. Nishiura I, Koyama T, Handa J. Intracanalicular perineural cyst. *Surg Neurol* 1985;23:265-9.
9. Fortuna A, La Torre E, Ciappetta P. Arachnoid diverticula: A unitary approach to spinal cysts communicating with the subarachnoid space. *Acta Neurochir (Wien)* 1977;39:259-68.
10. Patel MR, Louie W, Rachlin J. Percutaneous fibrin glue therapy of meningeal cysts of the sacral spine. *AJR Am J Roentgenol* 1997;168:367-70.
11. Morio Y, Nanjo Y, Nagashima H, Minamizaki T, Teshima R. Sacral cyst managed with cyst-subarachnoid shunt: A technical case report. *Spine (Phila Pa 1976)* 2001;26:451-3.

How to cite this article: Sharma M, Velho V, Mally R, Khan SW. Symptomatic lumbosacral perineural cysts: A report of three cases and review of literature. *Asian J Neurosurg* 2015;10:222-5.

Source of Support: Nil, Conflict of Interest: None declared.