

## CASE REPORT

# Vascular injury after lumbar discectomy mimicking appendicitis: Report of a case

Hsiao-Yue Wee<sup>1</sup>, Che-Chuan Wang<sup>2</sup>, Jinn-Rung Kuo<sup>2,3</sup>

<sup>1</sup>Department of Neurosurgery, Chi Mei Medical Center, Liouying, <sup>2</sup>Department of Neurosurgery, Chi Mei Medical Center, YongKang, <sup>3</sup>Department of Biotechnology, Southern Taiwan University of Science and Technology, Tainan, Taiwan

## ABSTRACT

Right lower quadrant pain after a lumbar discectomy is a rare condition. We report on a 29-year-old man who developed right lower quadrant pain 12 h after lumbar discectomy due to the formation and rupture of a right iliac artery pseudoaneurysm. The diagnostic laparoscopy was done under the impression of acute appendicitis but showed a retroperitoneal hematoma. An emergency abdominal computed tomography confirmed a right iliac artery pseudoaneurysm rupture. We performed a transarterial embolization with multiple metallic coils in the aneurysm cavity and connected the proximal and distal right internal iliac artery because his hemodynamics became progressively unstable. In this article, in addition to presenting the clinical course of an unusual case, we also wanted to emphasize that patients with right lower quadrant pain could be presenting an early sign of pseudoaneurysm formation and rupture after a lumbar discectomy.

**Key words:** Acute appendicitis, lumbar discectomy, pseudoaneurysm, transarterial embolization

## Introduction

Lumbar discectomy is a common and relatively safe procedure in spinal surgery.

However, vascular injury is occasionally reported.<sup>[1-7]</sup> Without prompt diagnosis, the prognosis is dismal, even fatal.<sup>[2]</sup> Here, we report a patient with right lower quadrant pain that was caused by internal iliac artery injury after lumbar discectomy mimicking appendicitis.

## Case Report

A 29-year-old man had received an L4–L5 laminectomy and discectomy surgery 3 years prior to his admission to our ward complaining of low back pain radiating to the right lower leg for 3 months. He underwent an L4/S1 laminectomy + L4/5 and L5/S1 discectomy operation. Twelve hours later, he developed right lower quadrant

pain, with suspicion of acute appendicitis. The diagnostic laparoscopy showed a retroperitoneal hematoma and no acute appendicitis [Figure 1]. An emergency abdominal computed tomography showed the rupture of a pseudoaneurysm from the right internal iliac artery [Figure 2]. His hemodynamic status became unstable, so we performed a transarterial embolization with multiple metallic coils in the aneurysm cavity and connected the proximal and distal right internal iliac artery after angiography diagnosis [Figures 3 and 4]. After the embolization and a massive fluid and blood transfusion, his hemodynamic status stabilized. Finally, he was discharged smoothly and reported no new neurological problems 10 days after admission.

## Discussion

Vascular injury after lumbar surgery is rare, and the incidence has been estimated to be 0.01–0.05%.<sup>[1]</sup> Among the most common types of injuries are arteriovenous fistulas with or without pseudoaneurysms (67%), lacerations (30%), and less frequently, a pseudoaneurysm alone (3%).<sup>[1]</sup> Without prompt diagnosis and management, the prognosis is very poor, even fatal.<sup>[2]</sup>

Most of the reported incidents occurred during a discectomy at the L4–L5 or L5–S1 levels.<sup>[1]</sup> At this level, the most commonly injured vessel is the left common iliac artery, followed by the left common iliac vein because of their anatomical proximity to the operation site and their immobility.<sup>[3]</sup> As demonstrated in our patient, right internal iliac artery pseudoaneurysm formation and rupture is relatively rare as compared to the previous reports.

### Access this article online

#### Quick Response Code:



#### Website:

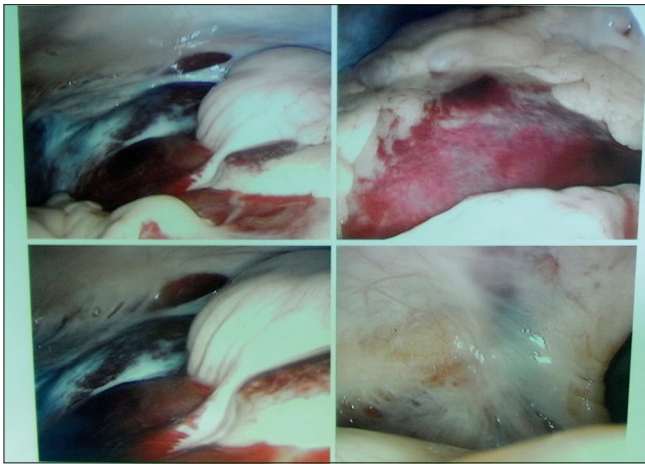
www.asianjns.org

#### DOI:

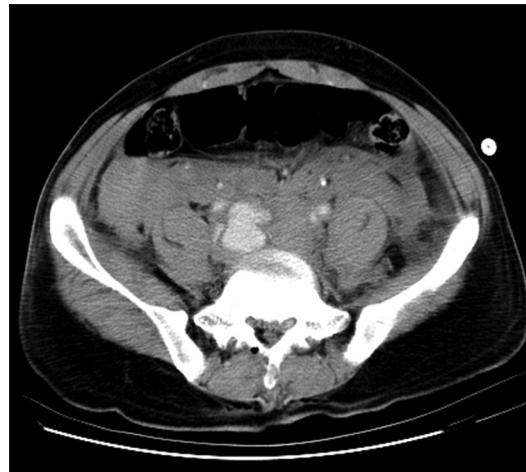10.4103/1793-5482.161186

### Address for correspondence:

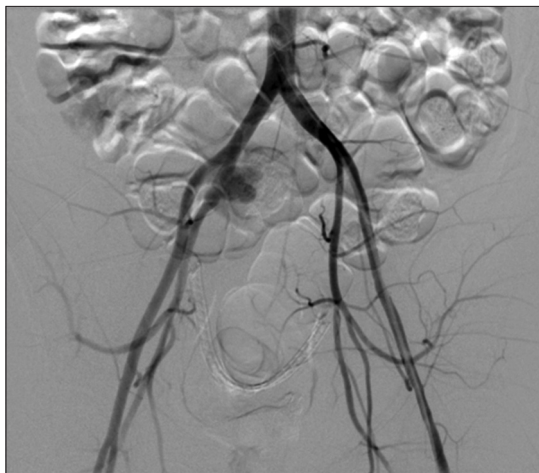
Dr. Jinn-Rung Kuo, Department of Neurosurgery, Chi Mei Medical Center, No. 901 Chung-Hwa Road, Yung-Kang City, Tainan 710, Taiwan. E-mail: kuojinnrung@gmail.com



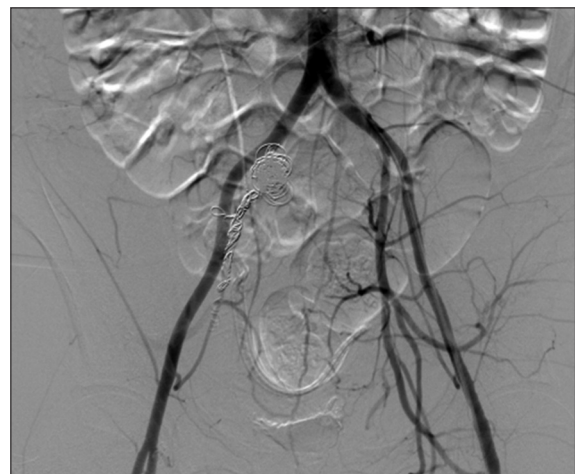
**Figure 1:** Diagnostic laparoscopy was done under the impression of acute appendicitis but showed a retroperitoneal hematoma with normal appendix appearance



**Figure 2:** Abdominal computed tomography showed pseudoaneurysm formation from right internal iliac artery and massive retroperitoneal hematoma



**Figure 3:** Conventional angiography demonstrating extravasation of contrast from right internal iliac artery



**Figure 4:** Conventional angiography shows the transarterial embolization with multiple coils successfully deployed to obliterate the pseudoaneurysm aneurysm cavity and the connection of the proximal and distal right internal iliac artery

The symptoms of vascular injury may be immediately recognized by hypotension, tachycardia, or even shock if there has been excessive blood loss. Delayed onset of symptoms may occur resulting from the formation of an arteriovenous fistula or pseudoaneurysm.<sup>[1,4]</sup> In our case, the overnight development of a pseudoaneurysm and the initial presentation as right lower quadrant pain mimicking acute appendicitis were unusual. However, if we consider vascular injury during a lumbar discectomy as a highly suspicious possibility, we can avoid misdiagnosis and delayed treatment.

In this case, the possible mechanisms for the vessel injury may be related to the fibrotic tissue around the diseased disc and the adhesion of vessels to the disc during the previous discectomy procedure.<sup>[1,5]</sup> Deep intrusion of the pituitary rongeur to cause arterial wall disruption in the presence of advanced disc disease may be another cause.<sup>[5]</sup> We consider preoperative measurement of the exact diameter of the lumbar

disc, average 33–56 mm as reported by Anda *et al.*, to be helpful to avoid the instrument perforating anteriorly.<sup>[6]</sup>

Iliac artery injury following lumbar discectomy could be treated by direct surgical repair of the damaged vessel,<sup>[7]</sup> a single balloon inflation,<sup>[8]</sup> insertion of a covered stent,<sup>[9]</sup> and coil embolization for a bleeding vessel.<sup>[10]</sup> In our case, we chose transarterial embolization with multiple metallic coils based on the fact that our patient's hemodynamics were progressively compromised. Instead of sending the patient to the operating room, we determined that occluding the lesion on the angiography table to stop the bleeding immediately after the diagnosis.

In this case report, besides present the unusual clinical course of our patient, we want to emphasize that right lower quadrant pain could be an early sign of pseudoaneurysm

formation and rupture in patients following a lumbar discectomy. Early recognition of iliac artery injury is very important for beginning prompt and appropriate treatment to improve the overall prognosis.

## References

1. Papadoulas S, Konstantinou D, Kourea HP, Kritikos N, Haftouras N, Tsolakis JA. Vascular injury complicating lumbar disc surgery. A systematic review. *Eur J Vasc Endovasc Surg* 2002;24:189-95.
2. Inamasu J, Guiot BH. Vascular injury and complication in neurosurgical spine surgery. *Acta Neurochir (Wien)* 2006;148:375-87.
3. Bingol H, Cingoz F, Yilmaz AT, Yasar M, Tatar H. Vascular complications related to lumbar disc surgery. *J Neurosurg* 2004;100:249-53.
4. Luan JY, Li X. A misdiagnosed iliac pseudoaneurysm complicated lumbar disc surgery performed 13 years ago. *Spine (Phila Pa 1976)* 2012;37:E1594-7.
5. Dösoglu M, Is M, Pehlivan M, Yildiz KH. Nightmare of lumbar disc surgery: Iliac artery injury. *Clin Neurol Neurosurg* 2006;108:174-7.
6. Anda S, Aakhus S, Skaanes KO, Sande E, Schrader H. Anterior perforations in lumbar discectomies. A report of four cases of vascular complications and a CT study of the prevertebral lumbar anatomy. *Spine (Phila Pa 1976)* 1991;16:54-60.
7. Chao CM, Wu CD, Sung KC, Lin WT, Lee KK, Lai CC. Right iliac aortic aneurysmal hemorrhage as a complication of lumbar discectomy. *World Neurosurg* 2013;80:901.e7-8.
8. Olcay A, Keskin K, Eren F. Iliac artery perforation and treatment during lumbar disc surgery by simple balloon tamponade. *Eur Spine J* 2013;22 Suppl 3:S350-2.
9. Hong SJ, Oh JH, Yoon Y. Percutaneous endovascular stent-graft for iliac pseudoaneurysm following lumbar discectomy. *Cardiovasc Intervent Radiol* 2000;23:475-7.
10. de Godoy JM, Reis LF, Casagrande M, Braile DM. Treatment of internal iliac artery pseudoaneurysm by an endovascular approach. *J Chin Med Assoc* 2005;68:435-6.

**How to cite this article:** Wee HY, Wang CC, Kuo JR. Vascular injury after lumbar discectomy mimicking appendicitis: Report of a case. *Asian J Neurosurg* 2015;10:243-5.

**Source of Support:** Nil, **Conflict of Interest:** None declared.