

Decompressive craniectomy in malignant middle cerebral artery infarct: An institutional experience

Hanish Bansal, Ashwani Chaudhary, Apinderpreet Singh, Birinder Paul¹, Rajveer Garg

Departments of Neurosurgery and ¹Neurology, Dayanand Medical College and Hospital, Ludhiana, Punjab, India

ABSTRACT

Introduction: Decompressive craniectomy as a surgical treatment for brain edema has been performed for many years and for several different pathophysiologies, including malignant middle cerebral artery (MCA) infarct. The purpose of this article was to share author's experience with decompressive craniectomy in malignant MCA infarct with special emphasis on patients older than 60 years and those operated outside 48 h after onset of stroke.

Materials and Methods: Totally, 53 patients who underwent decompressive craniectomy after malignant MCA infarction between January 2012 and May 2014 at tertiary care hospital were analyzed for preoperative clinical condition, timing of surgery, cause of infarction, and location and extension of infarction. The outcome was assessed in terms of mortality and scores like modified Rankin scale (mRS).

Results: Totally, 53 patients aged between 22 and 80 years (mean age was 54.92 ± 11.8 years) were analyzed in this study. Approximately, 60% patients were older than 60 years. Approximately, 74% patients operated within 48 h (25 patients) had mRS 0–3 at discharge while 56% patients operated after 48 h had mRS 0–3 at discharge which is not significant statistically. 78% patients aged below 60 years had mRS 0–3 at discharge while only 38% patients aged above 60 years had mRS 0–3 at discharge which was statistically significant ($P < 0.008$).

Conclusion: Decompressive craniectomy has reduced morbidity and mortality especially in people aged below 60 years and those operated within 48 h of malignant MCA stroke though those operated outside 48 h of stroke also fare well neurologically, there is no reason these patients should be denied surgery.

Key words: Decompressive craniectomy, intracranial pressure, malignant middle cerebral artery infarct

Introduction

Decompressive craniectomy as a surgical treatment for brain edema has been performed for many years and for several different pathophysiologies including traumatic brain injury and nontraumatic brain injury (like malignant cerebral artery infarction, subarachnoid hemorrhage, cerebral venous thrombosis, encephalitis, demyelinating disorders, and refractory cerebral edema).

The purpose of this article was to share author's experience with decompressive craniectomy in malignant middle cerebral artery (MCA) infarct with special emphasis on patients older than 60 years and those operated outside 48 h after onset of stroke. The surgical procedure involves temporarily removal of a large segment of the cranium (fragments of frontal, temporal, and parietal bones) followed by opening of dura in order to provide extra space into which the injured or ischemic brain can expand. Decompressive craniectomy has largely replaced the removal of brain tissue (i.e. lobectomy) as the preferred surgical option.^[1]

The concept of decompression first introduced by Annandale in late 1890. Later, Kocher in 1901 and Harvey Cushing in 1905 proposed decompressive craniectomy for relieving raised intracranial pressure. Unfortunately, technique got limited due to poor esthetical results.^[2] The landmark work of Guerra *et al.* (decompressive craniectomy for traumatic brain swelling) established the procedure as an appropriate therapy for refractory intracranial pressure (ICP) of any origin in 1999.^[3]

We present out the experience of decompressive craniectomy in last 2½ years in malignant MCA infarct.

Access this article online	
Quick Response Code:	Website: www.asianjns.org
	DOI: 10.4103/1793-5482.161191

Address for correspondence:

Dr. Hanish Bansal, Department of Neurosurgery,
10-B Udhm Singh Nagar, Ludhiana, Punjab, India.
E-mail: y2khanish@rediffmail.com

Aims

- Role of decompressive craniectomy in malignant MCA infarct in patients aged below 60 years and above 60 years
- Factors influencing the outcome of patients, in order to create awareness of the indications and decision-making processes.

Materials and Methods

This retrospective study included a total of 53 patients who underwent decompressive craniectomy after malignant MCA infarction between January 2012 and May 2014 at the tertiary care hospital. Clinical characteristics included preoperative clinical condition, timing of surgery, cause, location, and extension of infarction. In addition, the time delay from the onset of symptoms to surgery and preoperative signs of herniation and their relation to the final outcome was analyzed. The final outcome was assessed in terms of mortality and scores such as modified Rankin scale (mRS). Functional outcome was divided into two groups: Favorable outcome (mRS score 0–3) versus poor outcome (mRS score 4–6).

On admission, cerebral pathology was revealed by neuroradiological studies (computed tomography [CT]/magnetic resonance imaging [MRI]). The presence of a midline shift was measured by observation of the distance of septum pellucidum that deviated from the line between anterior and posterior falx cerebri at its attachment to the inside of the calvarium. The eligibility criteria for determining for carrying out decompressive craniectomy in malignant MCA infarction in our study were large MCA infarct defined as an ischemic lesion volume $>150 \text{ cm}^3$ on diffusion-weighted MRI or CT evidence of at least $>50\%$ MCA territory infarction by visual inspection, clinical or radiological evidence of herniation and decrease in level of consciousness to a score 1 or greater on item 1a of the National Institute of Health Stroke Scale. Patients with Glasgow coma scale (GCS) <4 , coma with two dilated pupil and absent brainstem reflexes were excluded from the study.

Each patient was fully resuscitated, investigated, and treated in Intensive Care Unit after first admission. Basic monitoring, frequent blood gas analyses, and all basic blood biochemistry parameters were followed twice daily. Neurologic monitoring included repeated monitoring of pupil size and its reactivity to light and periodic recording of the GCS score when possible.

Decompressions were performed using wide Fronto-Temporo-Parietal skin flap. The burr holes were connected using an electrical drill, with subsequent removal of a $12 \text{ cm} \times 15 \text{ cm}$ free bone flap on affected side. The dura was usually opened with a stellate incision in the areas involving the frontal, temporal and parietal lobes extensively. Cortical resection was not performed in any patients. After duraplasty using galea graft, the temporal muscle was loosely re-approximated to the healthy dura and the skin flap was then

closed in two layers. The bone flap was usually re-implanted within 6–12 weeks after craniectomy.

Results

Totally, 53 patients who underwent decompressive craniectomy for malignant MCA infarct between January 2012 and May 2014 were included in the study. Patients aged between 22 and 80 years (mean age was 54.92 ± 11.8 years) were included in this study. The study group consisted of 35 males (66%) and 18 females (34%). The majority of patients were aged below 60 years (32 patients) while 21 patients were aged above 60 years [Table 1]. 32 patients (60.4%) had right sided stroke while 21 patients had left-sided stroke.

A total of 27 patients out of 53 (approximately 51%) had a history of preexisting diabetes while hypertension was found in as many as approximately 95% of the patients (50 out of 53). 34% patients also had a preexisting history of coronary artery disease. 1 patient had preoperative chronic renal failure. Mean GCS score at the presentation of all patients was 10.48 ± 2.4 while mean GCS at surgery was 6.56 ± 1.3 .

A total of 51 patients out of 53 had mRS of 5 at surgery while two patients had mRS of 6 at surgery. 25 patients were operated within 48 h while 28 patients were operated 48 h after onset of stroke. Out of those operated after 48 h majority (16 patients) were operated within 48–96 h of stroke [Figure 1]. Approximately, 74% patients operated within 48 h had mRS 0–3 at discharge while only 56% patients operated after 48 h had mRS 0–3 at discharge. But this difference was not statistically significant.

Table 1: Age distribution

Age group (years)	Number of patients
21-30	1
31-40	4
41-50	12
51-60	15
61-70	17
71-80	4

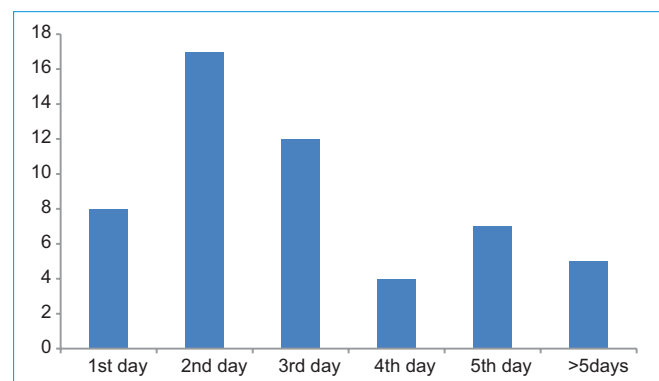


Figure 1: Time interval between surgery and day of stroke

About 78% patients aged below 60 years had mRS 0–3 at discharge while only 38% patients aged above 60 years had mRS 0–3 at discharge which was statistically significant ($P < 0.008$). Mean mRS at discharge was 3.33. Mean ventilatory days were 5.3; while patients under age of 60 years were on ventilator for mean of 4.4 days, patients aged more than 60 years were on ventilator for mean of 6.7 days, but this was not statistically significant.

Totally, 11 out of 32 patients (34.4%) aged below 60 years had one or more of the following complications (sepsis/bedsore/ventilator acquired pneumonia/deep vein thrombosis) while 8 out of 21 patients (38%) aged above 60 years had one or more of the above-mentioned complications but again the difference was not found to be statistically significant. There was no cerebrospinal fluid leakage, intracranial and/or wound infection in any patient.

A total of 2 patients (3.8%) died during hospital course in postoperative. Both patients were aged below 60 years and had GCS of 5 at the time of surgery. Both patients had developed ventilator acquired pneumonia during a hospital stay. 8 patients (15.1%) were discharged against medical advice due to the unwillingness of the family members to continue treatment due to social and economic constraints.

Preexisting factors that are also predictors of poor survival (diabetes mellitus, hypertension, atrial fibrillation, coronary artery disease) did not significantly influence mortality rates or functional outcomes in our study. We assume that this was caused by the relatively small number of patients ($n = 53$) in our study.

Discussion

Malignant MCA infarction refers to life-threatening cerebral edema due to ischemic lesion volume $> 150 \text{ cm}^3$ or $> 50\%$ MCA territory infarction. Malignant MCA infarcts accounts for 10% of supratentorial strokes and clinical worsening occurs in first 24–48 h. Malignant MCA infarction is so-called because of the secondary swelling that occurs in many young patients, and the mortality approaches 80%.

There is the limited role of conventional therapies such as mechanical ventilation, osmotherapy, hypothermia, and barbiturate administration in stroke patients developing intracranial hypertension.^[4]

Malignant sylvian stroke is the only class I indication for decompressive craniectomy in people less than 60 old, but there are controversies.^[5] Decompressive craniectomy interrupts the vicious cycle of extensive edema and elevated ICP to prevent further ischemia. Surgical intervention reduces initial elevated ICP value of by 15% and further reduction up to 70% occurs once the dura was opened. A craniectomy

8 cm large would appear large enough, but it gives just 23 ml additional volume. To obtain real decompression, a minimum diameter of 12 cm of Fronto-Temporo-Parietal bone or more gives 86 ml additional volume.

Decompressive craniectomy converts the closed, rigid cranial vault, into an open box which causes a dramatic decrease in ICP with reversal of the clinical and radiological signs of herniation. Early decompressive craniectomy can limit the spread of the infarcted area. The additional volume obtained by decompressive craniectomy is consequently superior to the one obtained by hyperventilation (2 ml/mm of lowering pCo₂) and ventricular tap of 20–30 ml and is without the risk of loop diuretics.

Cerebral blood flow is increased in the decompressed brain within 24 h after decompressive craniectomy. There is increased brain swelling during the 1st week; which is most probably due to loss of resistance in the brain underlying the craniectomy, which would lead to increased transcapillary leakage due to a higher transcapillary hydrostatic pressure gradient.^[6]

Several studies have reported an improved outcome in patients presenting with complete MCA infarction treated by decompressive hemicraniectomy. Studies indicate that during past four decades, the incidence of major disability or vegetative state has remained relatively constant, although there has been a gradual decrease in the mortality rate and an increase in the proportion of patients with good outcome.^[7]

Recently, clinical effectiveness of Decompressive craniectomy in malignant MCA infarction for patients under the age of 50 years was demonstrated by three randomized, controlled trials (decimal, hamlet and destiny), and a pooled analysis of all three studies. Trials demonstrated reduction in mortality rate by 49% at 1-year after stroke undergoing decompressive craniectomy when compared with conservative care at the same time and mortality rate can be reduced to 20% with timely decompressive craniectomy-number needed to treat to prevent one death is only two. And the favorable functional outcome (0–3 in mRS) increased by 22% due to surgery (43% in the craniectomy group, 21% in the conservative care group).^[8] In our study, 66% patients had the favorable outcome (mRS 0–3) at discharge which is much higher than reported in previous studies.

There are little data regarding the efficacy of surgery outside 48 h or in older patients. Approximately, 74% patients operated within 48 h had good recovery (mRS 0–3) at discharge while 56% patients operated after 48 h had mRS 0–3 at discharge. But this was not statistically significant. In contrast to previous studies, patients operated outside 48 h also fared well though number of patients with good recovery was not as good as operated within 48 h.

About 78% patients aged below 60 years had good recovery (mRS 0–3) at discharge while only 38% patients aged above 60 years had good recovery (mRS 0–3) at discharge which was statistically significant ($P < 0.008$). This is in concordance with previous studies which have also reported the poor neurological outcome in patients aged more than 60 years. 73% patients with right-sided stroke had good recovery (mRS 0–3) at discharge while 52% patients with left-sided stroke had good recovery (mRS 0–3) at discharge but difference was not significant statistically. Of two deaths, one patient had left sided stroke, and other had right-sided stroke.

Two patients died during hospital stay, but we propose factors other than age like co-existing morbidity may play a role in mortality as both patients were aged <60 years. Both patients had preexisting diabetes and hypertension while one of them had a history of coronary artery disease as well. Patients aged more than 60 years took more time to wean off the ventilator but the difference was not significant statistically. Eight patients were discharged against medical advice due to social and financial constraints but there was no statistically significant difference in terms of age, time to surgery since onset of stroke, co-morbidities and preoperative and postoperative neurological status as compared to rest of the group.

The risk of fatal complications such as intracranial infections and contralateral intracerebral hematoma exist but rarely take place. Other complications (such as subdural effusion-hygroma, posttraumatic hydrocephalus, epilepsy) can adversely affect the patient's outcome.^[9] None of our patient had a complication directly related to surgery. Complications during hospital stay like sepsis, bedsore, ventilator acquired pneumonia, and deep vein thrombosis were more common in patients aged more than 60 years but was not significant statistically.

In decompressive craniectomy, there for few key questions which always hammer treating neurologist and neurosurgeon while considering patients who need this life-saving procedure that whether decompressive craniectomy really saves life and improves neurological outcome. Decompressive craniectomy no doubt reduces mortality and increases the proportion of patient with good recovery but also there is a subset of patients who survive but lead bedridden life.

Conclusion

Questions regarding quality-of-life and eventual neurological outcome hammer treating neurologist and neurosurgeon while considering patients of malignant MCA infarction for surgery. Decompressive craniectomy has reduced morbidity and mortality especially in people aged below 60 years and those operated within 48 h of malignant MCA stroke though those operated outside 48 h of stroke also fare well neurologically, there is no reason these patients should be denied surgery. While discussing decompressive craniectomy, patients and families should be approached with extreme honesty, objectivity, and humility while every effort is made not to influence their decision.

References

1. Hempenstall J, Sadek AR, Eynon CA. Decompressive craniectomy in acute brain injury – Lifting the lid on neurosurgical practice. *J Intensive Care Soc* 2012;13:221-6.
2. Balan C, Alliez B. Decompressive craniectomy – From option to standard – Part I. *Rom Neurosurg* 2009;16:20-6.
3. Valença MM, Martins C, Silva JC, Mendonça CM, Ambrosi PB, Andrade-Valença LP. An innovative technique of decompressive craniectomy for acute ischemic stroke. In: Balestrino M, editor. *Advances in the Treatment of Ischemic Stroke*. Intech; 2012. Available from: <http://www.intechopen.com/books/advances-in-the-treatment-of-ischemic-stroke/decompressive-craniectomy-for-cerebral-ischemia>. [Last cited on 2015 Jan 10].
4. Fandino J, Keller E, Barth A, Landolt H, Yonekawa Y, Seiler RW. Decompressive craniotomy after middle cerebral artery infarction. Retrospective analysis of patients treated in three centres in Switzerland. *Swiss Med Wkly* 2004;134:423-9.
5. Balan C, Alliez B. Decompressive craniectomy – From option to standard – Part II. *Rom Neurosurg* 2010;17:73-80.
6. Olivecrona M, Rodling-Wahlström M, Naredi S, Koskinen LO. Effective ICP reduction by decompressive craniectomy in patients with severe traumatic brain injury treated by an ICP-targeted therapy. *J Neurotrauma* 2007;24:927-35.
7. Syed AB, Ahmad IH, Hussain M, Al-Bya F, Solaiman A. Outcome following decompressive craniectomy in severe head injury: Rashid Hospital experience. *Pan Arab J Neurosurg* 2009;1:29-35.
8. Yu JW, Choi JH, Kim DH, Cha JK, Huh JT. Outcome following decompressive craniectomy for malignant middle cerebral artery infarction in patients older than 70 years old. *J Cerebrovasc Endovasc Neurosurg* 2012;14:65-74.
9. Bakar B, Sumer MM, Tekkok IH. Decompressive craniectomy for intractable intracranial hypertension. *J Clin Anal Med* 2012;3:383-7.

How to cite this article: Bansal H, Chaudhary A, Singh A, Paul B, Garg R. Decompressive craniectomy in malignant middle cerebral artery infarct: An institutional experience. *Asian J Neurosurg* 2015;10:203-6.

Source of Support: Nil, **Conflict of Interest:** None declared.