

ORIGINAL ARTICLE

Analysis of 1014 consecutive operative cases to determine the utility of intraoperative neurophysiological data

Namath Syed Hussain

Department of Neurosurgery, Penn State Milton S. Hershey Medical Center, Hershey, Pennsylvania, USA

ABSTRACT

Introduction: Intraoperative neurophysiological monitoring (IOM) during neurosurgical procedures has become the standard of care at tertiary care medical centers. While prospective data regarding the clinical utility of IOM are conspicuously lacking, retrospective analyses continue to provide useful information regarding surgeon responses to reported waveform changes.

Methods: Data regarding clinical presentation, operative course, IOM, and postoperative neurological examination were compiled from a database of 1014 cranial and spinal surgical cases at a tertiary care medical center from 2005 to 2011. IOM modalities utilized included somatosensory evoked potentials, transcranial motor evoked potentials, pedicle screw stimulation, and electromyography. Surgeon responses to changes in IOM waveforms were recorded.

Results: Changes in IOM waveforms indicating potential injury were present in 87 of 1014 cases (8.6%). In 23 of the 87 cases (26.4%), the surgeon responded by repositioning the patient ($n = 12$), repositioning retractors ($n = 1$) or implanted instrumentation ($n = 9$), or by stopping surgery ($n = 1$). Loss of IOM waveforms predicted postoperative neurological deficit in 10 cases (11.5% of cases with IOM changes).

Conclusions: In the largest IOM series to date, we report that the surgeon responded by appropriate interventions in over 25% of cases during which there were IOM indicators of potential harm to neural structures. Prospective studies remain to be undertaken to adequately evaluate the utility of IOM in changing surgeon behavior. Our data is in agreement with previous observations in indicating a trend that supports the continued use of IOM.

Key words: Intraoperative monitoring, postoperative deficits, quality, surgical planning, waveform changes

Introduction

Intraoperative neurophysiological monitoring (IOM) during neurosurgical procedures has become the standard of care at tertiary care medical centers.^[1-6] As studies have been published with regard to its utility and while it has been adopted as an almost universal adjunct to the neurosurgeon's operative equipment, there has not been any report in the literature

describing detailed surgical experience with IOM, correlating monitoring changes with surgeon responses and actions in the operating room and patient postoperative neurological deficits.

Spinal and cranial decompression procedures are among the most common procedures in most clinical practices; however, in the recent years, due to surgeon-industry collaborations, more advanced equipment for surgical reconstruction has increased the utilization of permanently implanted hardware.^[1,6-12,13] This practice pattern introduces risks to the patient and must be done in the safest manner possible. The appropriate neuromonitoring adjuncts must be utilized when needed to improve safety.^[2,4,5,14-18] Even though the IOM technologist and the consulting neurologist reading the waveform changes appear to be the ones most knowledgeable with the respect to the IOM technology and machinery, it is critical for the surgeon to be up-to-date regarding the technology as they are the ones most directly making intraoperative decisions based on these IOM waveform changes that can permanently affect patients. Only the surgeon is perfectly privy and poised to make the most

Access this article online

Quick Response Code:



Website:

www.asianjns.org

DOI:

10.4103/1793-5482.161197

Address for correspondence:

Dr. Namath S. Hussain, Department of Neurosurgery, Penn State Milton S. Hershey Medical Center, 30 Hope Drive, EC110, Hershey, Pennsylvania 17033, USA. E-mail: namath.hussain@gmail.com

adequate decision with respect to continuing with surgery, changing the operative plan, or aborting.^[19]

While most surgeons are aware of these IOM tools and their medicolegal fallout and implications, many do not have a clear understanding of what actions to take in the event of a monitoring change and how likely these changes will signal a postoperative deficit since no clinical study has been conducted to examine these waveform changes in a rigorous manner. Our hypothesis was that IOM waveform changes do predict neurological deficit and that surgeon actions in response to these alerts can help to reduce postoperative deficits. Our study aims to describe our surgical experience over a 7 year period including intraoperative monitoring alerts along with surgeon responses to these alerts coupled with any changes in the patient's clinical exam postoperatively.

Methods

Data regarding patient clinical presentation and neurological examination, operative course, IOM modalities used, IOM waveform baseline abnormalities and changes, alerts given to the surgeon by the technologist, surgeon responses to these alerts, surgeon actions in response to these alerts, and the postoperative patient neurological examination were compiled from a database of 1014 cranial and spinal surgical cases at a single institution from 2005 to 2011. IOM modalities utilized included somatosensory evoked potentials (SSEPs), transcranial motor evoked potentials (MEPs), dermatomal evoked potentials (DEPs), visual evoked responses (VERs), pedicle screw stimulation, and electromyography (EMG) [Figures 1-6]. The data were acquired, displayed in real time, and stored digitally using Cascade® software on a customized desktop personal computer. Surgeon responses to changes in IOM waveforms were recorded by the monitoring technologist and maintained in our clinical database in a prospective fashion.

Waveform evaluation included a quantitative and qualitative analysis of variability, morphology, latency, and amplitude of waveforms and their relationship to the anesthetic regimen, specifically the minimum alveolar concentration (MAC) of volatile inhalant agent along with the stage of surgery and any reported surgeon actions. In evaluating SSEP waveforms, a decrease in amplitude of 50% or increase in latency of 10% was considered to be indicative of a significant change that may indicate damage to neural structures. In our assessment of MEPs, DEPs, and VERs, we reported a change as a decrease in amplitude of 80%. Intraoperative EMG consists of spontaneous EMG obtained by placing electrodes directly in muscles and triggered EMG or pedicle screw stimulation. Spikes, bursts, and trains of EMG activity were recorded, with trains being of highest concern for nerve injury. A Spearman's rank correlation coefficient was calculated for each modality, as we are comparing nonparametric data (presence or lack of deficits being binary data). Using several descriptive cases, we illustrate how intraoperative monitoring can be utilized to the neurosurgeon's advantage to decrease patient and surgery-related morbidity.

In terms of anesthetic management, the volatile agent in approximately two-thirds of the cases was sevoflurane. In most of the remaining cases desflurane was utilized and in a very few cases isoflurane was used. MAC values used for desflurane, sevoflurane, and isoflurane were 6.5, 2.2, and 1.1% respectively. The status of neuromuscular blocking was monitored by repetitive train-of-four stimulation of the ulnar nerve with recording from the first dorsal interosseus muscle. Narcotics were generally administered as a continuous infusion, although occasionally as a bolus. Sufentanil was the agent most commonly used, followed by fentanyl. In several cases, a total intravenous anesthetic protocol was used, consisting of propofol and sufentanil infusions. In most cases, the propofol infusion was 100 µg/kg/min.

Statistical analysis was performed with StatTools add-in statistical package for Microsoft Excel 2003. $P < 0.05$ was

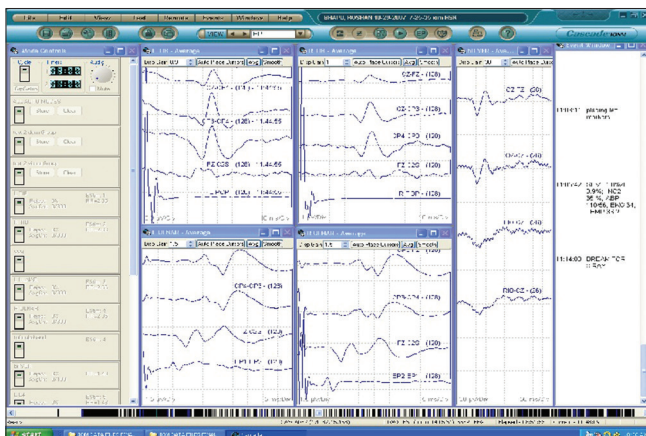


Figure 1: Intraoperative neurophysiological monitoring waveforms monitored including somatosensory evoked potentials and motor evoked potentials

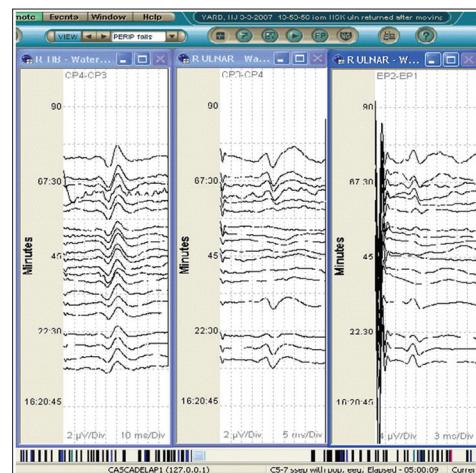


Figure 2: Ulnar nerve waveform loss with central line placement

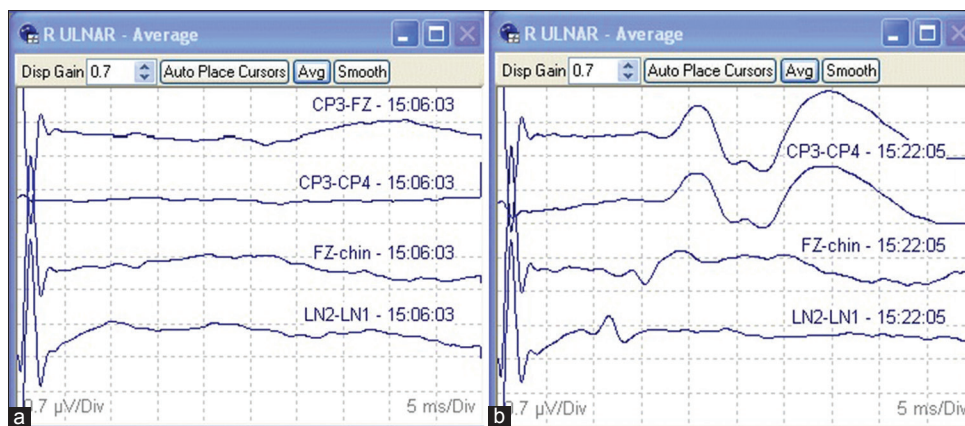


Figure 3: (a and b) Ulnar nerve waveform loss with axillary retractor placement and waveform return with retractor removal

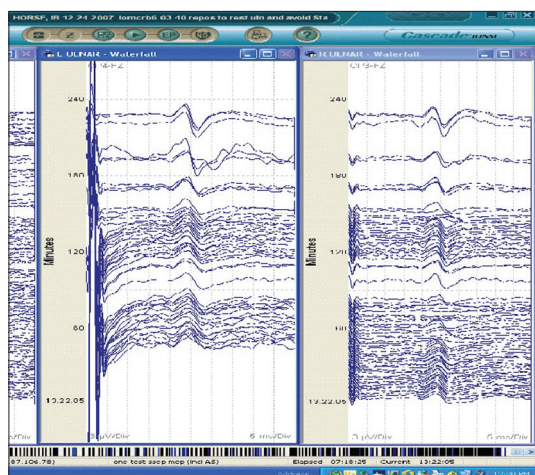


Figure 4: Ulnar nerve waveform loss during posterior cervical decompression

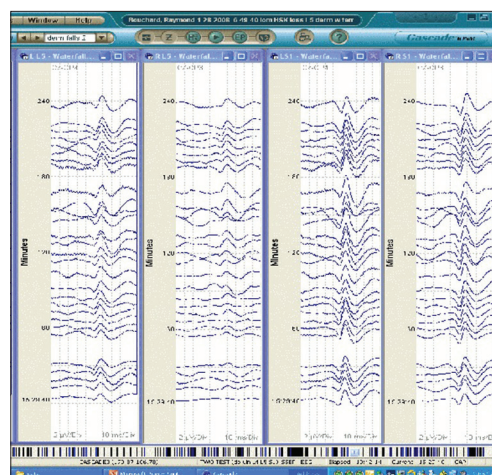


Figure 5: L5 nerve changes during vertebral body cage implantation

used to determine the significance. Spearman rank correlation coefficient was used to calculate correlations.

Results

There were no anesthesia-related intraoperative complications. The most common procedures performed were posterior lumbar fusion ($n = 413$), anterior cervical disectomy and fusion ($n = 135$), posterior cervical fusion ($n = 131$), and posterior thoracic fusion ($n = 111$). Quantitatively recorded changes in IOM waveforms indicating potential injury were present in 87 of 1014 cases (8.6%). The relationship between the degree of amplitude loss or latency increase and presence of postoperative deficits was not significant ($r = 0.045$, $P = 0.15$). No one modality predicted postoperative deficits better than another. Representative screenshots from the Cascade® software platform of waveform changes are shown in Figures 2-6. Examples that involved waveform changes that normalized after repositioning are shown. In 23 of the 87 cases (26.4%), the surgeon responded [Table 1] by repositioning the patient ($n = 12$), repositioning retractors ($n = 1$) or implanted instrumentation ($n = 9$), or by stopping surgery ($n = 1$) [Table 2]. In all cases where the

surgeon repositioned retractors or the patient, there were no sustained postoperative deficits. Four patients sustained deficits despite surgeon action [Table 1]. Loss of IOM waveforms predicted postoperative neurological deficit in 10 cases (11.5% of cases with IOM changes). Thus, in 11.5% of cases where IOM changes were present, the patient sustained a postoperative new neurological deficit. There was only one instance of a postoperative deficit when there were no IOM alerts noted. We did not have any instance of permanent deficits when repositioning retractors ($n = 1$), or implanted instrumentation ($n = 9$), or by stopping surgery ($n = 1$). An example that involved waveform changes that normalized after repositioning is shown [Figure 3].

Cases

Case presentation 1: Normal IOM waveforms [Figure 1].

Case presentation 2: Ulnar nerve waveform loss with placement of central line [Figure 2].

Case presentation 3: Ulnar nerve waveform loss with placement of axillary retractor and regain of waveform with retractor repositioning [Figures 3a, 3b].

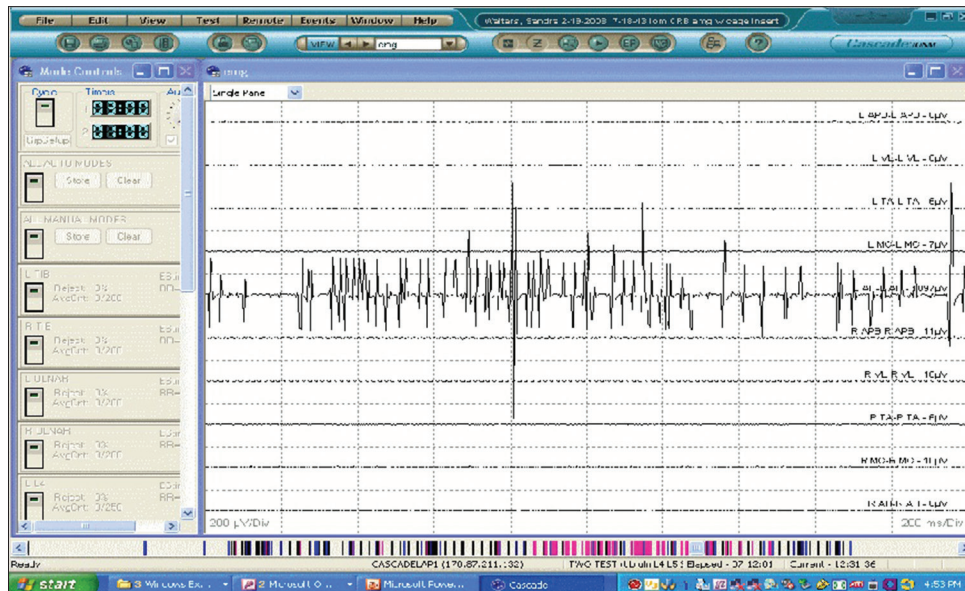


Figure 6: Electromyography changes during L5-S1 interbody graft placement

Table 1: 2x2 table showing breakdown of new deficits and surgeon responses in the subset of 87 cases with waveform changes

	Deficit	No deficit	Total
Surgeon response	4	19	23
No surgeon response	6	58	64
Total	10	77	87

Case presentation 4: Ulnar nerve waveform loss during posterior cervical decompression [Figure 4].

Case presentation 5: Waveform changes with L5 cage placement [Figure 5].

Case presentation 6: Free-run EMG changes noted during L5-S1 instrumentation [Figure 6].

Discussion

Minimally-invasive neurosurgical techniques have provided newer approaches that have led to better outcomes and are the preferred method for both cranial and spinal surgery over the past decade.^[20,21] Several studies have borne out the utility of IOM by looking at waveform changes and whether patients suffer from deficits postoperatively.^[2,3,18,22-27,34]

Somatosensory evoked potentials monitor the dorsal column-medial lemniscus pathway by recording specifically from the median and ulnar nerves in the upper extremities and the posterior tibial nerve and peroneal nerves in the lower extremities. A decrease in amplitude of 50% or increase in latency of 10% is considered to be indicative of a significant change that may indicate damage to neural structures.^[28,29,30] MEPs provide monitoring of the corticospinal tract. In the

past, a clinical examination was required to attain this type of information, and an intraoperative wake-up test was often utilized. There are two usual methods of recording MEPs. They can be obtained transcranially as we did or via D-wave monitoring directly at the spinal cord level. MEPs vary in their interpretation. Some studies have used an all-or-nothing amplitude threshold while others have employed specific morphology criteria.^[31]

Our study provides convincing evidence of that utility of IOM. Changes in IOM waveforms indicating potential injury occurred in 8.6% of cases in our large series. A unique aspect of our study is that we recorded surgeon responses to IOM waveform changes. In 23 of the 87 cases (26.4%), the surgeon responded with some change in the intraoperative plan [Table 1], meaning they took some action in response to the waveform changes. Loss of IOM waveforms predicted postoperative neurological deficit in 10 cases (11.5% of cases with IOM changes), making this a useful adjunct in neurosurgical procedures.

Raynor *et al.* have reported on the largest IOM data series to date examining 12,375 spinal surgical procedures.^[16] They identified 386 (3.1%) patients with loss/degradation of IOM waveforms. On examination of surgeon actions and their sequelae, they found that in 93.3% of patients with waveform changes, intervention by the surgeon based on this IOM information led to waveform recovery and no neurological deficits after surgery. Reduction from a potential (worst-case scenario) 3.1% (386) of patients with significant change in IOM waveforms to a permanent postoperative neurological deficit rate of 0.12% (15) patients was achieved ($P < 0.0001$), thus confirming utility of IOM. These results are in line with ours except for their very small deficit rate that may be a result of how they defined deficit, which was not explained in their

Table 2: Waveform changes noted during the study

Decreased voltage from all channels on left
 Loss of amplitude of left tibial with insertion of template, loss of EMG left gastroc
 Reduction of right ulnar amplitude with positioning, corrected
 Marked decreased amplitude of corticals with bleeding
 Loss of right ulnar all responses
 Good example of selective influence of gas and blood pressure on potentials
 Replaced screw in the same location, increased threshold
 Low threshold, screws repositioned
 Active EMG irritation right tibial/gastroc
 Latency increase in SSEPs
 Irritative EMG potentials
 Same side EMG signal with template insertion
 Good H-reflexes, good VERs, persistent EMG right gastroc
 Brief loss VERs with brief hypertension, otherwise good VERs, absent H-reflexes
 EMG signal with tapping in of cage
 Excellent SSEPs, brief run EMG after cage insertion
 Low thresholds, extremely small pedicles
 Nice marker stim, some low thresholds
 Activation with L1 screw stim, question of false positive with L2 screw stim
 Lost left tibial SSEP, some gastroc EMG signal
 Loss of ulnars, returned after repositioning
 Right tibial SSEP deterioration with R cage insertion
 Good flash VERs, periods of hypo and hypertension with changes
 Erb's point changes, fixed with repositioning, good motors from all dermatomes
 Excellent fast VERs, ulnar rebound after positioning change
 Lost H-reflex during biopsy of the tumor in cauda equina
 Lost ulnars with head turning during placement of central line
 EMG quiet, lost right H-reflex
 Lost SSEP, then MEP
 Lost left H-reflex and tibial SSEP, SSEP rebounded
 Lost right ulnar, returned after repositioning of retractor
 Remarkably sensitive right ulnar to positioning, lost left tibial response
 H-reflex on R appeared after decompression
 Marked improvement right ulnar after repositioning arm, very poor DERMs
 H-reflex returned after decompression, SSEPs poor to absent
 Extremely active EMG
 Lost H-reflex during manipulation
 Lost L5 DERMs after cage insertion
 Lost MEPs tibial/gastroc
 Lost L5 after cage placement, gradually returned
 Excellent DERMs, L4 lost amplitude with rod placement
 Loss of L DERMs and L tibial on 2 occasions
 Good example of brief EMG trains
 Good C6–7 DERMs, absent C5, loss of ulnar returned
 Lost R L5 after template inserted, all 3 DERMs show longer latency
 Lost SSEPs, hypotension due to excess bleeding
 DERMs lost after cage trials
 MEP loss during cage placement
 Lost right tibial/gastroc
 Lost ulnar with arm positioning, restored with repositioning
 Excellent motor, decreased SSEP with conus entry
 Decreased MEPs, good responses to stim

contd...

Table 2: Contd...

Ulnar nerve briefly lost and solved with repositioning
 Good DERMs, but marked decrease of L L4
 Marked changes SSEPs intraoperatively, some MEP change
 Lost left tibial SSEP
 Lost L4 briefly with insertion of L4–5 template and permanent cage
 Deterioration of MEPs
 EMG R biceps and deltoid during procedure
 Median lost, corrected with repositioning arm
 Lost right tibial after opening cord
 L gastroc EMG
 SSEP waveform decrease
 Low threshold screw, better after second repositioning
 Lost R tibial
 Lost tibial after opening cord
 Lost L5 DERMs
 Temporary loss of R C6 and C7 DERMs
 VERs changed with gas and surgery
 Changes on opposite side after clipping, recovered
 Good BAERs, good CN V and CN VII responses, facial EMG active
 Lost left tibial with mayfield positioning, returned after repositioning
 Deterioration of MEPs
 Rectus abdominis bursts during instrumentation placement
 Reduction right ulnar amplitude with positioning, corrected
 Low threshold, screws repositioned
 Replaced screw, increased threshold
 Left ulnar lost, MEPs depressed on left except most proximal muscles
 EMG signal with template insertion
 Erb's point changes fixed with repositioning
 L tibial/gastroc SSEP/MEP response declined in amplitude
 H-reflex on R appeared after decompression
 H-reflex returned after decompression, SSEPs poor
 Lost H-reflex during manipulation
 Lost MEPs tibial/gastroc
 Lost MEPs ulnar/median, EMG signal
 Lost L4 briefly with insertion of template and permanent cage

EMG – Electromyography; SSEPs – Somatosensory evoked potentials; VERs – Visual evoked responses; MEP – Motor evoked potential

methods. Our definition was any change in motor power on the traditional 5 point scale.

In a very large study with similar patient numbers (1121 patients) as ours, Schwartz *et al.* found that 38 (3.4%) of patients had waveform changes.^[32] Of those 38 patients, 17 showed MEP loss of over 65% without SSEP changes. In nine of the 38 patients, the signal change was related to hypotension and was corrected intraoperatively. In the remaining 29 patients, waveform loss was directly temporally related to a surgical maneuver. Three alerts occurred following segmental vessel clamping, and the remaining 26 alerts were related to instrumentation implantation and deformity correction. In total 9 (35%) of these 26 patients with an instrumentation-related alert, or 0.8% of the total cohort, awoke from surgery with a transient motor and/or sensory deficit with seven having motor and two having sensory deficits. SSEPs failed to identify a motor deficit

in four of the seven patients with a confirmed motor deficit. An additional finding of the study was that changes in SSEPs lagged behind changes in MEPs by an average of 5 min. With an appropriate response to the alert, the deficits in all nine patients resolved within 3 months.

Hilibrand *et al.* reported on another large cohort of 427 patients, 12 of whom demonstrated substantial or complete loss of amplitude of MEPs.^[33] Ten of the 12 patients had complete resolution of the waveform loss with the surgeon intraoperative intervention, whereas the remaining two awoke with a new motor deficit. SSEP changes lagged behind MEP changes by half an hour. According to their data, MEPs were 100% sensitive and 100% specific, whereas SSEPs were 25% sensitive and 100% specific. They found that transient sensory deficits when they do occur most likely represent mild neuropraxia that usually resolve, which agrees with the findings in our operative database.

The literature contains several studies documenting the utility of IOM, but there has been no previous study that documents both surgeon responses and deficits postoperatively such as ours. We hope that this finding may convince more surgeons that IOM has utility, and that waveform changes should not be overlooked when IOM is used. These findings also provide rigorous documentation with no patients lost to follow-up that may provide the basis for further research endeavors that may explore other aspects of how monitoring changes, surgeon responses, and patient deficits interplay with one another. More study is needed to obtain more quantitative data in terms of how long monitoring changes occurred before surgeons took action and what degree of monitoring changes were most likely or sufficient induce surgeon response or result in a new postoperative deficit.

Conclusions

Intraoperative neurophysiological monitoring is an effective adjunct to the neurosurgeon's armamentarium that may be particularly helpful when confronted with pathology near eloquent neural tissue. With improved IOM platforms, new minimally-invasive surgical techniques can help treat patients while improving the safety profile of our treatment options. In the largest comprehensive clinical IOM series to date that includes patients' preoperative and postoperative exam, IOM alerts, and surgeon actions, we report that the surgeon responded by appropriate interventions in over 25% of cases during which there were IOM indicators of potential harm to nearby critical neural structures. Further prospective studies remain to be undertaken to adequately evaluate the utility of IOM in modifying and changing surgeon behavior. Further refinements in surgical technique can be recommended with this type of intraoperative data. Ultimately, patient safety and satisfaction will drive adoption of these data sets into clinical practice utilization and oversight. Our data are in agreement

with previous studies indicating a trend that supports the continued use of IOM.

References

1. Calancie B, Harris W, Broton JG, Alexeeva N, Green BA. "Threshold-level" multipulse transcranial electrical stimulation of motor cortex for intraoperative monitoring of spinal motor tracts: Description of method and comparison to somatosensory evoked potential monitoring. *J Neurosurg* 1998;88:457-70.
2. Cho KJ, Suk SI, Park SR, Kim JH, Kim SS, Choi WK, *et al.* Complications in posterior fusion and instrumentation for degenerative lumbar scoliosis. *Spine (Phila Pa 1976)* 2007;32:2232-7.
3. Chung I, Glow JA, Dimopoulos V, Walid MS, Smisson HF, Johnston KW, *et al.* Upper-limb somatosensory evoked potential monitoring in lumbosacral spine surgery: A prognostic marker for position-related ulnar nerve injury. *Spine J* 2009;9:287-95.
4. Dekutoski MB, Norvell DC, Dettori JR, Fehlings MG, Chapman JR. Surgeon perceptions and reported complications in spine surgery. *Spine (Phila Pa 1976)* 2010;35:S9-21.
5. Deletis V, Sala F. Intraoperative neurophysiological monitoring of the spinal cord during spinal cord and spine surgery: A review focus on the corticospinal tracts. *Clin Neurophysiol* 2008;119:248-64.
6. Eggspuehler A, Sutter MA, Grob D, Jeszenszky D, Porchet F, Dvorak J. Multimodal intraoperative monitoring (MIOM) during cervical spine surgical procedures in 246 patients. *Eur Spine J* 2007;16 Suppl 2:S209-15.
7. Fan D, Schwartz DM, Vaccaro AR, Hilibrand AS, Albert TJ. Intraoperative neurophysiologic detection of iatrogenic C5 nerve root injury during laminectomy for cervical compression myelopathy. *Spine (Phila Pa 1976)* 2002;27:2499-502.
8. Fehlings MG, Brodke DS, Norvell DC, Dettori JR. The evidence for intraoperative neurophysiological monitoring in spine surgery: Does it make a difference? *Spine (Phila Pa 1976)* 2010;35:S37-46.
9. Guérit JM, Verhelst R, Rubay J, Khoury G, Matta A, Dion R. Multilevel somatosensory evoked potentials (SEPs) for spinal cord monitoring in descending thoracic and thoraco-abdominal aortic surgery. *Eur J Cardiothorac Surg* 1996;10:93-103.
10. Guérit JM, Witdoeck C, Verhelst R, Matta AJ, Jacquet LM, Dion RA. Sensitivity, specificity, and surgical impact of somatosensory evoked potentials in descending aorta surgery. *Ann Thorac Surg* 1999;67:1943-6.
11. Hilibrand AS, Schwartz DM, Sethuraman V, Vaccaro AR, Albert TJ. Comparison of transcranial electric motor and somatosensory evoked potential monitoring during cervical spine surgery. *J Bone Joint Surg Am* 2004;86-A: 1248-53.
12. Hussain NS, Perez-Cruet MJ. Complication management with minimally invasive spine procedures. *Neurosurg Focus* 2011;31:E2.
13. Isaacs RE, Hyde J, Goodrich JA, Rodgers WB, Phillips FM. A prospective, nonrandomized, multicenter evaluation of extreme lateral interbody fusion for the treatment of adult degenerative scoliosis: Perioperative outcomes and complications. *Spine (Phila Pa 1976)* 2010;35:S322-30.
14. Ito Z, Matsuyama Y, Shinomiya K, Ando M, Kawabata S, Kanchiku T, *et al.* Usefulness of multi-channels in intraoperative spinal cord monitoring: Multi-center study by the Monitoring Committee of the Japanese Society for Spine Surgery and related research. *Eur Spine J* 2013;22:1891-6.
15. Jarvis JG, Strantzas S, Lipkus M, Holmes LM, Dear T, Magana S, *et al.* Responding to neuromonitoring changes in 3-column posterior spinal osteotomies for rigid pediatric spinal deformities. *Spine (Phila Pa 1976)* 2013;38:E493-503.
16. Jellish WS, Sherazee G, Patel J, Cunanan R, Steele J, Garibashvilli K, *et al.* Somatosensory evoked potentials help prevent positioning-related brachial plexus injury during skull base surgery. *Otolaryngol Head Neck Surg* 2013;149:168-73.
17. Lorenzini NA, Poterack KA. Somatosensory evoked potentials are not a sensitive indicator of potential positioning injury in the prone patient. *J Clin Monit* 1996;12:171-6.

18. Luk KD, Hu Y, Wong YW, Cheung KM. Evaluation of various evoked potential techniques for spinal cord monitoring during scoliosis surgery. *Spine (Phila Pa 1976)* 2001;26:1772-7.
19. Mardjetko SM, Connolly PJ, Shott S. Degenerative lumbar spondylolisthesis. A meta-analysis of literature 1970-1993. *Spine (Phila Pa 1976)* 1994;19 20 Suppl: 2256S-65.
20. McAfee PC, Phillips FM, Andersson G, Buvenenadran A, Kim CW, Laurysen C, *et al.* Minimally invasive spine surgery. *Spine (Phila Pa 1976)* 2010;35:S271-3.
21. Novak K, Widhalm G, de Camargo AB, Perin N, Jallo G, Knosp E, *et al.* The value of intraoperative motor evoked potential monitoring during surgical intervention for thoracic idiopathic spinal cord herniation. *J Neurosurg Spine* 2012;16:114-26.
22. Pastorelli F, Di Silvestre M, Plasmati R, Michelucci R, Greggi T, Morigi A, *et al.* The prevention of neural complications in the surgical treatment of scoliosis: The role of the neurophysiological intraoperative monitoring. *Eur Spine J* 2011;20 Suppl 1:S105-14.
23. Raynor BL, Bright JD, Lenke LG, Rahman RK, Bridwell KH, Riew KD, *et al.* Significant change or loss of intraoperative monitoring data: A 25-year experience in 12,375 spinal surgeries. *Spine (Phila Pa 1976)* 2013;38:E101-8.
24. Robertazzi RR, Cunningham JN Jr. Monitoring of somatosensory evoked potentials: A primer on the intraoperative detection of spinal cord ischemia during aortic reconstructive surgery. *Semin Thorac Cardiovasc Surg* 1998;10:11-7.
25. Robertazzi RR, Cunningham JN Jr. Intraoperative adjuncts of spinal cord protection. *Semin Thorac Cardiovasc Surg* 1998;10:29-34.
26. Rodgers WB, Gerber EJ, Patterson J. Intraoperative and early postoperative complications in extreme lateral interbody fusion: An analysis of 600 cases. *Spine (Phila Pa 1976)* 2011;36:26-32.
27. Rousseau MA, Lazennec JY, Bass EC, Saillant G. Predictors of outcomes after posterior decompression and fusion in degenerative spondylolisthesis. *Eur Spine J* 2005;14:55-60.
28. Sala F, Lanteri P, Bricolo A. Motor evoked potential monitoring for spinal cord and brain stem surgery. *Adv Tech Stand Neurosurg* 2004;29:133-69.
29. Schwartz DM, Auerbach JD, Dormans JP, Flynn J, Drummond DS, Bowe JA, *et al.* Neurophysiological detection of impending spinal cord injury during scoliosis surgery. *J Bone Joint Surg Am* 2007;89:2440-9.
30. Seyal M, Mull B. Mechanisms of signal change during intraoperative somatosensory evoked potential monitoring of the spinal cord. *J Clin Neurophysiol* 2002;19:409-15.
31. Stecker MM, Robertshaw J. Factors affecting reliability of interpretations of intra-operative evoked potentials. *J Clin Monit Comput* 2006;20:47-55.
32. Thirumala PD, Kodavatiganti HS, Habeych M, Wichman K, Chang YF, Gardner P, *et al.* Value of multimodality monitoring using brainstem auditory evoked potentials and somatosensory evoked potentials in endoscopic endonasal surgery. *Neurol Res* 2013;35:622-30.
33. Tormenti MJ, Maserati MB, Bonfield CM, Okonkwo DO, Kanter AS. Complications and radiographic correction in adult scoliosis following combined transpoas extreme lateral interbody fusion and posterior pedicle screw instrumentation. *Neurosurg Focus* 2010;28:E7.
34. Tormenti MJ, Maserati MB, Bonfield CM, Gerszten PC, Moosy JJ, Kanter AS, *et al.* Perioperative surgical complications of transforaminal lumbar interbody fusion: A single-center experience. *J Neurosurg Spine* 2012;16:44-50.

How to cite this article: Hussain NS. Analysis of 1014 consecutive operative cases to determine the utility of intraoperative neurophysiological data. *Asian J Neurosurg* 2015;10:166-72.
Source of Support: Nil, **Conflict of Interest:** None declared.