

CASE REPORT

Unspecific clinical manifestation of cauda equina myxopapillary ependymoma

Gayrat Maratovich Kariev, Elbek Shodievich Halikulov¹, Shavkat Orzikuloviich Rasulov¹

Republican Scientific Center of Neurosurgery, ¹Department of Neurosurgery, Tashkent Pediatric Medical Institute, Tashkent, Uzbekistan

ABSTRACT

A 9-year-old boy admitted to the neurosurgical hospital complaining of headache, vomiting, abdominal pain, and weakness in the arms and legs, urinary retention. Previously, the patient had a treatment of pediatricians. He was examined, magnetic resonance imaging revealed the tumor of the conus medullaris and cauda equina. The surgery was performed with removal myxopapillary ependymoma (ME). Postoperative neurological symptoms regressed; he has received radiotherapy postoperatively. This case illustrates a rare clinical presentation of ME, which simulated intracranial, thoracic, and caudal pathology. We presented features of the clinical presentation, diagnostics, and treatment options of this ependymoma.

Key words: Clinical presentation, Laminectomy, myxopapillary ependymoma

Introduction

Myxopapillary ependymoma (ME) is a rare type of tumors of the central nervous system (CNS), which is mainly localized in the cauda equina roots. ME benign neoplasm with a different type of growth and having a propensity to metastases. We presented a rare case of ME caudal localization with clinical manifestation similar to cranial or cervical pathology, delivering possible diagnostic and therapeutic aspects of the disease.

Case Report

A 9-year-old boy was admitted to the hospital with complaints of headache, weakness in the lower extremities, urinary retention, abdominal pain, vomiting, and loss of weight. The onset of illness was 3 months ago with headache and abdominal pain. Laboratory test data were all within the normal ranges. Examining the status of the abdominal cavity and ultrasound revealed no pathology. However, with

the lapse of time, the patient's symptoms continued and the additional neurological deficit appeared. Neurologically observed lower paraparesis muscle strength of 3/3 points, paraparesis of upper extremities 4/4 points, hypesthesia from L1 on conductive type, pain in the legs and nuchal rigidity [Figure 1]. On electromyography, signs of conductive disorders at the level of the thoracic segments of the spinal cord. Visual function without pathology. In a series of magnetic resonance imaging (MRI) images revealed the tumor with solid and cystic components from level T10 to L4 vertebra [Figure 2]. MRI examination of the cervical spine and head did not reveal pathology. A cystic expansion of the central canal revealed at the mild and upper thoracic level of the spinal cord [Figure 3]. The patient underwent decompressive laminectomy where we found tumor and subarachnoid hemorrhage. We have removed the cystic component extracapsular, and part of the solid tumors. Histopathology showed ME [Figure 4]. Urinary retention after surgery regressed, abdominal pain and vomiting resolved. Headache and neurological deficit eventually disappeared. Patient was discharged with a recommendation to radiotherapy.

Discussion

Myxopapillary ependymoma is usually localized in the cauda equina, and filum terminale characterized mucin production and the formation of the node. Despite the benign neoplasms, in practice, there have been cases of dissemination and metastasis through the cerebrospinal axis.^[1,2] The tumor has no different specificity of clinical signs from the syndrome of degenerative diseases of the spinal cord. Despite the fact that the main symptom of tumors of the conus medullaris and cauda equina is a pain,^[3] in our opinion neurological deficit

Access this article online	
Quick Response Code:	Website: www.asianjns.org
	DOI: 10.4103/1793-5482.161198

Address for correspondence:

Dr. Halikulov Elbek Shodievich, Department of Neurosurgery, Tashkent Pediatric Medical Institute, Bagishamal Street 223, Yunusabad Region, 100140 Tashkent City, Uzbekistan.
E-mail: elkhal@rambler.ru

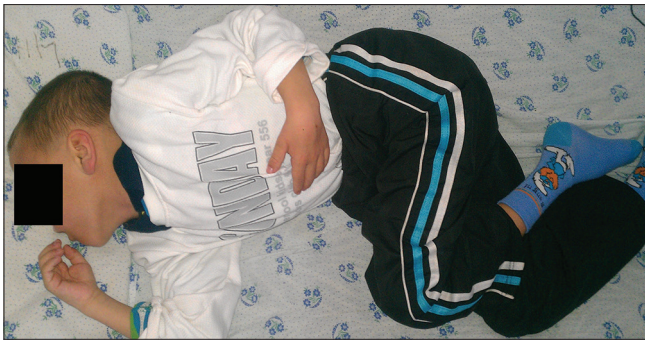

Figure 1: A patient presented with nuchal rigidity

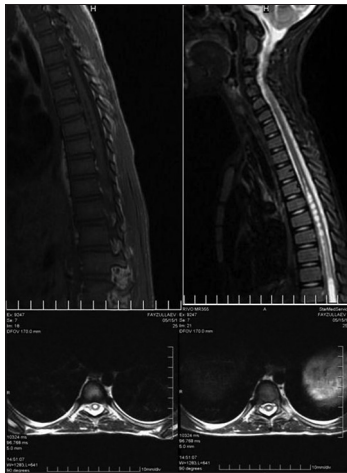

Figure 3: Magnetic resonance imaging reveals cystic expansion of central canal of spinal cord at the thoracic level

has a greater informative value. The combination of the back pain syndrome and cauda equina may indicate surgically significant pathology.^[4]

Note that the ME may complicate spinal subarachnoid hemorrhage.^[5] According to some authors, headaches accompanied by severe pain in the lower back can be assumed as a subarachnoid hemorrhage in a patient with a tumor of the spinal cord.^[6]

In our case, the headache was accompanied not only concomitant low back pain, but the pain in the legs, abdominal pain, and vomiting. Presented nature of pain can manifest itself not only in the subarachnoid hemorrhage, but also in associated intracranial pathology. Thus, the literature describes cases of combination tumor cauda equina with a brain tumor,^[7] as well as hydrocephalus,^[8,9] manifested by headaches. In the presence of the ME, filum terminale and the brain cannot be excluded retrograde dissemination of tumor cells in the cranial direction.^[10] In our case nuchal rigidity, headache and brain MRI indicated subarachnoid hemorrhage. In rare cases, the only sign of a tumor of the thoracic spinal cord is a pain in the abdomen.^[11] In the present case, abdominal pain differed by the presence of vomiting.

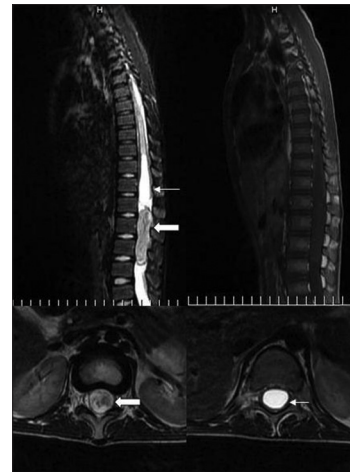


Figure 2: Magnetic resonance imaging reveals tumor at the level of VTh₁₁-VL₄ with solid (large arrow) and cystic (small arrow) part

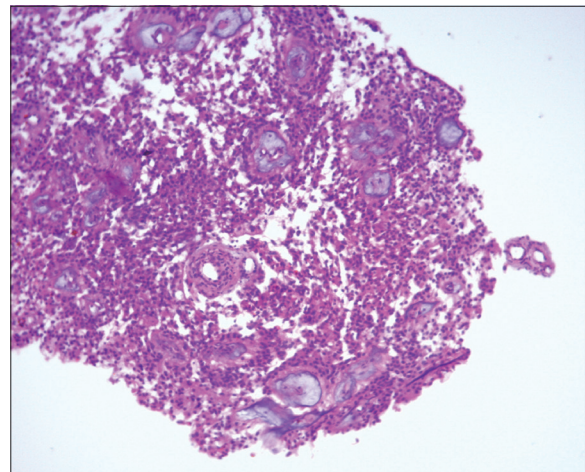


Figure 4: Tumor cells around vessels with mucoid degeneration

If the headache and vomiting are due to subarachnoid hemorrhage, the upper paraparesis more indicative for cervical or thoracic spinal cord lesions. Electromyography identified lesion at the thoracic level of the spinal cord.

Radiological method of choice for diagnosis of the spinal cord tumors is MRI.^[12] In our case, MRI revealed a cauda equina tumor, intramedullary cyst of spinal cord cystic expansion of the central canal of the spinal cord, extending up to the cervical spine. MRI of the brain revealed no pathology. MRI data with the clinical picture showed subarachnoid hemorrhage, as well as compression of the spinal cord at the cervical-thoracic cystic expansion of the central canal.

As with other benign tumors of cauda equina at ME surgical treatment is the method of choice.^[13] With the involvement of the spinal cord cone intraoperative use of somatosensory evoked potentials favorably in order to achieve better outcome. However, in our case for due to some technical reasons, we could not use it.

Although the tumor is benign, the risk of dissemination by cerebrospinal fluid (CSF) pathways conserved. In this connection, it is advisable to supplement the surgery radiotherapy.^[14]

Despite the fact that the prognosis of good recovery at syndrome of cauda equina and spinal cord cone less favorable compared with other types of neurological deficits,^[1] in our opinion surgical intervention is justified at least in terms of prevention of subarachnoid hemorrhage. Rapid regression of clinical symptoms in our observation was associated with the release of cauda equina roots, as well as restoration of the flow of CSF of the central spinal canal.

Conclusion

Myxopapillary ependymoma may have variable cranial and/or spinal clinical symptoms. This makes it difficult to diagnose and delaying the surgery. The surgeon must be aware of the atypical manifestations of this disease. In the absence of diagnosed intracranial causes, cases with headaches and vomiting require detailed neuroimaging studies throughout the CNS.

References

1. Al-Hussaini M, Herron B. Metastasizing myxopapillary ependymoma. *Histopathology* 2005;46:469-70.
2. Chan HS, Becker LE, Hoffman HJ, Humphreys RP, Hendrick EB, Fitz CR, *et al.* Myxopapillary ependymoma of the filum terminale and cauda equina in childhood: Report of seven cases and review of the literature. *Neurosurgery* 1984;14:204-10.
3. Wostrack M, Shibani E, Obermueller T, Gempt J, Meyer B, Ringel F. Conus medullaris and cauda equina tumors: Clinical presentation, prognosis, and outcome after surgical treatment: Clinical article. *J Neurosurg Spine* 2014;20:335-43.
4. Estey A, Lim R. Sudden-onset back pain and cauda equina syndrome in an adolescent: A case report. *Pediatr Emerg Care* 2010;26:672-5.
5. Patrona A, Harders A, Schmieder K, Scholz M. Intraventricular bleeding and transient hydrocephalus in a patient with hemorrhagic filum terminale ependymoma undergoing anticoagulation therapy with phenprocoumon. *Clin Neurol Neurosurg* 2010;112:252-7.
6. Nozaki I, Matsumoto Y, Yamaguchi K, Shimizu Y, Kumahashi K, Munemoto S. A case of lumbar myxopapillary ependymoma discovered due to headache. *Rinsho Shinkeigaku* 2013;53:136-42.
7. Bollo RJ, Zagzag D, Samadani U. Synchronous choroid plexus papilloma of the fourth ventricle and ependymoma of the filum terminale: Case report. *Neurosurgery* 2010;67:E1454-9.
8. Tzekov C, Naydenov E, Kalev O. Ependymoma of the cauda equina starting with communicating hydrocephalus: A case report. *Pediatr Neurosurg* 2007;43:399-402.
9. Drozdowski W, Pogorzelski R. Features of intracranial hypertension as a manifestation of cauda equina tumor. *Neurol Neurochir Pol* 2004;38:227-30.
10. Wang M, Wang H, Zhou Y, Zhan R, Wan S. Myxopapillary ependymoma in the third ventricle area and sacral canal: Dropped or retrograde metastasis? *Neurol Med Chir (Tokyo)* 2013;53:237-41.
11. Park JE, Chung ME, Song DH, Choi HS. Inexplicable abdominal pain due to thoracic spinal cord tumor. *Ann Rehabil Med* 2014;38:273-6.
12. Hallacq P, Labrousse F, Streichenberger N, Lisii D, Fischer G. Bifocal myxopapillary ependymoma of the terminal filum: The end of a spectrum? Case report. *J Neurosurg* 2003;98:288-9.
13. Meneses MS, Leal AG, Periotto LB, Milano JB, Coelho-Net M, Sobral AC, *et al.* Primary filum terminale ependymoma: A series of 16 cases. *Arq Neuropsiquiatr* 2008;66:529-33.
14. Nakamura M, Ishii K, Watanabe K, Tsuji T, Matsumoto M, Toyama Y, *et al.* Long-term surgical outcomes for myxopapillary ependymomas of the cauda equina. *Spine (Phila Pa 1976)* 2009;34:E756-60.

How to cite this article: Kariev GM, Halikulov ES, Rasulov SO. Unspecific clinical manifestation of cauda equina myxopapillary ependymoma. *Asian J Neurosurg* 2015;10:256-8.
Source of Support: Nil, **Conflict of Interest:** None declared.