

## CASE REPORT

# Treatment of arteriovenous malformation with high-flow fistula and bilateral transverse-sigmoid sinuses stenosis resulting diffuse cortical vein engorgement and symptoms resembling carotid-cavernous fistula

Kuo-Wei Chen, I-Chang Su<sup>1</sup>, Jing-Er Lee<sup>2</sup>, Hon-Man Liu<sup>3</sup>

Department of Surgery, Division of Neurosurgery, National Taiwan University Hospital, <sup>1</sup>Department of Surgery, Cathay General Hospital, <sup>2</sup>Department of Neurology, Taipei Medical University, Wan Fang Hospital, <sup>3</sup>Department of Radiology, National Taiwan University Hospital, Taipei, Taiwan

## ABSTRACT

Patients harboring arteriovenous malformations (AVMs) may present with focal neurological deficit, seizures, hemorrhage or be completely asymptomatic. This diversity in manifestation of AVM is related to the individual characteristics of AVMs such as size, location, configuration of feeding arteries, and drainage veins. Treating the AVMs with high-flow fistula and downstream sinuses occlusion is challenging. The authors reported their experience of treating this kind of AVM. The high venous pressure caused diffuse cortical venous regurgitation and engorgement of left superior ophthalmic vein and symptoms resembling carotid-venous fistula. To avoid possible reflux of embolization materials to cortical veins and facilitate surgical treatment, the bilateral transverse sinuses were re-canalized first. The venous pressure was measured through left transverse sinus, and it decreased significantly from 50 mmHg to 20 mmHg after bilateral sinus stenting. The AVM was then embolized and excised uneventfully.

**Key words:** Arteriovenous malformation, sinus occlusion, venous hypertension

## Introduction

Treating the arteriovenous malformations (AVMs) with high-flow fistula and downstream sinuses occlusion is challenging.<sup>[1-5]</sup> A series of 13 cases of AVM with venous anomaly and brain edema has been reported.<sup>[5]</sup> Seven patients underwent embolization, and one of them had further surgical resection. Four patients including the one had surgery suffered from intracerebral hemorrhage (ICH). Two had N-butyl-2-cyanoacrylate (NBCA) reflux from the high-flow

shunt into the dilated venous sac and resulted in ICH. We suggested a new treatment concept by relieving the high venous pressure first to reduce the possibility of embolization material reflux. The AVM was then embolized and excised uneventfully.

## Case Report

**History and Examination:** A 49-year-old woman denied history of head trauma or central nervous system infection. She had been experiencing headache, dizziness, progressive left eye proptosis, and congestion for 5 years [Figure 1a and b]. She was first treated as conjunctivitis, but her symptoms progressed. Under the impression of carotid-cavernous fistula (CCF), computed tomography (CT) and CT angiography (CTA) was arranged. CTA revealed a right parieto-occipital AVM and bilateral transverse-sigmoid sinus occlusion with diffuse engorged cortical drainage veins. Angiography revealed that the branches of the right middle cerebral artery (MCA) and posterior cerebral artery (PCA) constituted the feeders of the AVM, and one prominent early drainage vein drained into the superior sagittal sinus. The AVM contained a high-flow fistula, and the high venous pressure of the large shunting of AVM caused reflux of venous blood from the superior sagittal

### Access this article online

#### Quick Response Code:



#### Website:

[www.asianjns.org](http://www.asianjns.org)

#### DOI:

10.4103/1793-5482.162715

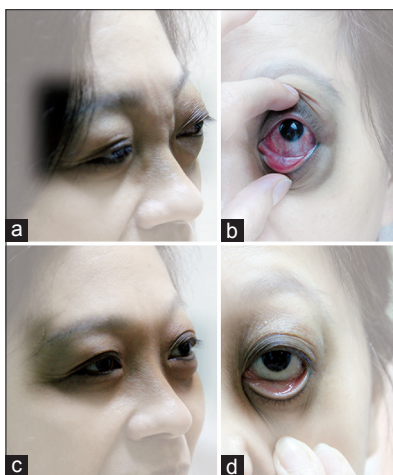
### Address for correspondence:

Dr. Kuo-Chen Wei, Department of Surgery,  
 Division of neurosurgery, National Taiwan University Hospital,  
 7 Chun-Shun South Road,  
 Taipei 100, Taiwan. E-mail: wang081466@yahoo.com.tw

sinus and left transverse sinus into cortical veins. The site of occlusion of the left transverse sinus was distal to the origin of the vein of Labbé, leading to engorgement of the left vein of Labbé and both the veins of Trolard. The left cavernous sinus collected more than half of the venous return of the brain and caused left superior ophthalmic vein engorgement and symptoms mimicking CCF [Figure 2].

**Treatment:** The patient underwent two sessions of endovascular procedures. The primary goal of the first session was to re-canalize the obstructive transverse sinuses and to decrease the venous pressure. Access to the right femoral arterial was obtained with a 6-Fr sheath, and a 6-Fr guiding catheter was placed in the right internal carotid artery. The left femoral vein was accessed, and a 7-Fr shuttle guide catheter was positioned into left jugular bulb. A 0.008-inch guidewire was then advanced across the obstructed portion of the distal left transverse sinus. The venous pressure was measured over 50 mmHg. The obstruction was opened by performing a serial angioplasty procedure with 5 mm × 20 mm, 7 mm × 20 mm angioplasty balloons, followed by deployment of a 9 mm × 30 mm Cordis Precise Nitinol self-expanding stent (Cordis Corp., USA). After stent placement, anterograde flow of the left transverse-sigmoid sinus was obvious, and there was a significant decrease of ipsilateral cortical venous reflux [Figure 3]. Then, the AVM was embolized by super-selective catheterization of multiple feeders from the MCA and was injected with 20–40% NBCA/lipiodol mixture. This resulted in a significant decrease of the arteriovenous (AV) shunting flow. The venous pressure decreased to about 30 mmHg. Following this, the occluded right transverse sinus was opened using a similar process, and lastly a 7 mm × 40 mm nitinol stent was positioned. The final venous pressure was around 20 mmHg.

A few days later, the second session of AVM embolization was conducted. 20–30% NBCA/lipiodol mixture was injected



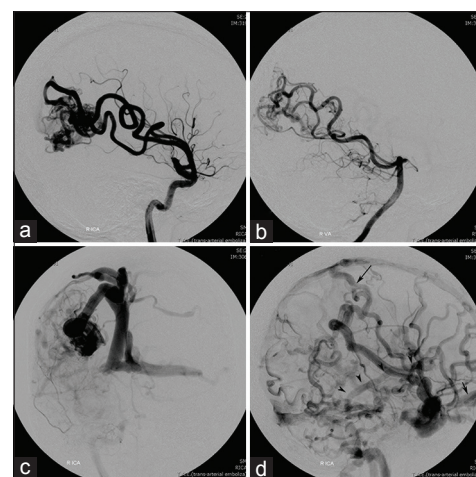
**Figure 1:** (a and b) She suffered from left eye ptosis and chemosis. (c and d) After embolization, before surgical excision, her symptoms improved dramatically

into the feeders from the MCA and PCA. On the immediate postprocedural angiogram, only minimal residuals of AV shunting remained, and both the transverse-sigmoid sinuses were patent without cortical venous reflux. Her symptoms improved immediately [Figure 1c and d]. She did not take anti-platelet medication and underwent AVM excision 5 days later. Three days later, she began to take aspirin 100 mg QD. She recovered well except mild left lower quadrantanopsia.

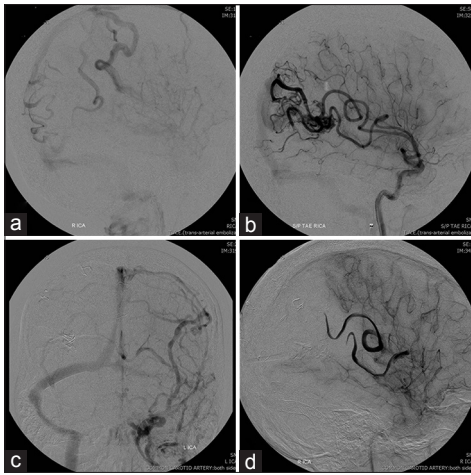## Discussion

Arteriovenous malformations are abnormalities of intracranial vessels consisting of feeding arteries, draining veins, and a nidus that acts as a shunt from the arterial to the venous system. The absence of a capillary bed results in low resistance and high-flow AV shunting, and subsequently venous hypertension and arterial hypotension.<sup>[2,6,7]</sup> AVMs are considered as congenital anomalies that undergo remodeling to take their mature form. The mechanical action of pressure and shearing stress on the endothelium cause hyperplasia of the smooth muscle cells in the tunica media of the draining veins and distal sinus.<sup>[7,8]</sup> This also causes intimal damage and release of pro-inflammatory cytokines.<sup>[6]</sup> This phenomenon contributes to venous stenosis and obstruction of sinus.<sup>[2,6-10]</sup> A case report demonstrated that a patient with left parietal AVM with a high-flow direct fistula who developed high-grade superior sagittal sinus stenosis 5 years later. These authors concluded that AVM could cause high-flow occlusive venopathy in a major sinus.<sup>[8]</sup>

Our case showed a high-flow fistula and the high-flow venopathy caused the occlusion of the downstream sinuses. In turn, the obstruction of both the transverse-sigmoid sinuses caused the reflux of venous blood along the superior



**Figure 2:** (a and b) Arteriovenous malformation with high-flow fistula in the right parietal lobe with feeders from (a) the right middle cerebral artery and (b) posterior cerebral artery. (c) Obstruction of both the transverse-sigmoid sinuses. (d) High venous pressure causes diffuse engorgement of cortical veins including the vein of Trolard (long arrow), the vein of Labbé (arrow heads), and the superior ophthalmic vein (short arrow)



**Figure 3:** (a) After opening the left transverse-sigmoid sinus, the venous reflux decreases significantly. (b) The embolization further decreases the arteriovenous (AV) shunting. (c and d) The follow-up angiography shows no residual AV malformation and patent transverse-sigmoid sinuses

sagittal sinus and left a vein of Labbé. This transmitted the pressure to the left cavernous sinus and caused left superior ophthalmic vein engorgement. Treating this kind of AVM requires extra considerations. The high-flow fistula posed additional risk of perioperative bleeding, and preoperative embolization is often considered of utmost importance.<sup>[4,5]</sup> However, when performing embolization, care must be taken since overshooting the shunting zone into the drainage veins and reflux into the already hypertensive cortical veins is possible. A series of 13 cases of AVM with venous anomaly and brain edema has been reported.<sup>[5]</sup> Seven patients underwent embolization, and one of them had further surgical resection. Four patients including the one had surgery suffered from ICH. Two had NBCA reflux from the high-flow shunt into the dilated venous sac and resulted in ICH within 24 h after the procedure. The one underwent surgery had total AVM excision, but postoperative venous congestion and ICH occurred 1-day later. He concluded that the increasing the efficiency of venous outflow could decrease the venous hypertension, and this is a possible treatment choice to manage this kind of AVM.

Therefore, we decided to do sinus stenting first to release the high venous pressure. During the procedure, we measured the venous pressure through left transverse sinus and surprisingly, it was higher than 50 mmHg. After stenting of the left side, the pressure decreased to 30 mmHg and dropped further to 20 mmHg after right transverse sinus stenting. The effect of the stent was evident and the size of the drainage veins reduced immediately [Figure 3]. Subsequently, we used NBCA as our

embolic material, and embolization was done successfully. Five days after the endovascular procedure, she had surgery and began taking anti-platelet 3 days later.

In summary, the manifestation of AVMs is diverse. AVM treatment requires completely understanding the pathophysiology and should be specialized for the individual. Endovascular re-canalization is a treatment choice for AVMs associated with high-flow fistula with downstream sinus occlusion. After recanalization, the venous hypertension and regurgitation is reduced, which facilitates embolization and surgery.

## Acknowledgment

Special thanks to our patient for permitting us to use her photos.

## References

1. Lv X, Li Y, Yang X, Jiang C, Wu Z. Characteristics of brain arteriovenous malformations in patients presenting with nonhemorrhagic neurologic deficits. *World Neurosurg* 2013;79:484-8.
2. Moftakhar P, Hauptman JS, Malkasian D, Martin NA. Cerebral arteriovenous malformations. Part 2: Physiology. *Neurosurg Focus* 2009;26:E11.
3. Stapf C, Mast H, Sciacca RR, Choi JH, Khaw AV, Connolly ES, et al. Predictors of hemorrhage in patients with untreated brain arteriovenous malformation. *Neurology* 2006;66:1350-5.
4. Yuki I, Kim RH, Duckwiler G, Jahan R, Tateshima S, Gonzalez N, et al. Treatment of brain arteriovenous malformations with high-flow arteriovenous fistulas: Risk and complications associated with endovascular embolization in multimodality treatment. *Clinical article. J Neurosurg* 2010;113:715-22.
5. Kim BS, Sarma D, Lee SK, terBrugge KG. Brain edema associated with unruptured brain arteriovenous malformations. *Neuroradiology* 2009;51:327-35.
6. Panciani PP, Fontanella M, Carlino C, Bergui M, Ducati A. Progressive spontaneous occlusion of a cerebellar AVM: Pathogenetic hypothesis and review of literature. *Clin Neurol Neurosurg* 2008;110:502-10.
7. Fleetwood IG, Steinberg GK. Arteriovenous malformations. *Lancet* 2002;359:863-73.
8. Song JK, Patel AB, Duckwiler GR, Gobin YP, Jahan R, Martin NA, et al. Adult pial arteriovenous fistula and superior sagittal sinus stenosis: Angiographic evidence for high-flow venopathy at an atypical location. *Case report. J Neurosurg* 2002;96:792-5.
9. Abdulrauf SI, Malik GM, Awad IA. Spontaneous angiographic obliteration of cerebral arteriovenous malformations. *Neurosurgery* 1999;44:280-7.
10. Viñuela F, Nombela L, Roach MR, Fox AJ, Pelz DM. Stenotic and occlusive disease of the venous drainage system of deep brain AVM's. *J Neurosurg* 1985;63:180-4.

**How to cite this article:** Chen KW, Su IC, Lee JE, Liu HM. Treatment of arteriovenous malformation with high-flow fistula and bilateral transverse-sigmoid sinuses stenosis resulting diffuse cortical vein engorgement and symptoms resembling carotid-cavernous fistula. *Asian J Neurosurg* 2015;10:310-2.

**Source of Support:** Nil, **Conflict of Interest:** None declared.