

## CASE REPORT

# Enigmatic intracranial cyst causing diplopia and trigeminal neuralgia

Pavan Kumar Pelluru, Alugolu Rajesh

Department of Neurosurgery, Nizam's Institute of Medical Sciences, Punjagutta, Hyderabad, Telangana, India

## ABSTRACT

Chronic compression by intracranial cystic lesions can cause cranial nerve palsies and bony changes. With the advent of imaging techniques, grossly accurate diagnosis is possible. However, few cases do surprise the clinicians both intra, and postoperatively. A 27-year-old male presented to us with complaints of double vision for 4 months followed by sharp, shooting pain in the left V1 and V2 distribution for 1-month duration, on examination, he had left lateral palsy and decreased pin prick and temperature sensation in V1 distribution. On computed tomography scan, a cystic lesion noted which is isodense in the middle cranial fossa with erosion of the underlying bone. On magnetic resonance imaging lesion was iso to hyperintense on T1-Weighted and hyperintense on T2-Weighted, brilliantly enhancing on contrast administration. Provisional diagnosis was trigeminal schwannoma, left temporal craniotomy and total excision of the cyst done. Histopathological examination showed cyst wall lined with collagen. Postoperatively patient neuralgic pain subsided with persisting sixth nerve palsy.

**Key words:** Cystic lesion, lateral rectus palsy, trigeminal neuralgia

## Introduction

Arachnoid cysts are a type of pseudocysts, formed as a result of collection of cerebrospinal fluid (CSF) between arachnoid layers. Primary arachnoid cysts are developmental abnormalities, whereas secondary arachnoid cysts can result from trauma, infection, surgery, or previous hemorrhage.<sup>[1,2]</sup> These may be asymptomatic or may expand gradually, causing signs and symptoms by raised intra-cranial pressure. On neuroimaging, these lesions appear as smooth-bordered, noncalcified, extraparenchymal cystic masses with a density similar to CSF and no enhancement on intravenous contrast administration. They can cause chronic expansion and remodeling of nearby bone.<sup>[3-5]</sup> Most occur in the anterior half of the middle cranial fossa around the origin of sylvian fissure.<sup>[6]</sup> Most of the cyst are asymptomatic detected incidentally. However, subtle clinical manifestation include chronic headache, seizures, decreased scholastic performance. They are, however, rare to produce

raised intracranial pressure (except when causing compression of ventricular outlet or progressively increasing due to the ball-valve effect) or cranial nerve deficits.

## Case Report

A 27-year-old male presented to us with complaints of double vision while looking toward his left for 1-year, which was progressive to cause difficulty in looking to his left for over 6 months period, followed by pain in the upper half of face for about 1-month, the pain was sharp, shooting in character, localized to the left frontal and temporal region, aggravated on talking, chewing, brushing, blowing of air. Patient is not a known hypertensive or diabetic. No history of paresthesias or weakness in the limbs. No history trauma. Previous medical history was unremarkable.

On examination, his higher mental functions are normal. Left lateral rectus palsy is noted with decreased sensations in the V1 and V2 distribution of the trigeminal nerve to pin prick and temperature. No other cranial nerve deficits. No motor or sensory deficits. Bilateral plantars are flexor. No signs of meningeal irritation.

## Imaging

On computed tomography, (CT) imaging an isodense lesion noted in the anterior half of middle cranial fossa with erosion of the underlying bone [Figure 1]. On magnetic resonance (MR) imaging lesion is iso to hypointense on T1-Weighted and hyperintense on T2-Weighted imaging, brilliantly enhancing on contrast administration. On MR angiography, there is splaying of surrounding arteries [Figure 2]. Provisional

### Access this article online

#### Quick Response Code:



#### Website:

www.asianjns.org

#### DOI:

10.4103/1793-5482.162717

### Address for correspondence:

Dr. Alugolu Rajesh, Department of Neurosurgery, Nizam's Institute of Medical Sciences, Punjagutta, Hyderabad - 500 082, Telangana, India.  
E-mail: drarajesh1306@gmail.com

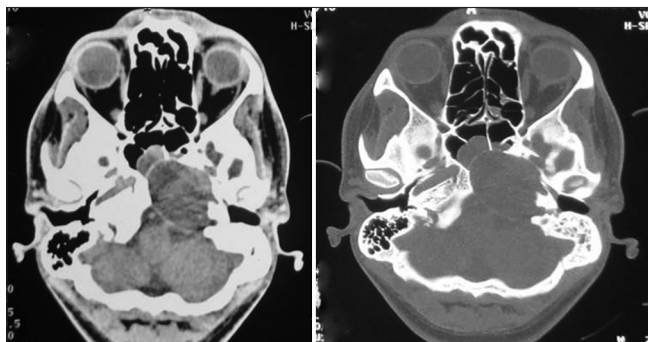
diagnosis is trigeminal schwannoma, middle cerebral artery aneurysm, meningioma.

Patient underwent temporal craniotomy and extra-dural approach to the cavernous sinus. Per operatively a cystic lesion was found from the anterior temporal-based extending posteriorly along the lateral wall of cavernous sinus, splaying the ganglion and extending inferiorly along V2, cyst is occupying the space between the foramen rotundum and ovale, eroding the petrous apex. Cyst was filled with approximately 25cc of xanthochromic fluid. Cyst was partially excised and sent for histopathological examination, which showed cyst wall lined with collagen fibers. In the postoperative period patient did well, pain in the V1 distribution subsided. Postoperative CT scan showed complete removal of the cyst. After 18 months, follow-up there is persisting sixth nerve palsy on the left side with no recurrence of neuralgic pain.

### Discussion

Arachnoid cysts are congenital fluid-filled cavities, circumscribed by arachnoid membrane, which have settled in the cisternae and major cerebral fissures. Arachnoid cysts account for approximately 1% of all intracranial mass lesions.<sup>[7]</sup> Congenital cysts appear to originate from alterations in CSF flow in the early phase of sub-arachnoid space formation.<sup>[8]</sup> Two-thirds are located in the Supratentorial space; half of which (50%) are in relation to the Sylvian cistern. Other locations include the suprasellar region (10%), convexity (5%), interhemispheric (5%), and intraventricular (2%). The remaining third are located in the posterior fossa with vermis and cisterna magna (12%), cerebellopontine angle (8%), quadrigeminal plate (5%) and prepontine (1%).<sup>[9]</sup>

Usually arachnoid cyst are asymptomatic, occasionally become symptomatic due to their pressure effects on surrounding structures, symptoms include headache, seizures, mental retardation, cognitive impairment and rarely focal neurological deficits. Most arachnoid cysts remain stable throughout life; however, some can enlarge due to various mechanisms such as



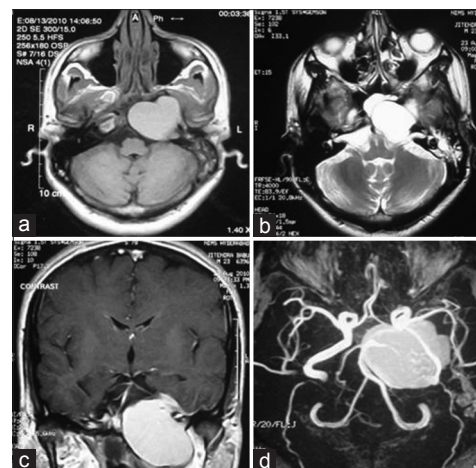
**Figure 1:** Computed tomography scan of the brain with bone windows showing an isodense lesion in the middle cranial fossa causing erosion of the petrous apex on the left side

(a) Active CSF secretion from the cyst membrane<sup>[10]</sup> (b) osmotic gradients caused by a higher protein concentration in the cyst fluid, or (c) cyst contents communicating with the subarachnoid space via ball-valve mechanisms that entrap CSF during Valsalva maneuvers.<sup>[11-13]</sup> Supratentorial cysts are more frequently encountered, with nearly half of all cysts occurring within the sylvian fissure.<sup>[10]</sup> Less frequent locations include the interhemispheric fissure and the petroclival region. Cysts of the suprasellar region are more commonly encountered in children than in adults.<sup>[14]</sup> Surgical management should be considered only for increasing cysts causing neural compression, hydrocephalus, or refractory symptoms secondary to mass effect.<sup>[15,16]</sup>

In our case, patient has neuralgic pain in the trigeminal distribution with sixth nerve palsy and CT imaging the hypodense lesion is extending into the infra-temporal fossa with erosion of the underlying bone favoring a diagnosis of trigeminal schwannoma, however, histopathological examination is arachnoid cyst. Compression of cranial nerves VII or V can cause facial palsy, hemifacial spasm and/or neuralgic pain.<sup>[17]</sup> Eslick *et al.* reported a case of arachnoid cyst in the cerebellopontine angle causing diplopia due to direct compression of the cranial nerve VI.<sup>[18]</sup> In 2002, Batra *et al.*<sup>[19]</sup> described a case of right-sided trigeminal neuralgia secondary to arachnoid cyst in the petrous region.

Another differential will be echordosis physaliphora (EP), a benign lesion, which arises from ectopic notochordal remnants, lying along the craniospinal axis from the clivus to the sacrococcygeal region.<sup>[20,21]</sup>

It is a gelatinous nodule, varying in size from a few millimeters to 2 cm, exhibiting a slow growth pattern. Intracranial EP is typically found intradurally in the prepontine cistern where it



**Figure 2:** Magnetic resonance (MR) imaging brain axial (a, and b) and coronal contrast. (c) A lesion iso to hyperintense on T1-Weighted, hyperintense on T2-Weighted images with uniform contrast enhancement extending into the infratemporal region; (d) splaying of the vessels as noted in MR angiogram

is attached to the dorsal wall of the clivus via a small pedicle, cartilaginous/osseous in origin. EP in this region is usually asymptomatic and found incidentally in 0.4-2% of autopsies. Three variants have been described-the (a) classical type of EP is frequently associated with a T2 hypointense protrusion. (b) T2-Weighted hypointense protrusions without clivus cysts may represent an incomplete type of EP. (c) Third type of EP variant only harbors lesions within the clivus.<sup>[22]</sup> Ours was probably incomplete type of EP.

The patient was doing well at 1-month follow-up and was lost to follow-up thereafter.

## Conclusion

Cystic lesions around the clivus are rare and in the presence of isolated abducent pathology a strong possibility of chordoma and its variants-like echordosis should be kept in mind.

## References

1. Enzmann DR, Pelc NJ. Cerebrospinal fluid flow measured by phase-contrast cine MR. *AJNR Am J Neuroradiol* 1993;14:1301-7.
2. Giudicelli G, Hassoun J, Choux M, Tonon C. Supratentorial "arachnoia" cysts. *J Neuroradiol* 1982;9:179-201.
3. Hara H, Inoue T, Matsuo K, Kobayashi S, Sugita K. Unusual computed tomographic findings in a case of arachnoid cyst in the middle cranial fossa. *Surg Neurol* 1984;22:79-82.
4. Shaw CM. "Arachnoid cysts" of the sylvian fissure versus "temporal lobe agenesis" syndrome. *Ann Neurol* 1979;5:483-5.
5. Starkman SP, Brown TC, Linell EA. Cerebral arachnoid cysts. *J Neuropathol Exp Neurol* 1958;17:484-500.
6. Barker RA, Phillips RR, Moseley IF, Taylor WJ, Kitchen ND, Scadding JW. Posterior communicating artery aneurysm presenting with haemorrhage into an arachnoid cyst. *J Neurol Neurosurg Psychiatry* 1998;64:558-60.
7. Robinson RG. Congenital cysts of the brain: Arachnoid malformations. *Prog Neurol Surg* 1971;4:133-74.
8. Lemire R, Loeser J, Leech R, Alvord EJ. Normal and Abnormal Development of the Human Nervous System. New York: Harper and Row; 1975.
9. Wester K. Peculiarities of intracranial arachnoid cysts: Location, sidedness, and sex distribution in 126 consecutive patients. *Neurosurgery* 1999;45:775-9.
10. Rengachary SS, Watanabe I. Ultrastructure and pathogenesis of intracranial arachnoid cysts. *J Neuropathol Exp Neurol* 1981;40:61-83.
11. Caemaert J, Abdullah J, Calliauw L, Carton D, Dhooze C, van Coster R. Endoscopic treatment of suprasellar arachnoid cysts. *Acta Neurochir (Wien)* 1992;119:68-73.
12. Santamarta D, Aguas J, Ferrer E. The natural history of arachnoid cysts: Endoscopic and cine-mode MRI evidence of a slit-valve mechanism. *Minim Invasive Neurosurg* 1995;38:133-7.
13. Schroeder HW, Gaab MR. Endoscopic observation of a slit-valve mechanism in a suprasellar prepontine arachnoid cyst: case report. *Neurosurgery* 1997;40:198-200.
14. Rengachary SS, Watanabe I, Brackett CE. Pathogenesis of intracranial arachnoid cysts. *Surg Neurol* 1978;9:139-44.
15. Raffel C, McComb JG. To shunt or to fenestrate: which is the best surgical treatment for arachnoid cysts in pediatric patients? *Neurosurgery* 1988;23:338-42.
16. Stein SC. Intracranial developmental cysts in children: Treatment by cystoperitoneal shunting. *Neurosurgery* 1981;8:647-50.
17. Ottaviani F, Neglia CB, Scotti A, Capaccio P. Arachnoid cyst of the cranial posterior fossa causing sensorineural hearing loss and tinnitus: A case report. *Eur Arch Otorhinolaryngol* 2002;259:306-8.
18. Eslick GD, Chalasani V, Seex K. Diplopia and headaches associated with cerebellopontine angle arachnoid cyst. *ANZ J Surg* 2002;72:915-7.
19. Batra A, Tripathi RP, Singh AK, Tatke M. Petrous apex arachnoid cyst extending into Meckel's cave. *Australas Radiol* 2002;46:295-8.
20. Lantos PL, Louis DN, Rosenblum MK, Kleihues P. Tumours of the nervous system. In: Graham DI, Lantos PL, editors. *Greenfield's Neuropathology*. 7<sup>th</sup> ed., Vol. 2. London: Arnold; 2002. p. 767-1052.
21. Rodriguez L, Colina J, Lopez J, Molina O, Cardozo J. Intradural prepontine growth: Giant echordosis physaliphora or extraosseous chordoma? *Neuropathology* 1999;19:336-40.
22. Chihara C, Korogi Y, Kakeda S, Nishimura J, Murakami Y, Moriya J, et al. Echordosis physaliphora and its variants: Proposed new classification based on high-resolution fast MR imaging employing steady-state acquisition. *Eur Radiol* 2013;23:2854-60.

**How to cite this article:** Pelluru PK, Rajesh A. Enigmatic intracranial cyst causing diplopia and trigeminal neuralgia. *Asian J Neurosurg* 2015;10:316-8.

**Source of Support:** Nil, **Conflict of Interest:** None declared.