

CASE REPORT

The unusual angiographic course of intracranial pseudoaneurysms

Mario Zanaty, Nohra Chalouhi, Pascal Jabbour, Robert M. Starke¹, David Hasan²

Department of Neurosurgery, Thomas Jefferson University Hospital, Philadelphia, ¹Department of Neurosurgery, University of Virginia, School of Medicine, Charlottesville, Virginia, ²Department of Neurosurgery, Carver College of Medicine, University of Iowa, Iowa City, Iowa, USA

ABSTRACT

Although rare, traumatic intracranial pseudoaneurysms remain one of the most difficult vascular lesions to diagnose and treat. A 55-year-old male patient underwent endoscopic endonasal transphenoidal resection for a pituitary macroadenoma. The operation was complicated by an arterial bleed. The initial angiogram revealed pseudoaneurysm of the anterior choroidal artery. Although the pseudoaneurysm completely disappeared on the second angiogram, it was surprisingly found to have enlarged on the third angiogram. The lesion was successfully treated with flow-diversion using a pipeline embolization device. The present case demonstrates that the natural history of iatrogenic pseudoaneurysms may be unpredictable and misleading. Traumatic pseudoaneurysms should, therefore, be carefully followed when conservative treatment is elected or when the lesion seems to have spontaneously regressed. Flow-diversion seems to be a reasonable treatment option.

Key words: Flow-diversion, intracranial aneurysms, pipeline, traumatic pseudoaneurysms

Introduction

Pseudoaneurysms are uncommon and account for 1% of all intracranial aneurysms^[1] and 0.5–6.5% of internal carotid artery (ICA) aneurysms.^[2-4] They may result from blunt or penetrating trauma to the head, and in many cases from surgical injury.

This type of aneurysm poses a challenge to traditional surgical and endovascular treatment because of its morphology and small size. Furthermore, the natural history of these lesions is unclear. Although spontaneous closure has been reported in the literature, pseudoaneurysms are usually associated with a high risk of bleeding, relapse, and perioperative complications.^[1,5,6] No consensus has been made on their management so far.

Case Report

The patient is a 55-year-old male who presented with diplopia and bitemporal hemianopsia. He was later found to harbor a pituitary macroadenoma [Figure 1]. The patient underwent endoscopic endonasal transsphenoidal surgery for tumor resection. At the completion of the resection, brisk bleeding was encountered after removal of the ring curet from the intradural space. The bleeding was packed with thrombin-soaked cottonoids and Floseal until complete hemostasis was achieved. The patient remained hemodynamically stable throughout the procedure despite the loss of over 1 L of blood volume. A vascular injury was suspected, and the patient was then transported while remaining intubated, to the computerized tomography (CT) scanner where a noncontrast head-CT was performed. An immediate angiogram was also obtained. The angiogram demonstrated a pouch just below the takeoff of the anterior choroidal artery consistent with an iatrogenic pseudoaneurysm [Figure 2]. The decision was made to wait 2 days for the pouch to mature before proceeding with coiling. On postoperative day 3, a second angiogram was performed showing complete resolution of the pouch [Figure 3]. Because of the suspicious course of the pseudoaneurysm, a repeat angiogram was performed 1-week later, and to our surprise, demonstrated a 1.3 mm × 1.5 mm pseudoaneurysm in the left ICA [Figure 4]. The pseudoaneurysm was therefore back and enlarged. The decision was made to treat the aneurysm with placement of a pipeline embolization device (PED). Treatment

Access this article online

Quick Response Code:



Website:

www.asianjns.org

DOI:

10.4103/1793-5482.162721

Address for correspondence:

Dr. David Hasan, Department of Neurological Surgery, Division of Endovascular and Neurovascular Surgery, University of Iowa Hospitals and Clinics, 200 Hawkins Drive, JCP 1616, Iowa City, IA 52242, USA. E-mail: david-hasan@uiowa.edu

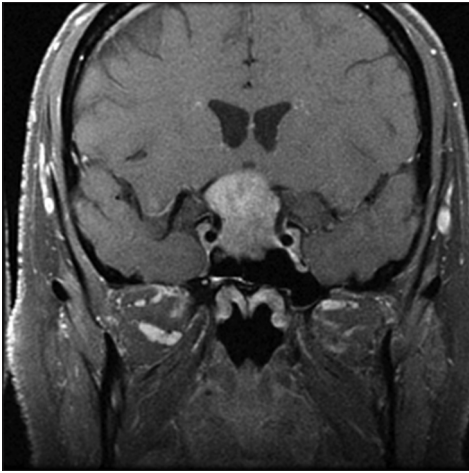


Figure 1: Preoperative magnetic resonance imaging showing a pituitary macroadenoma

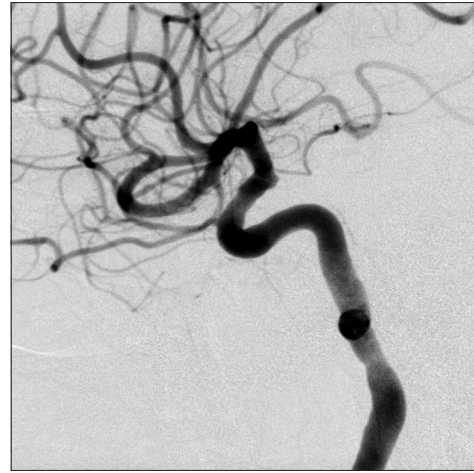

Figure 2: Perioperative angiogram showing a small pouch suggestive of pseudoaneurysm, just below the level of the takeoff of the left anterior choroidal artery

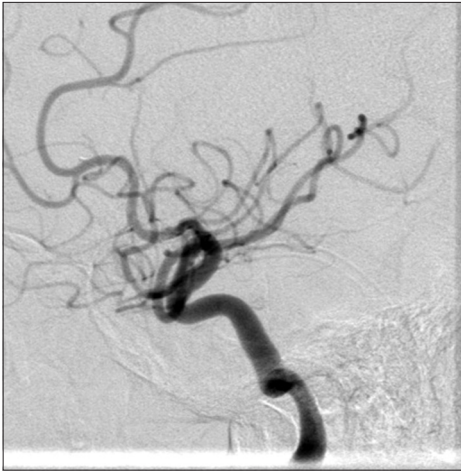

Figure 3: Second postoperative day angiogram showing a complete resolution of the pouch and disappearance of the pseudoaneurysm

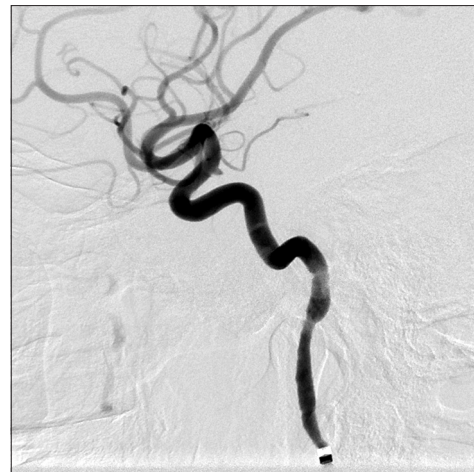


Figure 4: Angiogram, 1-week after the surgery before pipeline embolization device placement, shows a 1.5 mm x 1.3 mm left internal carotid artery pseudoaneurysm

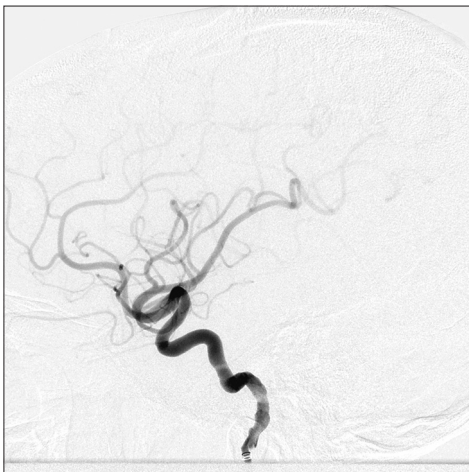

Figure 5: Angiogram after pipeline embolization device placement shows no evidence of stenosis, proximal, distal, or within the device, and there is no evidence of embolus or occlusion at any of the intracranial vessels

with PED was successful [Figure 5] and the patient remained neurologically stable after the procedure.

Discussion

The small size of pseudoaneurysms along with their particular morphology makes them difficult to diagnose on computerized tomography angiography (CTA) and even on digital subtraction angiography (DSA).^[7,8] In a recent study, 50% (6/12) of pseudoaneurysms that presented with rupture were missed on CTA and 25% (3/12) were missed even on the first DSA.^[8] Once they are formed, they might rapidly expand in volume, progress to saccular shape, and end up having a high rebleeding risk.^[8,9] The present case report serves to demonstrate that the progression of iatrogenic pseudoaneurysms might be misleading. In fact, the pseudoaneurysm disappeared on the second angiogram but was found to have increased in

size in 1-week later. This unusual and misleading course of a cerebral pseudoaneurysm has not been adequately reported in the literature. Neurointerventionists should be aware of this unusual course and obtain adequate follow-up when conservative treatment is considered or when the lesion seems to have spontaneously regressed. We believe that this phenomenon is due to the inherent properties of the pseudoaneurysm (which tend to enlarge or shrink spontaneously) as well as to vasospasm. However, one must be careful not to generalize the evolution of this type of pseudoaneurysm (iatrogenic), which may be different than traumatic pseudoaneurysms that form at the skull base and blood-borne blister-like aneurysm that arose from hemorrhagic dissection. It may be that different types of morphologically similar pseudoaneurysms have different evolution based on their underlying pathophysiology. Although traumatic and blood-borne blister-like aneurysms have been somewhat extensively evaluated, we present an unusual evolution of a pseudoaneurysm that might be due to its inherent properties.

The treatment of pseudoaneurysms can be threatening and hazardous, mainly due to the friability of the vessel wall that increases the risk of intraoperative rupture, and the absent or deformed neck that renders surgical clipping difficult.^[2,10,11] The small size of the aneurysm further complicates the intervention. Both open surgery and endovascular therapy have been utilized in the management of traumatic pseudoaneurysms. Surgical options include surgical trapping with or without the bypass, surgical wrapping, and parallel clipping.^[8,11] Clipping is usually offered as a first-line option when surgical treatment is considered.^[8] Surgery is typically indicated when the lesions are difficult to catheterize, or when endovascular therapy have failed to secure the lesion.^[8,10,11]

With the advent of endovascular therapy, some of these pseudoaneurysms have become amenable to treatment without sacrificing the parent artery. Endovascular techniques include coiling, stent-assisted coiling, telescoping stents, and flow-diversion.^[9-13] Lim *et al.* used a stent-in-stent assisted coil embolization of a traumatic ICA pseudoaneurysm.^[14] Liquid embolic agents have also been successfully used.^[15] Of the previously mentioned endovascular techniques, flow-diversion has been recently gaining grounds. Flow-diversion has been used for various types of aneurysms, including: Large and giant, wide-necked, pseudoaneurysms and saccular aneurysms.^[16-20] It has been also used for aneurysms of different locations, such as anterior and posterior circulation aneurysms.^[16,21-23,24] In a systemic review, endovascular treatment of pseudoaneurysms displayed a relatively low morbidity and mortality rate of 3.4% and 11.5% respectively.^[8] While coiling had the highest combined morbimortality, flow-diversion had the lowest.^[8] Flow-diversion offers the advantage of the exosaccular treatment, thus avoiding the risk of rupture

that exists with other endovascular modalities that require intrasaccular catheterization. However, one limitation of flow-diversion might be delayed aneurysm obliteration. Finally with flow-diversion, the risk of hemorrhage has to be weighed against the risk of thromboembolism. Since complete hemostasis was achieved in our case and the patient did not display any sign of bleeding, antiplatelet therapy with aspirin and clopidogrel could be instituted.

Conclusion

The present case report demonstrates that the natural history of cerebral iatrogenic pseudoaneurysms may be unpredictable and misleading. Traumatic pseudoaneurysms should, therefore, be carefully followed when conservative treatment is elected or when the lesion seems to have spontaneously regressed. While many treatment options are available, flow-diversion use has been recently gained traction.

References

1. Shigeta H, Kyoshima K, Nakagawa F, Kobayashi S. Dorsal internal carotid artery aneurysms with special reference to angiographic presentation and surgical management. *Acta Neurochir (Wien)* 1992;119:42-8.
2. Abe M, Tabuchi K, Yokoyama H, Uchino A. Blood blisterlike aneurysms of the internal carotid artery. *J Neurosurg* 1998;89:419-24.
3. Kim BM, Kim DI, Chung EC, Kim SY, Shin YS, Park SI, *et al.* Endovascular coil embolization for anterior choroidal artery aneurysms. *Neuroradiology* 2008;50:251-7.
4. Lee BH, Kim BM, Park MS, Park SI, Chung EC, Suh SH, *et al.* Reconstructive endovascular treatment of ruptured blood blister-like aneurysms of the internal carotid artery. *J Neurosurg* 2009;110:431-6.
5. Lee JW, Choi HG, Jung JY, Huh SK, Lee KC. Surgical strategies for ruptured blister-like aneurysms arising from the internal carotid artery: A clinical analysis of 18 consecutive patients. *Acta Neurochir (Wien)* 2009;151:125-30.
6. Ogawa A, Suzuki M, Ogasawara K. Aneurysms at nonbranching sites in the supraclinoid portion of the internal carotid artery: Internal carotid artery trunk aneurysms. *Neurosurgery* 2000;47:578-83.
7. Çinar C, Oran I, Bozkaya H, Özgiray E. Endovascular treatment of ruptured blister-like aneurysms with special reference to the flow-diverting strategy. *Neuroradiology* 2013;55:441-7.
8. Gonzalez AM, Narata AP, Yilmaz H, Bijlenga P, Radovanovic I, Schaller K, *et al.* Blood blister-like aneurysms: Single center experience and systematic literature review. *Eur J Radiol* 2014;83:197-205.
9. Park JH, Park IS, Han DH, Kim SH, Oh CW, Kim JE, *et al.* Endovascular treatment of blood blister-like aneurysms of the internal carotid artery. *J Neurosurg* 2007;106:812-9.
10. McLaughlin N, Laroche M, Bojanowski MW. Surgical management of blood blister-like aneurysms of the internal carotid artery. *World Neurosurg* 2010;74:483-93.
11. Le Feuvre DE, Taylor AG. The management of very small/blister internal carotid artery aneurysms. *Interv Neuroradiol* 2011;17:431-4.
12. Fiorella D, Albuquerque FC, Deshmukh VR, Woo HH, Rasmussen PA, Masaryk TJ, *et al.* Endovascular reconstruction with the Neuroform stent as monotherapy for the treatment of uncoilable intradural pseudoaneurysms. *Neurosurgery* 2006;59:291-300.
13. Bulsara KR, Kuzmik GA, Hebert R, Cheung V, Matouk CC, Jabbour P, *et al.* Stenting as monotherapy for uncoilable intracranial aneurysms. *Neurosurgery* 2013;73 1 Suppl Operative: On80-5.
14. Lim YC, Kang JK, Chung J. Reconstructive stent-butressed coil embolization of a traumatic pseudoaneurysm of the supraclinoid internal carotid artery. *Acta Neurochir (Wien)* 2012;154:477-80.
15. Medel R, Crowley RW, Hamilton DK, Dumont AS. Endovascular

- obliteration of an intracranial pseudoaneurysm: The utility of Onyx. *J Neurosurg Pediatr* 2009;4:445-8.
16. Chitale R, Gonzalez LF, Randazzo C, Dumont AS, Tjoumakaris S, Rosenwasser R, *et al.* Single center experience with pipeline stent: Feasibility, technique, and complications. *Neurosurgery* 2012;71:679-91.
 17. el-Chalouhi N, Jabbour PM, Tjoumakaris SI, Starke RM, Dumont AS, Liu H, *et al.* Treatment of large and giant intracranial aneurysms: Cost comparison of flow diversion and traditional embolization strategies. *World Neurosurg* 2014;82:696-701.
 18. Chalouhi N, Chitale R, Starke RM, Jabbour P, Tjoumakaris S, Dumont AS, *et al.* Treatment of recurrent intracranial aneurysms with the Pipeline Embolization Device. *J Neurointerv Surg* 2014;6:19-23.
 19. Chalouhi N, Starke RM, Yang S, Bovenzi CD, Tjoumakaris S, Hasan D, *et al.* Extending the indications of flow diversion to small, unruptured, saccular aneurysms of the anterior circulation. *Stroke* 2014;45:54-8.
 20. Chalouhi N, Zanaty M, Tjoumakaris S, Gonzalez LF, Hasan D, Kung D, *et al.* Treatment of blister-like aneurysms with the pipeline embolization device. *Neurosurgery* 2014;74:527-32.
 21. Chalouhi N, Tjoumakaris S, Dumont AS, Gonzalez LF, Randazzo C, Starke RM, *et al.* Treatment of posterior circulation aneurysms with the pipeline embolization device. *Neurosurgery* 2013;72:883-9.
 22. Zanaty M, Chalouhi N, Tjoumakaris SI, Gonzalez LF, Rosenwasser R, Jabbour P. Flow diversion for complex middle cerebral artery aneurysms. *Neuroradiology* 2014;56:381-7.
 23. Chalouhi N, Jabbour P, Starke RM, Zanaty M, Tjoumakaris S, Rosenwasser RH, *et al.* Treatment of a basilar trunk perforator aneurysm with the pipeline embolization device: Case report. *Neurosurgery* 2014;74:E697-701.
 24. Amenta PS, Starke RM, Jabbour PM, Tjoumakaris SI, Gonzalez LF, Rosenwasser RH, *et al.* Successful treatment of a traumatic carotid pseudoaneurysm with the Pipeline stent: Case report and review of the literature. *Surg Neurol Int* 2012;3:160.

How to cite this article: Zanaty M, Chalouhi N, Jabbour P, Starke RM, Hasan D. The unusual angiographic course of intracranial pseudoaneurysms. *Asian J Neurosurg* 2015;10:327-30.
Source of Support: Nil, **Conflict of Interest:** None declared.