

CASE REPORT

Enchondroma of the cervical spine in young woman: A rare case report

Dong Mun Jeong, Sung Hwa Paeng

Department of Neurosurgery, School of Medicine, Busan Paik Hospital, Inje University, Busan, South Korea

ABSTRACT

Enchondroma is a type of benign cartilaginous bone tumor. Enchondroma of the spine is very rare. There are only a few cases of enchondromas located in the lamina of the cervical spine have been reported. Therefore, we report a case of enchondroma in the cervical spine. A 24-year-old female patient presented with a history of neck pain, restriction of neck movement, pain and numbness along the right scapula, and weakness accompanied by wasting of the right hand. Presumptive diagnoses included bony tumors such as an aneurysmal bone cyst or a giant cell tumor. Radiologic examinations revealed a round tumor in the right lamina of C4 with extracortical extension and foramen of C4-5. C4 right hemilaminectomy and facetectomy were performed with near complete removal of the tumor. On histological examination, the tumor was confirmed to be an enchondroma. At the 6-month follow-up, a computed tomography scan showed no recurrence with good alignment.

Key words: Bone tumor, cervical spine, enchondroma, lamina

Introduction

Chondromas are benign cartilaginous tumors. These are classified as enchondromas that arise within the medullary cavity and periosteal chondromas that arise on the surface of the bone.^[1] Enchondroma is a rare benign bone tumor where it commonly involves the long tubular bones. Involvement of the spine is also rare that enchondroma of the spine has rarely been reported. To our knowledge, only 11 cases of chondromas in cervical spine have been reported in the literature since 1960 [Table 1].^[2-12] We report a case of enchondroma that was located in the right lamina of the fourth cervical vertebra in a young woman.

Case Report

A 24-year-old female patient presented with a history of neck

pain, restriction of neck movement, pain, and numbness along the medial border of the right scapula, and weakness accompanied by wasting of the right hand.

In imaging studies, a computed tomography scan revealed a lobulated marginated soft-tissue lesion measuring approximately 15 Roci mm in the right lamina of C4 with extracortical extension to the right epidural space and neural foramen of C4-5. The lesion showed widening of the right neural foramen of C4-5 and indentation to the thecal sac along calcifications. On magnetic resonance imaging, the lesion showed slightly heterogeneous signal intensity on T2-weighted images, and iso-signal intensity on T1-weighted images [Figure 1a and b]. The radiologist diagnosed a suspicious aneurysmal bone cyst or a giant cell tumor. Surgery was performed. The fascia was incised along the skin incision and the paravertebral muscles were stripped away from the spinous processes and lamina of C4 on the right side. A hard irregularly shaped tumor mass was seen. C4 right hemilaminectomy and partial facetectomy were performed. The tumor mass was almost completely removed [Figure 2a and b].

Microscopic examination revealed multiple fragmented masses that were composed of multiple cartilage islands separated by fibro-osseous septa. The tumor cells were arranged in small clusters in nodules. The chondrocytes, with bland-looking nuclei, were situated within sharp-edged lacunar spaces (inlet) [Figure 3a and b]. The histological diagnosis was enchondroma.

Access this article online	
Quick Response Code:	Website: www.asianjns.org
	DOI: 10.4103/1793-5482.162725

Address for correspondence:

Prof. Sung Hwa Paeng, Department of Neurosurgery, School of Medicine, Busan Paik Hospital, Inje University, Bok Ji Ro 75, Busanjin-Ku, Busan 614-734, South Korea.
E-mail: shpaeng@empas.com

Table 1. Published reports of cervical spine chondroma

Year	Author(s)	Sex/age	Location	Pathology	Treatment	Outcome	FU
1968	Slowik <i>et al.</i> [2]	F/10	C6-7 spinous & transverse processes	Periosteal chondroma	Complete resection, Steel wiring of C-4 & C5-T1	Resolution	3.5 year
1980	Maiuri <i>et al.</i> [3]	M/20	C2-3 transverse processes & Intervertebral foramen W/extradural extension	Periosteal chondroma	partial resection of mass C1-4 laminectomy	Normal	6 month
1982	Calderone <i>et al.</i> [4]	M/20	C-2 arch & Spinous process	Periosteal chondroma	Posterior midline for curettage of C-2 arch & spinous process	NR	NR
1986	Willis & Heilbrun [5]	M/24	Destruction of C-4 VB, partial involvement of anterior portions of C-5 & C-3 VBs	enchondroma	En bloc excision of Involved VBs, C-4, Portions of C-3 & C-5, iliac crest bone Graft, K-wires & acrylic	resolution no recurrence	1 year
1987	Lozes <i>et al.</i> [6]	F/76	Rt C4-5 intervertebral foramen W/ extradural extension	Periosteal chondroma	Anteroat piecemeal resection, partial C-5 corpectomy, acrylic prosthesis	no recurrence no spinal instability	3 year
1988	Baber <i>et al.</i> [7]	M/50	C-4& C-5 lamina & pedicles	Periosteal chondroma	En bloc resection, C3-6 laminectomy w/ sacrifice of It facet, vertebral artery, & dura	No progression of preop symptoms, no recurrence	2 year
1988	Palaoglu <i>et al.</i> [8]	M/30	Rt side of C-5 & C-6, dorsal extension into canal & anterolat into soft tissues	Periosteal chondroma	Anterolateral resection of rt-side-C5-6 tumor by curettage, up to the dura	Recurrence & reop at 1 year	NR
1992	Antic <i>et al.</i> [9]	M/28	Extradural mass extending laterally btwn arches of C-5 & C-6	Periosteal chondroma	complete resection C4-6 laminectomy	Resolution except Rt arm hemiparesis, no recurrence	2 year
1999	Shurland <i>et al.</i> [10]	F/11	C-5 lamina & transverse process	enchondroma	C-5 laminectomy, curettage, & drilling of lesion	Resolution	NR
2009	Fahim <i>et al.</i> [11]	M/6	C5-6 VB, C6 foramen	Periosteal chondroma	Complete excision C5-6 corpectomy C4-T3 lateral mass screw & pedical screw	Completely resolution of dysphagia & swallowing difficulty	3 month
2010	Russo <i>et al.</i> [12]	M/38	C4 cord compression	chondroma	C5 hemilaminectomy	No progression no recurrence	3 month
2014	Present case	F/24	C4-5 lamina Extradural extension	enchondroma	Complete excision C-4 hemilaminectomy & facetectomy	Resolution, no recurrence	3 year

FU – Follow up; NR – Not reported; VB – Vertebral body

At the 6-month follow-up, the patient reported no pain, and her numbness and motor weakness were improved. She had no neurological symptoms and no recurrence 3 years after the operation [Figure 4].

Discussion

Chondroma is a type of benign bone tumor that is a well-differentiated hyaline cartilage tumor. It occurs more frequently in patients between third and fifth decades of life.^[9] Benign cartilaginous tumors can be classified as osteochondromas, chondromas, chondroblastomas, or chondromyxoid fibromas.^[11] Chondromas are further classified as enchondromas and periosteal chondromas. Enchondromas arise within the medullary cavity, and periosteal chondromas arise on the surface of the bone.^[1] Enchondromas are frequently located in the tubular bones of the hands. Other anatomical sites are the long bones of the extremities and the ribs. Intracranial occurrence is extremely infrequent, and location in the spine is rare.^[11,13,14] Spinal chondromas may be derived from a hyperplasia of immature spinal cartilage

with migration outside the vertebral axis or from metaplasia of the connective tissue in contact with the spine or the annulus fibrosus.^[6] Enchondroma of the vertebral body with neural compression has rarely been reported.^[2,5] Enchondroma develops slowly and has a firm, elastic consistency. It is well-demarcated from adjacent structures. Progressive neurological symptoms rarely occur as a result of these tumors in the spine because of their slow growth.^[6,14] Therefore, enchondromas are frequently asymptomatic and are discovered incidentally. When they are symptomatic, spinal enchondromas present with signs of nerve root or spinal cord compression, local pain, palpable masses, and/or pathological fractures.^[1,15] For bones, enchondromas typically arise in metaphysis or diaphysis and may appear radiolucent, partially mineralized, or heavily mineralized.^[13] The pattern of mineralization is characteristic and includes a combination of rings or arcs and stippled radiodensities. The tumor is typically lobular in contour with intermediate signal intensity on T1-weighted images and high signal intensity on T2-weighted images, consistent with hyaline cartilage.^[13,16,17] In spine, calcification is rarely visible on radiographs. Local

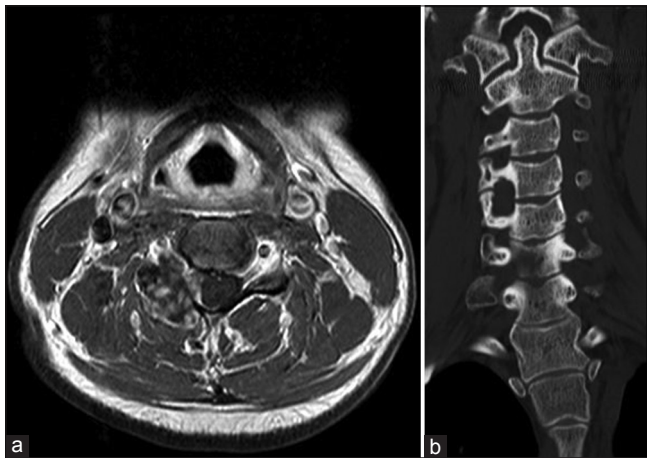


Figure 1: (a) Preoperative axial magnetic resonance imaging shows the lobulated marginated heterogeneous enhancing lesion measuring approximately 15 mm × 23 mm in the right lamina of C4, right epidural space, and neural foramen of C4-5. (b) Coronal computed tomography shows widening of the right neural foramen at C4-5

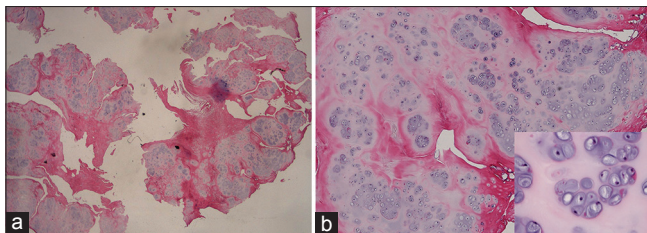


Figure 3: (a) Multiple fragmented masses are noted, composed of multiple cartilage islands separated by fibro-osseous septa (H and E, ×10). (b) The tumor cells are arranged in small clusters in nodules. The chondrocytes showing bland-looking nuclei are situated within sharp-edged lacunar spaces (inlet) (H and E, ×40, ×400 [inlet])

deformity may be present, and the neural foramen may be wide similar to our case if the tumor is intraforaminal.^[7]

The treatment of choice is excision of the tumor, preservation of vital neural and vascular structures, and maintenance of spinal stability.^[12] Surgical resection is used to establish a histologic diagnosis, prevent sarcomatous degeneration, and preserve neurologic function. Following complete resection of an enchondroma, the recurrence rate is <10%.^[1,11] Regarding adjuvant treatments for spinal enchondroma, chemotherapy is ineffective, and radiation therapy is used only for patients with tumors that are not amenable to resection or in cases where surgical margins have been histologically positive for tumor. These lesions are either only slightly responsive or resistant to radiotherapy, and the required high doses of radiation can be hazardous to adjacent nervous tissue.^[11,17] Sarcomatous degeneration is possible, but spontaneous remissions have been reported, particularly in elderly patients.^[6] Cartilage tumors present challenges in the differentiation of benign and malignant tumors through clinical symptoms or imaging studies. Surgical resection is the treatment of choice and is required for histologic diagnosis. In enchondroma, if only partial excision has been performed, close long-term follow-up

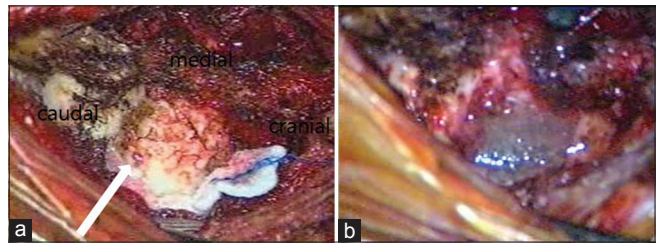


Figure 2: (a) Tumor mass of right lamina and facet joint before total resection (white arrow). (b) After total tumor resection, the tumor bed was covered with glue

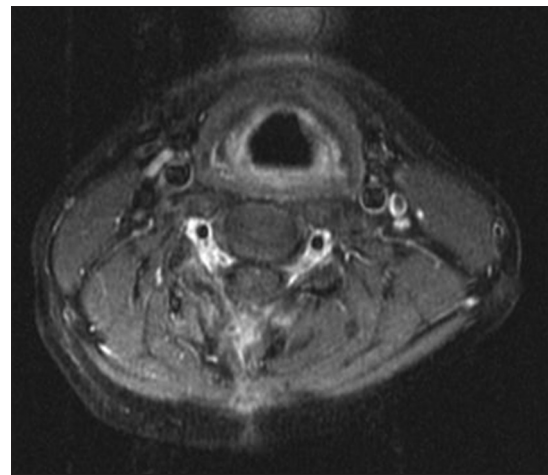


Figure 4: Follow-up magnetic resonance imaging shows no recurrence after 3 years

is mandatory due to the facts that these tumors have been known to recur. If necessary, adjuvant radiation therapy should be considered to prevent malignant change or recurrence.

Conclusion

Enchondroma involving the lamina of the cervical spine rarely occurs. In our case, the tumor was located in the lamina, and this mass invaded the area around the soft tissue and compressed the spinal cord. We initially thought that the lesion was most likely a benign bone tumor and suspected aneurysmal bone cyst or giant cell tumor. However, the pathologic diagnosis was enchondroma. The mass was most likely derived from metaplasia of the connective tissue in contact with the lamina of the spine. Furthermore, enchondromas should be best treated with an aggressive operation to prevent recurrence.

References

1. McLoughlin GS, Sciubba DM, Wolinsky JP. Chondroma/chondrosarcoma of the spine. *Neurosurg Clin N Am* 2008;19:57-63.
2. Slowik T, Bittner-Manioka M, Grochowski W. Case reports and technical notes. Chondroma of the cervical spine. Case report. *J Neurosurg* 1968;29:276-9.
3. Maiuri F, Corriero G, De Chiara A, Giamundo A, Benvenuti D, Gangemi M. Chondroma of the cervical spine: A case report. *Acta Neurol (Napoli)* 1980;2:204-8.
4. Calderone A, Naimark A, Schiller AL. Case report 196: Juxtacortical chondroma of C2. *Skeletal Radiol* 1982;8:160-3.

5. Willis BK, Heilbrun MP. Enchondroma of the cervical spine. *Neurosurgery* 1986;19:437-40.
6. Lozes G, Fawaz A, Perper H, Devos P, Benoit P, Krivosic I, *et al.* Chondroma of the cervical spine. Case report. *J Neurosurg* 1987;66:128-30.
7. Baber WW, Numaguchi Y, Kenning JA, Harkin JC. Periosteal chondroma of the cervical spine: One more cause of neural foramen enlargement. *Surg Neurol* 1988;29:149-52.
8. Palaoglu S, Akkas O, Sav A. Chondroma of the cervical spine. *Clin Neurol Neurosurg* 1988;90:253-5.
9. Antic B, Roganovic Z, Tadic R, Ilic S. Chondroma of the cervical spinal canal. Case report. *J Neurosurg Sci* 1992;36:239-41.
10. Shurland AT, Flynn JM, Heller GD, Golden JA. Tumor of the cervical spine in an 11-year-old girl [clinical clinical]. *Clin Orthop Relat Res* 1999;368:287-90;293-5.
11. Fahim DK, Johnson KK, Whitehead WE, Curry DJ, Luerssen TG, Jea A. Periosteal chondroma of the pediatric cervical spine. *J Neurosurg Pediatr* 2009;3:151-6.
12. Russo V, Platania N, Graziano F, Albanese V. Cervical spine chondroma arising from C5 right hemilamina: A rare cause of spinal cord compression. Case report and review of the literature. *J Neurosurg Sci* 2010;54:113-7.
13. Douis H, Saifuddin A. The imaging of cartilaginous bone tumours. II. Chondrosarcoma. *Skeletal Radiol* 2013;42:611-26.
14. Cetinkal A, Güven G, Topuz AK, Colak A, Demircan MN, Haholu A. Lumbar spinal chondroma presenting with radiculopathy: Case report. *Turk Neurosurg* 2008;18:397-9.
15. Singh AP, Singh AP, Mahajan S. Periosteal chondroma of the sacrum. *Can J Surg* 2008;51:E105-6.
16. Al Kaissi A, Klaushofer K, Grill F. Progressive vertebral fusion in a girl with spinal enchondromatosis. *European J Radiol Extra* 2007;63:125-9.
17. Ogata T, Miyazaki T, Morino T, Nose M, Yamamoto H. A periosteal chondroma in the lumbar spinal canal. Case report. *J Neurosurg Spine* 2007;7:454-8.

How to cite this article: Jeong DM, Paeng SH. Enchondroma of the cervical spine in young woman: A rare case report. *Asian J Neurosurg* 2015;10:334-7.
Source of Support: Nil, **Conflict of Interest:** None declared.