

CASE REPORT

Incidental frontal lobe mixed density epidermoid tumor in a patient of head injury: A rare case report

Pankaj Gupta, Radheyshyam Mittal, Ashok Gandhi, Achal Sharma, Sapna Gandhi¹

Departments of Neurosurgery and ¹Pathology, S.M.S. Medical College, Jaipur, Rajasthan, India

ABSTRACT

The incidence of the epidermoid tumor is approximately 0.2–1.8% of all intracranial tumors. Epidermoid tumors are typically intradural, but extra-axial in location and only rarely found within the brain substance. We are reporting the first case of incidental mixed density frontal epidermoid tumor in a patient of head injury. Difficulty in the preoperative diagnosis and uncommon presentation of the intracranial epidermoid tumor prompted us to report this case.

Key words: Epidermoid tumor, frontal lobe, mixed density, road traffic accident

Introduction

Intracranial epidermoids are usually congenital in origin, however, acquired lesions following trauma have been rarely reported.^[1] On reviewing the PubMed and Google databases, we found only two reported cases of incidental epidermoid tumors in patients of trauma, out of which the first tumor was located in sphenoid sinus and the second in temporal bone.^[1] For the first time in literature, Watanabe *et al.* have described the existence of mixed density epidermoid tumor.^[2] Two cases of hyperdense epidermoids following head injury have also been reported.^[3] To the best of our knowledge, we are reporting the first case of incidental mixed density epidermoid tumor of frontal lobe in a patient of head injury, with special emphasis on diagnostic difficulties, operative findings, and impact of tumor.

Case Report

A 27-year-old male patient admitted with a history of trauma due to a road traffic accident (RTA). The patient was a known case of seizure disorder since last 10 years for which he was taking treatment, but never investigated. The patient was irregular with treatment and history of

recurrent seizures was present. Regarding the mode of injury, while driving a bike he suddenly lost his control and hit a moving cart in full speed. On examination, the patient was unconscious, Glasgow Coma Scale (GCS) score was 4/15 (E1V1M2) and anisocoria was present. A lacerated wound was present over the left frontal region through which the brain matter was coming out. The patient was investigated by noncontrast computed tomography (CT) scan head [Figure 1], which showed bifrontal comminuted depressed fracture, bifrontal extradural hematoma with multiple tiny contusions and scattered pneumocephalus. A mixed density lesion was present in the right frontal region. The superficial part of the lesion was hypodense while the deeper part was hyperdense with areas of marginal calcification. The hypodense part of lesion was presumed to be some wooden foreign body, hyperdense part as hematoma, and the marginal calcifications as migrated pieces of fractured bony fragments. Patient was shifted to operation theatre and bifrontal craniotomy raised. Elevation and removal of depressed bony fragments along with evacuation of bifrontal extradural hematoma (EDH) done. Durotomy done in curvilinear fashion to deal with the right frontal lesion. Dura was firmly adhered to the underlying lesion. Grossly [Figure 2], the lesion was pearly white, encapsulated, avascular, soft, friable, greasy inconsistency, and resembling epidermoid tumor. Areas of peripheral calcification and dural infiltration by the tumor were present. Gross total excision of tumor with excision of tumor capsule was done. The part of dura infiltrated by the tumor was also excised. Thorough lavage with antibiotic mixed saline and watertight augmented duraplasty using autologous pericranial patch done. On postoperative day 1, endotracheal tube was removed after tracheostomy had been done. Initially patient showed some signs of improvement and GCS was 5/15 (E1V1M3) on postoperative day 3, but from

Access this article online

Quick Response Code:



Website:

www.asianjns.org

DOI:

10.4103/1793-5482.162726

Address for correspondence:

Dr. Pankaj Gupta, Department of Neurosurgery, S.M.S. Medical College, Jaipur - 302 004, Rajasthan, India.
E-mail: drpankaj.gupta@yahoo.co.in

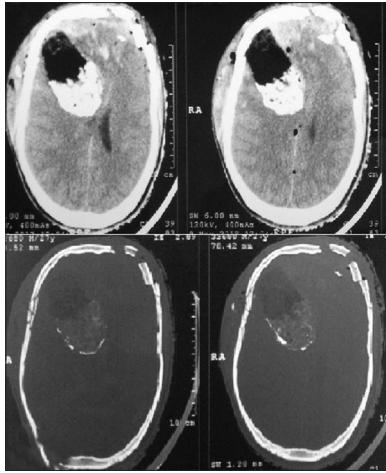


Figure 1: Noncontrast computed tomography head showing bifrontal comminuted depressed fracture with underlying extradural hematoma and subdural hematoma (L>R), multiple tiny contusions and scattered pneumocephalus. A mixed density lesion present in right frontal region whose superficial part is hypodense while the deeper part hyperdense with areas of peripheral calcification present

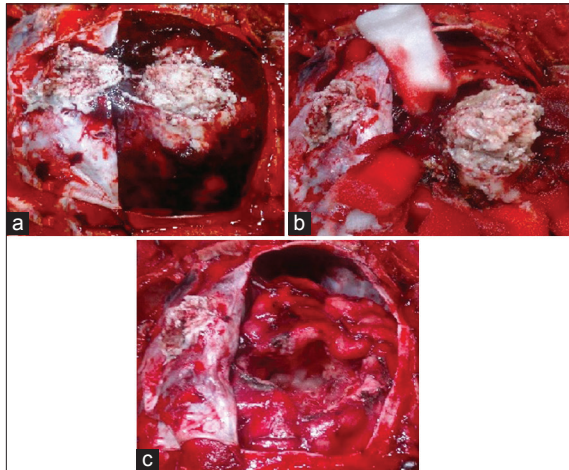


Figure 2: (a) Perioperative picture after durotomy showing right frontal epidermoid tumor which was adhered to overlying dura. (b) Tumor was dissected out of surrounding brain parenchyma. (c) After gross total excision of tumor

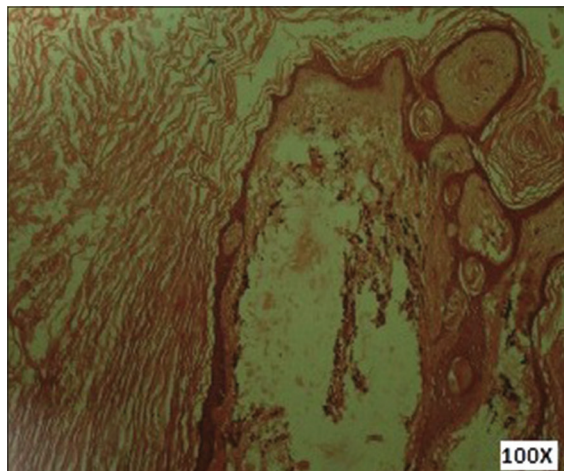


Figure 3: Photomicrograph showing epidermoid cyst lined by keratinized stratified squamous epithelium (H and E, ×100)

postoperative day 4 onwards, patient’s clinical status started deteriorating. CT chest showed evidence of gross aspiration pneumonitis, which was treated by broad spectrum antibiotics, steroids and positive pressure ventilation, but patient did not improve and finally died on postoperative day 9. The histopathological examination [Figure 3] of the right frontal lesion was diagnostic of Epidermoid tumor.

Discussion

As a result of the slow growth and benign nature of the epidermoid cyst, signs and symptoms manifest years after growth. Epidermoid presenting with seizure is extremely rare and occurs either due to direct cerebral compression by expanding cyst or cyst rupture.^[1,4-6] In our case, epidermoid induced seizure was the possible cause of RTA.

Hasegawa *et al.*^[5] and Tekkök *et al.*^[7] reviewed the literature and found a total of thirteen reported cases of CT-hyperdense epidermoid tumors. Ten of these cases were posterior fossa epidermoids. Four more hyperdense epidermoids have been reported in corpus callosum, midline posterior fossa and CP angle. Braun *et al.*^[6] reported three cases of hyperdense epidermoid and suggested that the keratinized debris and its saponification to calcium soap was the cause of the homogeneous hyperdensity of these masses. Various other authors have attributed high protein concentration as the cause of hyperdensity in these cases.^[5,8] Tekkök *et al.*^[7] however, reported that abundance of polymorphonuclear leukocytes contributed to hyperdensity. There are only two reports of the spontaneous hemorrhage as the cause of hyperdensity of intracranial epidermoid on CT scan.^[3] Hasegawa *et al.*^[5] suggested that hemorrhage occurs continuously or intermittently from the small fibrous nodules containing numerous vessels, which lead to hemosiderin deposits in the cells; and that was the cause of hyperdensity on CT scan. Two cases of hyperdense epidermoids following head injury have been reported in literature.^[3,9] Abou-Samara *et al.*^[9] reported a case of frontal epidermoid along with a large subacute EDH following minor head injury. A mixed density epidermoid attached to dura of frontal convexity extending into cerebral parenchyma with enhancing capsule was reported by Watanabe *et al.*^[2] We are reporting the first case of incidental mixed density frontal epidermoid tumor in a patient of trauma.

Surgical excision is the mainstay of treatment, and is low-risk due to the avascular nature of the tumor.^[1,9] There are two school of thoughts in management of incidental tumor with coexisting trauma. Firstly, deal with the trauma part in the form of decompressive surgery as an emergency procedure if patient’s clinical condition is low and later the tumor part as an elective procedure in second look surgery. The secondly, deal with both the tumor part as well as trauma part in single stage surgery if we have the facilities in emergency operation theatre. In our case, since the primary cause of trauma was epidermoid

induced seizure and the tumor was sizeable producing mass effect, tumor capsule was ruptured with spillage of contents, therefore tumor had been dealt with trauma surgery to provide effective decompression and to minimize the risk of postoperative seizures even if the GCS of patient was poor. The capsule of the cyst can be problematic in these cases as it may be adherent to vital structures and may need to be left behind. A unique postoperative complication associated with excision of epidermoids is aseptic/chemical meningitis due of spillage of contents of a cyst in subarachnoid space.^[6] Peri-operative thorough lavage and postoperative steroids administration are useful in the treatment of meningitis.^[1,6] The overall prognosis of the epidermoid tumor is excellent, but in patients of co-incidental head injury, it is guarded.

Conclusion

Incidental mixed density epidermoid tumor is rarely found in the frontal lobe. They might present with headache or seizure-induced trauma. A high index of suspicion is required to diagnose such type of cases. Surgical resection is the mainstay of treatment, and prevention of chemical meningitis should be considered in the postoperative period. The overall prognosis of a patient of head injury with the incidental epidermoid tumor is worse.

References

1. Hewitt DK, Kinney WC. Two cases of incidental epidermoid cysts: Sphenoid sinus and temporal bone. *Ear Nose Throat J* 2006;85:825-8.
2. Watanabe K, Wakai S, Nagai M, Muramatsu H. Epidermoid tumor with unusual CT and MR findings - Case report. *Neurol Med Chir (Tokyo)* 1990;30:977-9.
3. Barnett FC, Barnett JC Jr. Massive bifrontal epidermoid tumor. *Surg Neurol* 1992;38:437-40.
4. Qayoom Khan HA, Sobani ZA, Siddiqui AA. Epidermoid cysts in frontal lobe: A case series. *J Pak Med Stud* 2011;1:95-9.
5. Hasegawa H, Bitoh S, Nakata M, Fujiwara M, Yasuda H. Intracranial epidermoid mimicking meningioma. *Surg Neurol* 1981;15:372-4.
6. Braun IF, Naidich TP, Leeds NE, Koslow M, Zimmerman HM, Chase NE. Dense intracranial epidermoid tumors. Computed tomographic observations. *Radiology* 1977;122:717-9.
7. Tekkök IH, Cataltepe O, Saglam S. Dense epidermoid cyst of the cerebellopontine angle. *Neuroradiology* 1991;33:255-7.
8. Hao S, Tang J, Wu Z, Zhang L, Zhang J, Wang Z. Natural malignant transformation of an intracranial epidermoid cyst. *J Formos Med Assoc* 2010;109:390-6.
9. Abou-Samra M, Marlin AE, Story JL. Cranial epidermoid tumor associated with subacute extradural hematoma. Case report. *J Neurosurg* 1980;53:574-5.

How to cite this article: Gupta P, Mittal R, Gandhi A, Sharma A, Gandhi S. Incidental frontal lobe mixed density epidermoid tumor in a patient of head injury: A rare case report. *Asian J Neurosurg* 2015;10:338-40.

Source of Support: Nil, **Conflict of Interest:** None declared.