

## CASE REPORT

# A rare case of neurofibromatosis – type 1

Prithvi Varghese, Muhammed Jasim Abdul Jalal<sup>1</sup>Departments of Neurosurgery and <sup>1</sup>Family Medicine, Lakeshore Hospital and Research Centre, Ernakulam, Kerala, India

## ABSTRACT

Neurofibromatosis type 1 (NF1), also known as von Recklinghausen disease, is an autosomal dominant familial tumor syndrome. Glioblastoma is a malignant brain tumor but is a rare occurrence in patients with NF1. Here, we report a rare occurrence of glioblastoma in a 60-year-old man with NF1, who presented with headache, neck pain, and gait unsteadiness of 3 days duration. He also had postural hypotension. Motor examination revealed left hemiparesis. Multiple subcutaneous soft swellings and multiple café-au-lait spots were seen all over his body. He also had inguinal and axillary freckling. Abdominal imaging revealed a right suprarenal mass suggestive of cystic pheochromocytoma. Brain imaging revealed a predominantly cystic intra-axial right frontal space occupying lesion (SOL) with enhancing solid component, perilesional edema, and mass effect. The patient underwent laparoscopic removal of right adrenal mass after being adequately “blocked” by an alpha blocker-prazosin. Thereafter, he underwent right frontal craniotomy and gross total excision of right frontal infiltrative SOL. The postoperative period was uneventful. Patient underwent adjuvant radiotherapy and chemotherapy.

**Key words:** Glioblastoma multiforme, neurofibromatosis type 1, pheochromocytoma

## Introduction

Neurofibromatosis type 1 (NF1), also known as von Recklinghausen disease, is an autosomal dominant familial tumor syndrome. The incidence of NF1 is about 1 in 3,500 individuals.<sup>[1]</sup> Low-grade gliomas involving the optic pathway and brainstem are the most common central nervous system neoplasms in patients with NF1.<sup>[2,3]</sup> Glioblastoma is a common malignant brain tumor in adults but is a rare occurrence in patients with NF1. We report a rare occurrence of glioblastoma in a 60-year-old man with NF1.

## Case Report

A 60-year-old Indian diabetic male presented with headache, neck pain, and gait unsteadiness of 3 days duration. On examination, the patient had postural hypotension. Motor examination revealed left hemiparesis. Multiple subcutaneous

soft swellings (most of them pedunculated) along with multiple café-au-lait spots were seen all over his body, including the scalp [Figure 1]. He also had inguinal and axillary freckling. Ophthalmologic examination was normal. The patient had no bone lesions. There was no family history of neurofibromatosis. Abdominal imaging showed a well-defined cystic lesion in the right adrenal gland with multiple enhancing septations and solid areas with hemorrhage, suggestive of cystic pheochromocytoma.

Computed tomography (CT)-brain showed a variegated space occupying lesion (SOL) in the right-frontal-lobe with a large cystic component and an enhancing solid component. Moderate surrounding edema was noticed with mass effect and midline shift to left. Magnetic resonance imaging (MRI)-brain [Figure 2] confirmed a predominantly cystic intra-axial right-frontal-SOL with enhancing solid component, perilesional edema, and mass effect.

Postural hypotension, elevation of 24 h urinary catecholamines [Table 1], and the findings on abdominal imaging were diagnostic of pheochromocytoma. The patient was adequately blocked with prazosin (starting with 1 mg daily, which was increased to 8 mg daily over a period of 5 days, all the while monitoring his blood pressure and heart rate). There was no need for beta-blocker. The patient was adequately hydrated and liberal salt intake was encouraged to prevent any episodes of hypotension. Thereafter, the patient underwent laparoscopic right adrenalectomy. Histopathology was consistent with pheochromocytoma. After 5 days, he underwent right-frontal-craniotomy and gross total excision of right frontal infiltrative SOL. Histopathology

### Access this article online

#### Quick Response Code:



#### Website:

www.asianjns.org

#### DOI:

10.4103/1793-5482.162728

### Address for correspondence:

Dr. Muhammed Jasim Abdul Jalal, Department of Family Medicine, Lakeshore Hospital and Research Centre, NH-47 Bypass, Maradu, Nettoor P.O., Ernakulam - 682 040, Kerala, India.  
E-mail: jasimabduljalal@yahoo.com

of the intracranial-SOL was consistent with glioblastoma multiforme (GBM) (WHO grade IV) [Figure 3].

The postoperative period was uneventful. The hemiparesis improved. The immediate postoperative CT-brain [Figure 2] confirmed gross total excision of the right-frontal-intracranial-SOL and resolution of the mass effect. Patient underwent adjunctive radiotherapy and chemotherapy with oral-temozolomide.

### Discussion

Neurofibromatosis type 1 was first described by the German pathologist Friederich Daniel von Recklinghausen in 1882. It is the most common neurocutaneous syndrome. Diagnosis of NF1 is based on the presence of at least two of the seven criteria established by the National Institute of Health (NIH) Consensus Development Conference in 1988 [Table 2].

Mutations of the NF1-gene (a tumor-suppressor-gene) located on chromosome 17q11.2, partly explains the clinical susceptibility for malignancies.<sup>[4]</sup> The NF1-gene product neurofibromin functions in part as a negative regulator of the p21 Ras proto-oncogene by accelerating the conversion of active guanosine triphosphate bound Ras to its inactive guanosine diphosphate bound form. Active Ras, as a result of reduced or absent neurofibromin expression, lead to increased cell growth and facilitates tumor formation.

Molecular analysis of GBMs arising in NF1-patients showed the presence of genetic alterations such as p16INK4A/ARF deletions and p53 mutations.<sup>[5]</sup> These alterations are believed to cooperate with NF1 in the development of malignant astrocytomas.

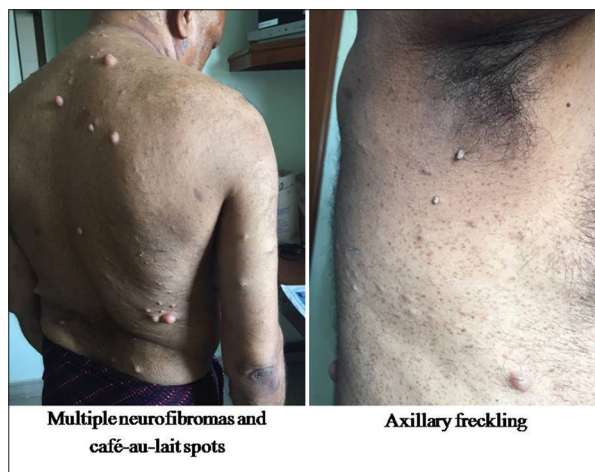**Table 1: 4-hour urinary catecholamines**

Catecholamine	Result	Unit	Reference interval
Epinephrine	20.35	µg/g Creat	1.30-10.70
Norepinephrine	153.64	µg/g Creat	8.90-61.60
Dopamine	506.37	µg/g Creat	40.00-390.00

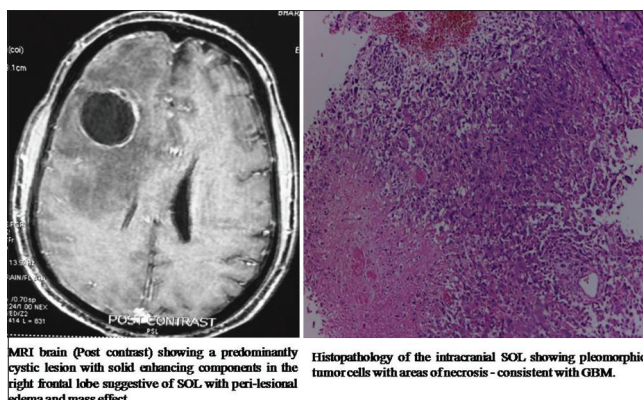
**Table 2: Diagnostic criteria for type 1 neurofibromatosis. (Two or more of the following criteria are required)**

- Six or more café-au-lait spots with the following diameter:
  - ≥5 mm before puberty
  - ≥15 mm after puberty
- Two or more neurofibromas of any type or one plexiform neurofibroma
- Axillary or inguinal freckling (cowden syndrome)
- Optic pathway glioma
- Two or more Lisch nodules (benign hamartomas of the iris)
- Typical bone lesions
  - Sphenoid dysplasia
  - Dysplasia or thinning of long bone cortex (pseudarthrosis)
- First-degree relatives with NF1

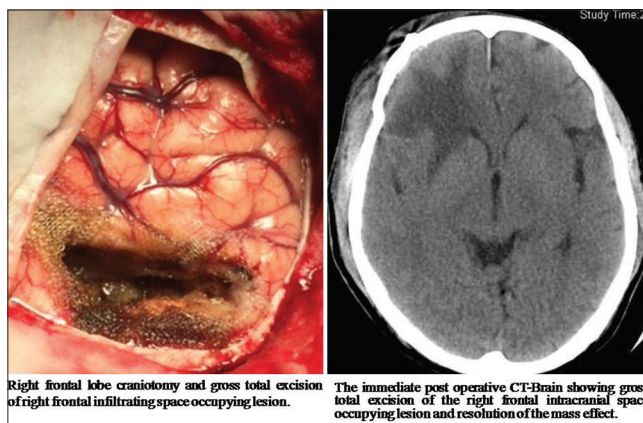
Zhu *et al.* reported that in their mouse model with NF1 and simultaneous loss of p53, most tumors arose in the vicinity of the subventricular zone (SVZ), where the majority of neural precursor cells reside.<sup>[6]</sup> This indicates:



**Figure 1:** Multiple neurofibromas, café-au-lait spots and axillary freckling



**Figure 2:** Right frontal lobe craniotomy with gross total excision of right frontal space occupying lesion (SOL) and the immediate postoperative computed tomography brain showing gross total excision of the right frontal SOL with resolution of the mass effect



**Figure 3:** Magnetic resonance imaging brain (postcontrast) and histopathology suggestive of glioblastoma multiforme

**Table 3: Reported cases of Glioblastoma Multiforme in Neurofibromatosis type 1 in adults<sup>[7-10]</sup>**

Authors	Year	Age (years)/sex	Location (lesion)	Treatment	Post-treatment course
Pál <i>et al.</i> <sup>[7]</sup>	2001	37/female	Occipital	No treatment	No treatment
Hakan and Aker <sup>[8]</sup>	2008	28/female	Frontal	Surgery, Radiotherapy, Chemotherapy (temozolamide)	Died 41 months after surgery
Broekman <i>et al.</i> <sup>[9]</sup>	2009	28/female	Cerebellum	Surgery, Radiotherapy, Chemotherapy	Died 6 months after surgery
TS Jeong <i>et al.</i> <sup>[10]</sup>	2014	32/male	Frontal	Surgery, Radiotherapy, Chemotherapy	Alive
Present case	2015	60/male	Frontal	Surgery, Radiotherapy, Chemotherapy	Alive

- Cells in this region of the brain are more susceptible to p53/NF1-mediated tumor formation
- The micromilieu of the SVZ is more advantageous to the growth of brain tumor precursor cells.

Very few cases of NF1 associated with glioblastoma had been reported [Table 3]. In 2001, Pal *et al.* reported the case of a 37-year-old woman with a progressive course of multiple sclerosis, who presented with cutaneous neurofibromatosis.<sup>[7]</sup> Unexpectedly, autopsy revealed a right-hemispheric-occipital glioblastoma which was silent during her lifetime.

In 2008, Hakan and Aker described a case of a lobar cystic glioblastoma and NF1 in a 28-year-old woman.<sup>[8]</sup> She underwent glioblastoma resection, followed by radiotherapy and chemotherapy. The patient survived for another 41 months.

In 2009, Broekman *et al.* reported a 28-year-old woman with NF1, who was regularly on follow-up for a cerebellar lesion, suspected to be a hamartoma.<sup>[9]</sup> This lesion was accidentally discovered in her at the age of 21 during a radiological exam performed for a facial neurofibroma. Further evaluation followed by neurosurgical resection revealed it to be a cerebellar-GBM. Following surgery, the patient underwent both radiotherapy and chemotherapy. Six months later, MRI-brain showed progression of the tumor. She developed metastases in the right-frontal-lobe and spine after another 6 months. The patient died shortly thereafter.

In 2014, Jeong and Yee reported a 32-year-old male, who presented with headache and radiological studies showing a high grade intra-axial tumor.<sup>[10]</sup> The patient underwent gross total surgical excision and the pathology revealed glioblastoma. He received standard concomitant chemoradiotherapy followed by adjuvant chemotherapy with temozolomide. After finishing six cycles of adjuvant chemotherapy, the patient showed no remarkable symptoms and follow-up MRI obtained 9 months after surgery did not show any evidence of recurrence.

In 2010, Huttner *et al.* reviewed five children with NF1 and GBM and reported their clinicopathologic features.<sup>[11]</sup> They provided that the survival of glioblastoma patient with NF1 was better than those without NF1. The overall median survival of patients with and without NF1 was 9.25 and 1.08 years, respectively.

## Conclusion

Neurofibromatosis type 1 was clinically diagnosable in the case presented here as the patient had three of the seven criteria given by NIH Consensus Development Conference in 1988. In addition, the patient was found to have GBM. The characteristics of this single case suggest that brain lesions in NF1-patients should be closely monitored for the potential development of high-grade astrocytomas. People with NF1 should be screened for the development of intracranial-SOL on a periodical basis (annually).

## Acknowledgments

I would like to express my sincere gratitude to Dr. H. Ramesh (Senior Consultant Gastrosurgeon, Lakeshore Hospital and Research Centre), Dr. Ramesh Gomez (Endocrinologist, Lakeshore Hospital and Research Centre), Dr. Sarah Kuruvila (Pathologist, Lakeshore Hospital and Research Centre) and Dr. Thomas Cherian (Pathologist, Lakeshore Hospital and Research Centre) for guiding me in this endeavor.

## References

1. Friedman JM. Epidemiology of neurofibromatosis type 1. *Am J Med Genet* 1999;89:1-6.
2. Blatt J, Jaffe R, Deutsch M, Adkins JC. Neurofibromatosis and childhood tumors. *Cancer* 1986;57:1225-9.
3. Korf BR. Malignancy in neurofibromatosis type 1. *Oncologist* 2000;5:477-85.
4. Wallace MR, Marchuk DA, Andersen LB, Letcher R, Odeh HM, Saulino AM, *et al.* Type 1 neurofibromatosis gene: Identification of a large transcript disrupted in three NF1 patients. *Science* 1990;249:181-6.
5. Gutmann DH, James CD, Poyhonen M, Louis DN, Ferner R, Guha A, *et al.* Molecular analysis of astrocytomas presenting after age 10 in individuals with NF1. *Neurology* 2003;61:1397-400.

6. Zhu Y, Guignard F, Zhao D, Liu L, Burns DK, Mason RP, *et al.* Early inactivation of p53 tumor suppressor gene cooperating with NF1 loss induces malignant astrocytoma. *Cancer Cell* 2005;8:119-30.
7. Pál E, Gömöri E E, Gáti I. Neurofibromatosis and glioblastoma in a case of multiple sclerosis. *Eur J Neurol* 2001;8:717-8.
8. Hakan T, Aker FV. Case report on a patient with neurofibromatosis type I and a frontal cystic glioblastoma. *Neurol Neurochir Pol* 2008;42:362-5.
9. Broekman ML, Risselada R, Engelen-Lee J, Spliet WG, Verweij BH. Glioblastoma multiforme in the posterior cranial fossa in a patient with neurofibromatosis type I. *Case Rep Med* 2009;2009:757898.
10. Jeong TS, Yee GT. Glioblastoma in a patient with neurofibromatosis type 1: A case report and review of the literature. *Brain Tumor Res Treat* 2014;2:36-8.
11. Huttner AJ, Kieran MW, Yao X, Cruz L, Ladner J, Quayle K, *et al.* Clinicopathologic study of glioblastoma in children with neurofibromatosis type 1. *Pediatr Blood Cancer* 2010;54:890-6.

**How to cite this article:** Varghese P, Abdul Jalal MJ. A rare case of neurofibromatosis - type 1. *Asian J Neurosurg* 2015;10:344-7.  
**Source of Support:** Nil, **Conflict of Interest:** None declared.