

## CASE REPORT

# “Giant” terminal myelocystocele: A rare variant of spinal dysraphism

Sumit Bansal, Ashok Kumar Mahapatra

Department of Neurosurgery, All India Institute of Medical Sciences, Bhubaneswar, Odisha, India

## ABSTRACT

Terminal myelocystocele (TMC) is a rare form of spinal dysraphism. They constitute approximately 5% of skin covered lumbosacral masses. The TMC is composed of a low-lying conus medullaris with cystic dilatation of caudal central canal and a surrounding meningocele that extends from the conus to the skin. A 2-year-old female child presented with a large lumbosacral mass and weakness of both lower limbs since birth. Magnetic resonance imaging revealed a giant TMC. The child was operated on successfully. This is an interesting and rare case of “giant” TMC with partial sacral agenesis.

**Key words:** Giant terminal myelocystocele, good outcome, sacral agenesis, spinal dysraphism, surgery

## Introduction

Terminal myelocystocele (TMC) constitute approximately 5% of skin covered lumbosacral masses.<sup>[1]</sup> They are defined as spinal dysraphism with a localized, cystic dilatation of the central canal of the spinal cord herniated posteriorly through spina bifida. TMC can be associated with anomalies of the anorectal system, lower genitourinary system, and vertebrae.<sup>[2]</sup> Here, we present an interesting case of “giant” TMC, only rarely reported in the literature.<sup>[2,3]</sup>

## Case Report

A 2-year-old female child, presented with a progressively increasing lumbosacral swelling, present since birth. The patient had weakness in both lower limbs (MRC Grade = 3/5). No obvious history of dribbling or urinary incontinence was present. On physical examination, there was a lumbosacral mass measuring 15 cm × 10 cm × 10 cm in size with overlying irregular and unhealthy skin covering [Figure 1]. The head circumference was 52 cm, and

the anterior fontanelle was lax. The anterior abdominal wall and the genitalia were normal.

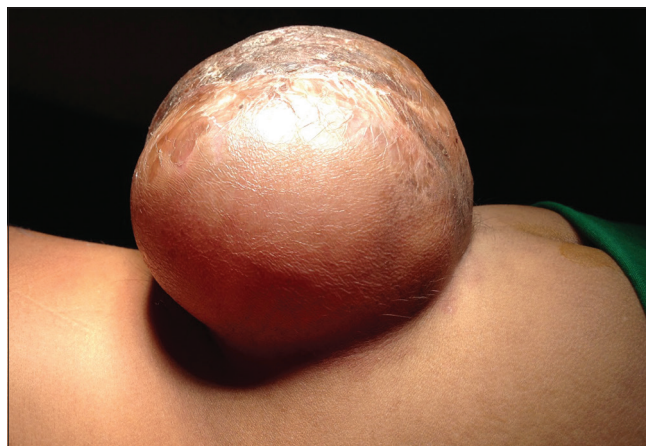Magnetic resonance imaging (MRI) revealed a giant TMC, which contained a trumpet like flaring of the central canal of the distal spinal cord and a meningocele located around the dilated central canal, which bulged into the subcutaneous region [Figure 2a and 2b]. MRI brain showed hydrocephalus with corpus callosum agenesis [Figure 2c].

The patient was operated, and a vertical incision was made in the midline and about 250 ml cerebrospinal fluid drained. There was an external cyst and another small cyst was found connected to the central canal. Due to the absence of posterior elements of the sacrum, nerve roots were seen traversing through the posterior wall of the inner cyst. Caudal portion of trumpet shaped myelocystocele sparing nerve roots was resected, and the remaining base was repaired using 4.0-vicryl

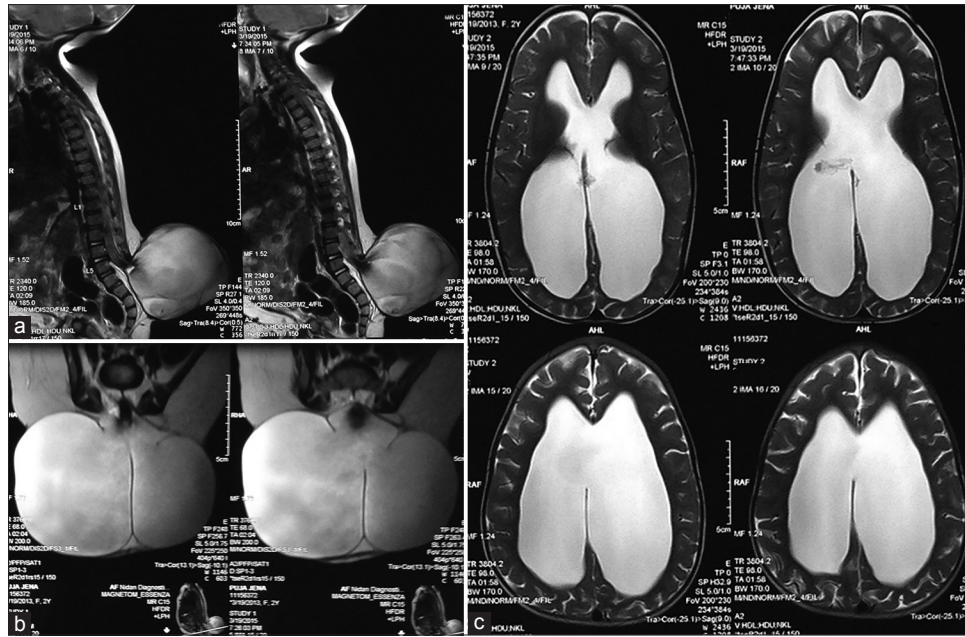
Access this article online	
Quick Response Code:	Website: www.asianjns.org
	DOI: 10.4103/1793-5482.162730

### Address for correspondence:

Dr. Sumit Bansal, Department of Neurosurgery, All India Institute of Medical Sciences, Bhubaneswar - 751 019, Odisha, India.  
E-mail: drsumitbansal@gmail.com



**Figure 1:** Preoperative image showing a large lumbosacral skin covered mass



**Figure 2:** Lumbo-sacral magnetic resonance imaging (MRI) - T2-weighted sagittal (a) and an axial (b) section showing giant terminal myelocystocele. Brain MRI showing hydrocephalus with corpus callosum agenesis (c)

sutures. The child recovered well with no new postoperative neurological deficits [Figure 3].

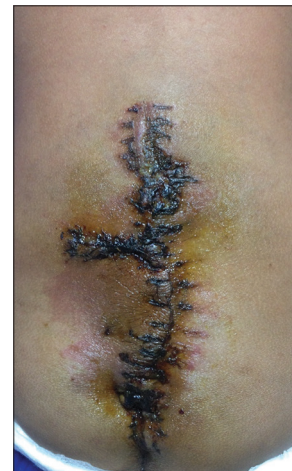## Discussion

Terminal myelocystocele constitutes 4–8% of lumbo-sacral occult spinal dysraphism.<sup>[4-6]</sup> The TMC is composed of a low-lying conus medullaris with cystic dilatation of caudal central canal, a surrounding meningocele. The terminal cyst is lined with ependymal and dysplastic glia and does not communicate with the subarachnoid space.

Epidemiologically, myelocystocele arises sporadically; there is no known familial incidence or sex preponderance has been described.<sup>[7]</sup> Myelocystocele have been described as terminal or nonterminal and reported in cervical, thoracic, and lumbo-sacral regions. Cervical myelocystocele is infrequently associated with neurological deficit whereas TMC is considered to have more neurological problems.<sup>[8]</sup>

The majority of children presented with a skin covered mass at the lower back. Midline abdominal and pelvic anomalies often accompany the TMCs. This constellation of abnormalities is best represented by the acronym "OEIS" a complex including an omphalocele defect, exstrophy of the bladder, imperforate anus, and spinal abnormalities.<sup>[9]</sup>

As per Pang's hypothesis,<sup>[10]</sup> the core structure of TMC strikingly resembles a transitory stage of late secondary neurulation in chicks in which the cerebrospinal fluid-filled bleb like distal neural tube bulges dorsally to fuse with the surface ectoderm before focal apoptosis detaches it from the surface and undertakes its final dissolution. TMC results



**Figure 3:** Postoperative image showing healed wound

from a time specific paralysis of apoptosis just before the dehiscence of the cystic distal cord from the future skin, thereby preserving the embryonic state. "Giant" variant of TMC was not described by Pang *et al.*<sup>[10]</sup> but reported by others.<sup>[2,3]</sup>

Magnetic resonance imaging is characterized by a "trumpet like" flaring of the distal cord central canal into an ependymal lined terminal cyst. Abnormalities of the vertebral column may occur and include lordosis, scoliosis, and agenesis of the sacral parts.<sup>[2]</sup> Many newborns with TMC have no neurological deficits but develop them with age.<sup>[10]</sup> TMC should be repaired within the first few months of life or once the diagnosis is made regardless of whether there are preexisting deficits.

## Conclusion

Surgical correction of myelocystocele is not only for cosmetic reasons but also to untether the spinal cord prophylactically to prevent future neurological deterioration. TMC should be included in the differential diagnosis of congenital lesions presenting as a lumbosacral mass.

## References

1. McLone DG, Naidich TP. Terminal myelocystocele. *Neurosurgery* 1985;16:36-43.
2. Gupta DK, Ramdurg S, Mahapatra AK. Giant terminal lipomyelocystocele. *Pediatr Neurosurg* 2006;42:49-53.
3. Ramdurg SR, Rajshekhar SJ, Dubey S, Odugoudar AR. A rare case of giant terminal lipomyelocystocele with partial sacral agenesis. *J Pediatr Neurosci* 2013;8:52-4.
4. Jaiswal AK, Mahapatra AK. Terminal myelocystocele. *J Clin Neurosci* 2005;12:249-52.
5. Tandon V, Garg K, Mahapatra AK. Terminal myelocystocele: A series of 30 cases and review of the literature. *Pediatr Neurosurg* 2012;48:229-35.
6. Gupta DK, Mahapatra AK. Terminal myelocystoceles: A series of 17 cases. *J Neurosurg* 2005;103:344-52.
7. Pang D. Sacral agenesis and caudal spinal cord malformations. *Neurosurgery* 1993;32:755-78.
8. Ochiai H, Kawano H, Miyaoka R, Nagano R, Kohno K, Nishiguchi T, *et al.* Cervical (non-terminal) myelocystocele associated with rapidly progressive hydrocephalus and Chiari type II malformation – Case report. *Neurol Med Chir (Tokyo)* 2010;50:174-7.
9. Kumar R, Chandra A. Terminal myelocystocele. *Indian J Pediatr* 2002;69:1083-6.
10. Pang D, Zovickian J, Lee JY, Moes GS, Wang KC. Terminal myelocystocele: Surgical observations and theory of embryogenesis. *Neurosurgery* 2012;70:1383-404.

**How to cite this article:** Bansal S, Mahapatra AK. "Giant" terminal myelocystocele: A rare variant of spinal dysraphism. *Asian J Neurosurg* 2015;10:350-2.  
**Source of Support:** Nil, **Conflict of Interest:** None declared.