

Relationship between demography, etiology, level of consciousness, and outcome of surgical intracranial suppurations of bacterial origin in a tropical tertiary center

Olufemi Emmanuel Idowu, Adetinuwe Adesunlola Majekodunmi¹

Departments of Surgery, Neurosurgery Division, and ¹Anaesthesia, Lagos State University College of Medicine and Lagos State University Teaching Hospital, Ikeja, Lagos, Nigeria

ABSTRACT

Introduction: Intracranial suppurations (ICS) of bacterial origin are associated with significant mortality and morbidity. This study aimed to review demography, etiology, level of consciousness, and outcome of surgical ICS in a tropical tertiary hospital.

Materials and Methods: All patients admitted to the neurosurgical unit within the study period of 7 years that had a surgical intervention for their ICS were prospectively included in the study. In accordance with the unit protocol, all patients in whom there was clinical suspicion of ICS had a preoperative computed tomography scan and/or magnetic resonance imaging done. The following data among others were documented and recorded electronically: demography, clinical and radiological diagnosis, etiology of ICS, admission Glasgow Coma Scale (GCS) score, type of neurosurgical intervention, mode of anesthesia, and outcome.

Results: Forty-nine patients were included in the study. There were 33 males with a male-to-female ratio of 2.1:1. All patients presented at least a week after the use of antibiotics. The most common type of ICS was cerebral abscess (33 patients, 67.3%). There was no statistical significant association between outcome and age group ($P = 0.630$), gender ($P = 0.999$), diagnosis ($P = 0.464$), etiology of ICS ($P = 0.169$), solitary or multiplicity of ICS ($P = 0.485$), or type of offending organism ($P = 0.278$).

Conclusions: ICS usually follows otorhinological infections in our center. The surgical outcome is dependent on the admission GCS score.

Key words: Brain abscess, epidural abscess, intracranial suppuration, subdural empyema

Introduction

Intracranial suppurations (ICS) of bacterial origin are relatively uncommon neurosurgical emergencies. These life-threatening

diseases include epidural abscesses, subdural empyemas, and brain abscesses. They have been a scourge through the ages and attempts at curative surgery are considered to be one of the first true neurosurgical interventions performed.^[1] Their management entails a swift diagnosis and urgent surgical intervention to avert death and ensure a good functional neurologic outcome.

These disease can result by direct spread from contiguous foci (otitis media, sinusitis, dental infection, osteomyelitis), penetrating cranial trauma, postneurosurgical procedures, hematogenous spread (suppurative lung abscess, cyanotic congenital heart disease, bacteria endocarditis), and cryptogenic causes.^[2] ICS following otorhinological infections are said to be uncommon in the age of antibiotics and the developed world.^[3] It has been observed that the prevalence of brain abscess is higher in immunocompromised individuals than in those with normal immune function, as the virulence

Access this article online	
Quick Response Code:	Website: www.asianjns.org
	DOI: 10.4103/1793-5482.165798

Address for correspondence:

Dr. Olufemi Emmanuel Idowu, Department of Surgery, Lagos State University College of Medicine and Lagos State University Teaching Hospital, Ikeja, Lagos, Nigeria.
E-mail: oeidowu412@yahoo.com

of the organism and the resistance of the host influence the outcome of this condition significantly.^[4,5] With the rise in the abuse of intravenous drug use and immunocompromised patients, the incidence of these infections may even be on the increase, making their successful management even more challenging in this already compromised patient population.

There has been a limited study on the profile and management of this condition in the present era in the tropics. Considering the peculiarities of a developing country where late hospital presentation is common in addition to deficiency of appropriate personnel and facility, it is pertinent to examine the current profile and outcome of surgical ICS.

The purpose of this study was to review the demography, etiology, level of consciousness, and outcome of surgical ICS in the tropics, using our institution as a stereotype tertiary neurosurgical center in the tropics.

Materials and Methods

The study is a prospective study of our patients with bacterial ICS treated surgically at the Lagos State University Teaching Hospital, Ikeja, Lagos, Nigeria; this was carried out over a 7-year period (August 2006–July 2013). The unit is a neurosurgical center for both adults and pediatric cases and is one of the 2 reference centers for a population of about 15 million people.

All patients admitted to the Neurosurgical unit within the study period that had a surgical intervention for their ICS were included in the study. Patients not treated surgically were excluded. All patients had a detailed clinical history and a thorough physical examination. The level of consciousness was assessed using the standard Glasgow Coma Scale (GCS). In accordance with our unit protocol, all patients in whom there was clinical suspicion of intracranial sepsis had a brain computed tomography scan and/or a magnetic resonance imaging done on admission. Laboratory tests included full blood count, electrolytes, urea and creatinine, erythrocyte sedimentation rate (prior and after surgery), C-reactive protein (pre and postsurgery), and aspirate microscopy cultures and sensitivity. Patients were commenced on intravenous ceftazidime while awaiting results of the microbiological test. The outcome of surgical management was assessed 3 months after surgery using the 5 - scale GC outcome score (GOS); where 1 - dead, 2 - persistent vegetative state (patient exhibits no obvious cortical function), 3 - severe disability (conscious but disabled and dependent), 4 - moderate disability (disabled but independent as far as daily life is concerned), 5 - good recovery (resumption of normal activities even though there may be minor neurological or psychological deficits).

The following patient's data were documented electronically: age and sex, clinical and radiological diagnosis, etiology of ICS, admission GCS score, type of neurosurgical intervention,

mode of anesthesia (general or local anesthesia with monitored conscious sedation), organism isolated from culture and GOS. Patients were also grouped according to their ages and with respect to the etiology of ICS (traumatic, otogenic, sinusogenic, pulmonary, cardiac, odontogenic, postneurosurgical procedures, or cryptogenic, where the source of the ICS could not be identified).

We compared groups using Chi-square, Fisher exact test, and *t*-test as appropriate. Significance was judged at $P < 0.05$ level. The data were computed and analyzed using the Statistical Package for Social Sciences version 17 statistical software (SPSS Inc., Chicago, IL, USA).

Results

A total of 49 cases were seen within the study period. Of these cases, 33 were males, giving a male: female ratio of 2.1:1. The mean age was 17.4 years (median 12 years, range of 6 weeks to 78 years). The peak age groups were 0–9 and 10–19 years [Figure 1]; these accounted for 42.9 and 30.6%, respectively. None of the patients had a history of intravenous drug use abuse or human immunodeficiency viral infection. All of the patients had prior use of antibiotics for at least 1 week before presentation. The most common type of ICS was cerebral abscess (33 patients, 67.3%) [Table 1] and the most common etiology was otogenic in 16 (32.7%) and sinusitis in 14 patients (28.6%) [Table 2]. Eight of the patients had Pott's puffy tumor.

A positive culture from the purulent aspirate was present in 28 cases (57.1%). The most common organism isolated were streptococcus pneumoniae (10, 20.4%) and streptococcus milleri (6, 12.2%). Three patients died giving a mortality rate of 6.1%. Of the three patients that died, 2 had Pott's puffy tumor, and one patient had cerebral abscess.

The organisms were isolated in 28 samples (57.1%) obtained at surgery [Table 3].

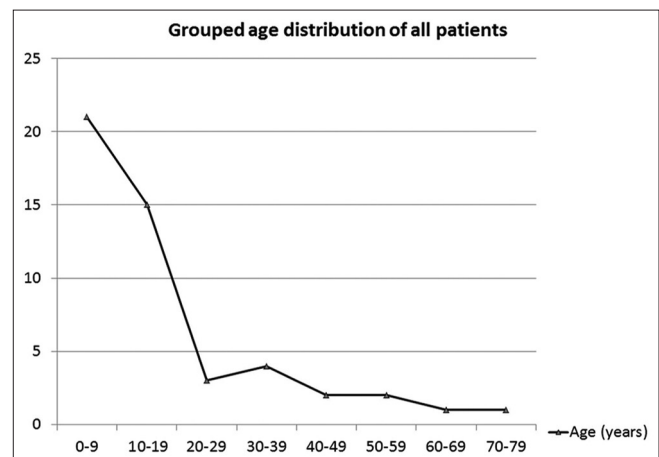


Figure 1: Age distribution of all patients with surgical intracranial suppurations of bacterial origin

There was no statistical significant association between outcome and age group ($P = 0.630$), gender ($P = 0.999$), diagnosis ($P = 0.464$), the type of surgery performed ($P = 0.061$), etiology of ICS ($P = 0.169$), solitary or multiplicity of ICS ($P = 0.485$), type of offending organism ($P = 0.278$), or type of anesthesia ($P = 0.348$). There was also no association between gender and etiology ($P = 0.900$), diagnosis ($P = 0.106$), type of offending organism ($P = 0.330$), age group ($P = 0.277$),

multiplicity of ICS ($P = 0.523$), or GCS grouping ($P = 0.534$); likewise no association between the organism isolated and etiology of ICS ($P = 0.692$), age group ($P = 0.356$), or multiplicity of lesion ($P = 0.688$). The admission GCS score was significantly associated with the outcome ($P = 0.021$) but not significantly associated with age group ($P = 0.385$), diagnosis ($P = 0.680$), etiology ($P = 0.061$), or lesion multiplicity ($P = 0.420$).

Discussion

ICS is the collection of pus within the intracranial compartment, and it is a potentially fatal disease. In ICS of bacterial origin, the optimal outcome is achieved with early diagnosis, urgent neurosurgical drainage, identification of the causative microorganism, and appropriate administration of antibiotics.

We had 49 patients over a 7 years period, with more males being affected with ICS (2.1:1). Cerebral abscess accounted for about two-third of all the 49 patients. The rarest form of ICS noted was cerebellar abscess; this occurred in a female child that was not adequately managed for her open depressed skull fracture. In the cerebral abscess group, the male to female ratio was 1.75:1. Harris *et al.* noted a ratio of 2:1 in their study of brain abscess of 31 patients over a 7-year period in their community hospital.^[6] Also of note is that the overall incidence of ICS peaked in children and early adolescence [Figure 1]. This is similar to the findings of Piatt from the United States of America.^[7] Piatt noted that boys were affected much more commonly than girls with respect to ICS following sinusitis; in his study, black children were affected out of proportion to their presence in the population.^[7]

Paradural abscesses are pus collection in the subdural or epidural space. Within the cranial compartment, subdural empyemas are more frequently encountered than its paradural counterpart, epidural abscesses. Subdural empyemas are said to account for 15–20% of all intracranial infections.^[8,9] However, epidural abscesses occur more commonly in the

Table 1. The diagnosis and gender of patients' with surgical intracranial suppurations of bacterial origin

Diagnosis	Gender		Total (%)
	Male	Female	
Cerebral abscess	21	12	33 (67.3)
Epidural abscess	1	0	1 (2.0)
Subdural empyema	5	1	6 (12.2)
PPT with epidural abscess	0	2	2 (4.1)
PPT with subdural empyema	4	0	4 (8.2)
PPT with paradural abscess	2	0	2 (4.1)
Cerebellar abscess	0	1	1 (2.0)
Total	33	16	49

*Paradural abscess- Combined epidural and subdural abscess

Table 2. The aetiology and gender tabulation of patients' with surgical intracranial suppurations of bacterial origin

Aetiology	Gender		Total (%)
	Male	Female	
Otogenic	12	4	16 (32.7)
Sinusitis	8	6	14 (28.6)
Meningitis	6	2	8 (16.3)
Cardiogenic	3	1	4 (8.2)
Cryptogenic	1	1	2 (4.1)
Traumatic	1	1	2 (4.1)
Odontogenic	1	0	1 (2.0)
Post-operative	1	1	2 (4.1)
Total	33	16	49

Table 3: Organism isolated and aetiology of bacteria intracranial suppuration

Organism(s) culture	Aetiology							Total	
	Cardiac	Crypto genic	Meningitis	Odontogenic	Otogenic	Post-operative	Sinusitis		Traumatic
Beta-haemolytic Streptococcus A	0	0	0	0	2	0	1	0	3
Klebsiella species	0	0	0	0	1	0	0	0	1
Peptostreptococcus	0	0	0	0	0	0	1	0	1
Propionibacterium, Peptostreptococcus	0	0	0	0	0	1	0	0	1
Proteus mirabilis	0	0	0	0	2	0	0	0	2
Pseudomonas aeruginosa	0	1	0	0	0	1	0	0	2
Staphylococcus aureus	0	0	0	0	0	0	0	2	2
Sterile culture	4	0	5	1	6	0	5	0	21
Streptococcus milleri	0	0	0	0	2	0	4	0	6
Streptococcus pneumoniae	0	1	3	0	3	0	3	0	10
Total	4	2	8	1	16	2	14	2	49

spine than in the brain, as they account for more than 90% of all spinal infections.^[5] Subdural empyema was present in 12 patients (24.5%) either in isolation or association with Potts puffy tumor with or without epidural abscess [Table 1]. In Harris *et al.* study, cranial subdural empyema was noted in 6 cases (19.4%), and epidural abscess was the cause in 2 cases (6.5%).^[6] Germiller *et al.* study of consecutive series of 25 children and adolescents noted that epidural abscess was the most common ($n = 13$, 37.1%), followed by subdural empyema ($n = 9$, 25.7%), meningitis ($n = 6$, 17.1%), encephalitis ($n = 2$, 5.7%), intracerebral abscess ($n = 2$, 5.7%), and dura sinus thrombophlebitis ($n = 2$, 5.7%).^[10] Comparing paradural abscesses, subdural empyemas can expand more freely into large, open subdural spaces limited only by the tentorium, foramen magnum, and the falx (cerebri and cerebelli). Hence, subdural empyemas can expand more rapidly and cause more mass effect than epidural abscess.

The routes of ICS include direct contamination from open skull fracture penetrating, contamination at the time of surgery, direct spread from osteomyelitis, septic thrombus entering emissary veins, and hematogenous spread. The most common etiology in our study was from chronic otitis media and sinusitis. This was closely followed by meningitis [Table 2]. In children, meningitis is a common predisposing factor, as this study revealed that close to 40% (8 out of 21) of the patients that were 9 years and below, had meningitis as a predisposing factor for their ICS [Figure 2]. Hematogenous spread from the heart, lungs, or odontogenic origin, likewise penetrating head injury, were rare.

All of our patients had received antibiotics before surgery. These were given at other centers or units prior to referral. This may account for the low positive bacteriological examination of 57.1%. Preoperative antibiotic therapy is known to correlate significantly with the occurrence of sterile cultures.^[11]

Over the past decades, the dawn of computerized tomographic scan and magnetic resonance imaging with contrast

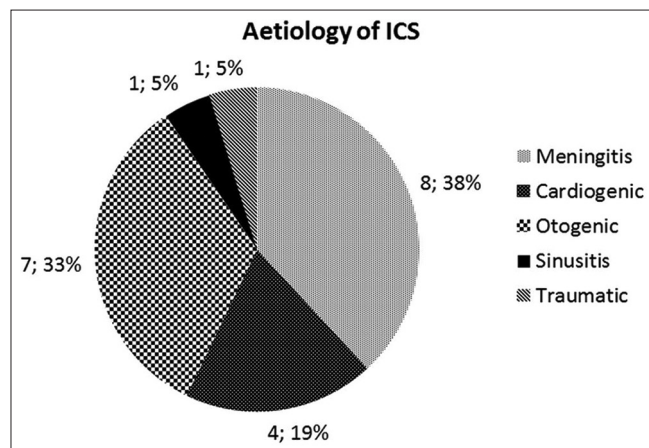


Figure 2: Etiology of intracranial suppuration in patients <10 years of age

enhancement has assisted in the rapid diagnosis and treatment of these lesions. This has resulted in significant improvement in outcome. Despite the significant reduction in mortality, ICS remains a serious illness that can result in severe disability or even death, especially if the presentation is delayed, misdiagnosed, or managed improperly. With appropriate and effective antibiotics and improved surgical techniques, the mortality from ICS has decreased to < 10% in the 1990s,^[12-14] and from 30% to 60% in the early 1970s.^[15,16] The exception to a mortality rate of < 10% is for those with ICS complicated by intraventricular rupture, whose mortality rate can approach 80%.^[17] The mortality rate in our study was 6.1% for all ICS. Besharat *et al.* recorded 9.7% while Sarmast *et al.* noted 7% mortality in brain abscesses.^[18,19] Piatt *et al.* and Germiller noted mortalities of 4% and 2%, respectively, in ICS complicating sinusitis.^[7,10]

The outcome of this infection is often influenced by the virulence of the infecting organism, resistance of the host, presence of altered mental status on presentation, age of the patient, comorbid conditions, neurologic deterioration, and any delay in instituting appropriate treatment. The organisms we isolated did not statistically affect the outcome. The only parameter that significantly affected the outcome was the admission GCS.

Conclusion

ICS usually follows otorhinological infections in our center. It is more common in males with cerebral abscess being the most common form of ICS. The surgical outcome is dependent on the admission GCS score.

References

- Nathoo N, Narotam PK, Nadvi S, van Dellen JR. Taming an old enemy: A profile of intracranial suppuration. *World Neurosurg* 2012;77:484-90.
- Hlavin ML, Kaminski HJ, Fenstermaker RA, White RJ. Intracranial suppuration: A modern decade of postoperative subdural empyema and epidural abscess. *Neurosurgery* 1994;34:974-80.
- Chang AE, O TM. Otagenic cerebral abscess: An unusual complication of otitis media. *Ear Nose Throat J* 2011;90:E11-2.
- Mamelak AN, Mampalam TJ, Obana WG, Rosenblum ML. Improved management of multiple brain abscesses: A combined surgical and medical approach. *Neurosurgery* 1995;36:76-85.
- Calfee DP, Wispelwey B. Brain abscess. *Semin Neurol* 2000;20:353-60.
- Harris LF, Haws FP, Triplett JN Jr, Maccubbin DA. Subdural empyema and epidural abscess: Recent experience in a community hospital. *South Med J* 1987;80:1254-8.
- Piatt JH Jr. Intracranial suppuration complicating sinusitis among children: An epidemiological and clinical study. *J Neurosurg Pediatr* 2011;7:567-74.
- Mauser HW, Tulleken CA. Subdural empyema. A review of 48 patients. *Clin Neurol Neurosurg* 1984;86:255-63.
- Gallagher RM, Gross CW, Phillips CD. Suppurative intracranial complications of sinusitis. *Laryngoscope* 1998;108:1635-42.
- Germiller JA, Monin DL, Sparano AM, Tom LW. Intracranial complications of sinusitis in children and adolescents and their outcomes. *Arch Otolaryngol Head Neck Surg* 2006;132:969-76.
- Gorgan M, Neacsu A, Bucur N, Pruna V, Lipan C, Sandu AM, *et al.*

- Brain abscesses: Management and outcome analysis in a series of 84 patients during 12 year period. *Rom Neurosurg* 2012;19:175-82.
12. Tekkök IH, Erbenli A. Management of brain abscess in children: Review of 130 cases over a period of 21 years. *Childs Nerv Syst* 1992;8:411-6.
 13. Yang SY, Zhao CS. Review of 140 patients with brain abscess. *Surg Neurol* 1993;39:290-6.
 14. Mathisen GE, Johnson JP. Brain abscess. *Clin Infect Dis* 1997;25:763-79.
 15. Rosenblum ML, Hoff JT, Norman D, Weinstein PR, Pitts L. Decreased mortality from brain abscesses since advent of computerized tomography. *J Neurosurg* 1978;49:658-68.
 16. Sharma BS, Khosla VK, Kak VK, Gupta VK, Tewari MK, Mathuriya SN, *et al.* Multiple pyogenic brain abscesses. *Acta Neurochir (Wien)* 1995;133:36-43.
 17. Takeshita M, Kawamata T, Izawa M, Hori T. Prodromal signs and clinical factors influencing outcome in patients with intraventricular rupture of purulent brain abscess. *Neurosurgery* 2001;48:310-6.
 18. Besharat M, Abbasi F. Brain abscess: Epidemiology, clinical manifestations and management: A retrospective 5-year study. *Iran J Clin Infect Dis* 2010;5:231-4.
 19. Sarmast AH, Showkat HI, Bhat AR, Kirmani AR, Kachroo MY, Mir SF, *et al.* Analysis and management of brain abscess; a ten year hospital based study. *Turk Neurosurg* 2012;22:682-9.

How to cite this article: Idowu OE, Majekodunmi AA. Relationship between demography, etiology, level of consciousness, and outcome of surgical intracranial suppurations of bacterial origin in a tropical tertiary center. *Asian J Neurosurg* 2016;11:41-5.

Source of Support: Nil, **Conflict of Interest:** None declared.