

## CASE REPORT

# Transdural retrieval of a retropulsed lumbar interbody cage: Technical case report

Hasan Aqdas Zaidi, Ashish Shah<sup>1</sup>, Udaya Kumar Kakarla

Department of Neurosurgery, Division of Neurological Surgery, St. Joseph's Hospital and Medical Center, Barrow Neurological Institute, Phoenix, Arizona, USA, <sup>1</sup>Department of Neurology, University of Miami, Coral Gables, Florida, USA

## ABSTRACT

The purpose of this case report was to describe a novel method to retrieve a herniated lumbar interbody cage. Transforaminal lumbar interbody fusion (TLIF) is an increasingly popular method of spinal fixation and fusion. Unexpected retropulsion of an interbody is a rare event that can result in intractable pain or motor compromise necessitating surgical retrieval of the interbody. Both anterior and posterior approaches to removing migrated cages may be associated with significant surgical morbidity and mortality. A 60-year-old woman underwent an L4-S1 TLIF coupled with pedicle screw fixation at a previous hospital 5 years prior to admission. She noted sudden-onset bilateral lower extremity weakness and right-sided foot drop. Magnetic resonance imaging and radiographs were notable for purely centrally herniated interbody. A posterior, midline transdural approach was used to retrieve the interbody. Situated in between nerve rootlets to the ventral canal, this virgin corridor allowed us to easily visualize and protect neurological structures while safely retrieving the interbody. The patient experienced an immediate improvement in symptoms and was discharged on postoperative day 3. At 12-month follow-up, she had no evidence of cerebrospinal fluid (CSF) leak and had returned to normal activities of daily living. While the risk of CSF leak may be higher with a transdural approach, we maintain that avoiding unnecessary retraction of the nerve roots may outweigh this risk. To our knowledge, this is the first case report of a transdural approach for the retrieval of a retropulsed lumbar interbody cage.

**Key words:** Cage migration, lumbar interbody, transdural approach

## Introduction

Since its original description by Harms and Rolinger in 1982,<sup>[1]</sup> transforaminal lumbar interbody fusion (TLIF) has become an increasingly popular and clinically efficacious method to restore lumbar lordosis and disk space height in patients with symptomatic spondylolisthesis and degenerative disk disease.<sup>[2,3]</sup> Retropulsion of the interbody cage into the spinal canal, a rare but dreaded complication, has been reported to occur in <1% of cases.<sup>[4-6]</sup> Resultant compression of the exiting nerve root or conus medullaris can result in intractable pain; paraparesis; loss of bowel or bladder function; and

rarely, permanent neurological injury. Depending on the interval between the original surgery and graft herniation, if the interbody is accessed through the original corridor, its removal can be limited by excessive scar tissue and bridging osteophytes from prior bone autograft/allograft insertion. These limitations may necessitate excessive manipulation of the nerve root or thecal sac, potentially resulting in iatrogenic injury to already-compromised neurological tissue.<sup>[6-8]</sup> Little evidence exists outside of anecdotes on how to best approach a retropulsed cage. Transdural approaches to resect intradural pathologies are commonly performed and are within the skill set of competent neurosurgeons. Here we present a novel case of the successful removal of a herniated interbody cage at the L5-S1 level via a transdural approach using skills that are part of a neurosurgeon's armamentarium. To the best of our knowledge, this is the first such report in the literature.

## Case Report

A 60-year-old woman presented to the spine clinic for a complaint of progressive severe pain in her lower back of approximately 2.5 years' duration. She previously underwent an L4-S1 TLIF for mobile spondylolisthesis and radiculopathy 3 years earlier at an outside institution. The patient reported significant improvement in her preoperative symptoms

Access this article online	
Quick Response Code:	Website: www.asianjns.org
	DOI: 10.4103/1793-5482.165802

### Address for correspondence:

Dr. Udaya Kumar Kakarla, c/o Neuroscience Publications, St. Joseph's Hospital and Medical Center, Barrow Neurological Institute, 350 West Thomas Road, Phoenix, Arizona, USA.  
E-mail: neuropub@dignityhealth.org

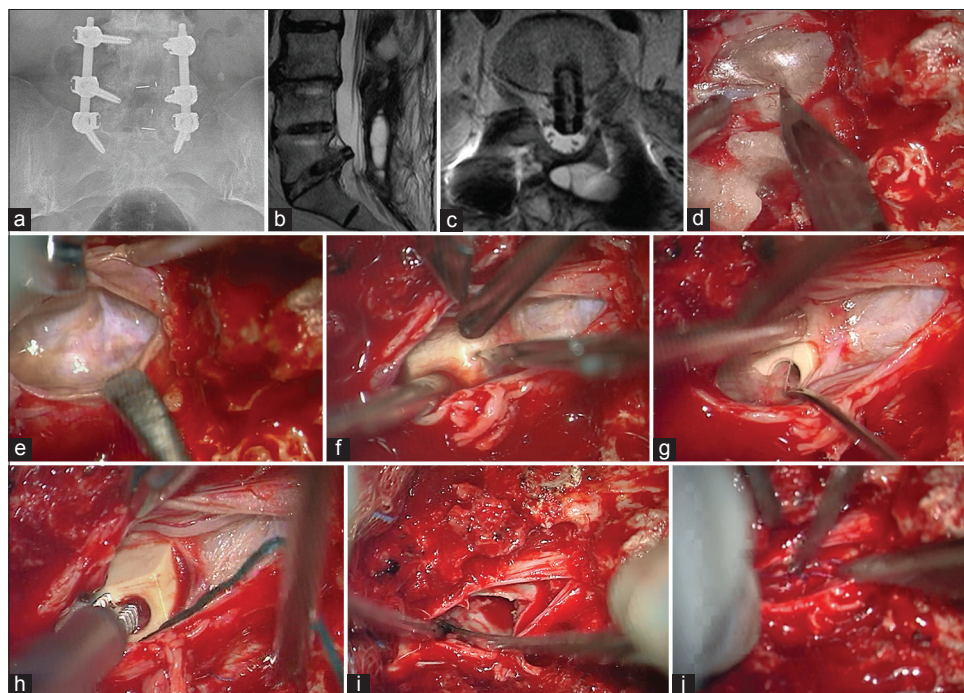
at that time, to the point where she was participating in physical therapy with minimal pain. At 6 months after the index surgery, she fell and reported hearing a distinct “pop” in her back. Since the fall, she remained bedridden with shooting, “shock-like” pain down her left leg associated with a progressively worsening left-sided foot drop (muscle strength 2/5) but with intact genitourinary function and perineal sensation. She was seen in our clinic 2.5 years after the index surgery for the progression of these symptoms. Radiological workup with radiographs and magnetic resonance imaging of the lumbar spine were notable for retropulsion of the L5-S1 interbody cage into the spinal canal, otherwise excellent positioning of the L4-5 interbody, and pedicle screws with posterolateral bridging bone [Figure 1a and b]. These findings were stable over the previous 2.5 years based on radiographic studies obtained after her fall. The patient’s original surgeon suggested revision surgery with the high risk of cerebrospinal fluid (CSF) leak and neurological deficit and the patient deferred a surgical option at that time. However, because of the her progression of her symptoms, she sought a second surgical opinion.

Considering the prolonged interval between the index surgery and the time of presentation to our clinic and the exact central position of the retropulsed interbody [Figure 1c],

we were concerned that significant scar tissue and osteophytic ridge formation would hinder visualization of the graft and place the surrounding neural tissue at risk due to the retraction that would be necessary if the interbody were accessed via the original surgical corridor. In addition, the patient had adjacent segment degeneration and stenosis at the L3-4 segmental level, which explained her progression of symptoms. Our recommendation was a more direct transdural approach that would represent virgin territory, obviating scar tissue while providing adequate visualization with minimal retraction of neurological tissue during retrieval of the interbody. An anterior approach via anterior lumbar interbody fusions was also considered, but a posterior-only approach was recommended because of the presence of additional pathology at L3-4 that required treatment. After risks, benefits, and alternatives to intradural and transdural approaches were explained, the patient agreed to proceed with transdural removal of the retropulsed L5-S1 interbody, along with an L3-4 laminectomy and extension of her fixation from L3 to S1.

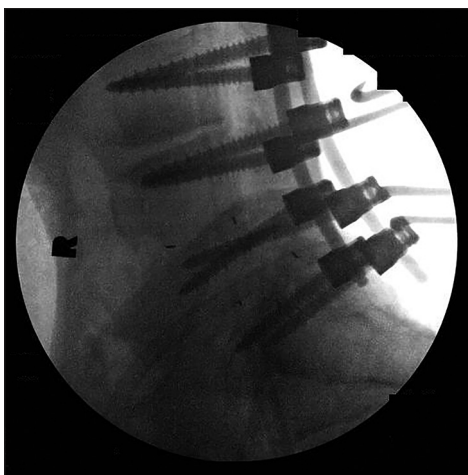
### Operative technique

The prior surgical incision was opened, and surgical dissection was carried down to the existing instrumentation at L4-5 and L5-S1. After the locking caps on all six screws were removed,



**Figure 1:** (a) Preoperative lumbar radiograph demonstrating retropulsion of interbody cage at L5-S1. (b) Sagittal T2-weighted lumbar magnetic resonance imaging (MRI) notable for herniated lumbar interbody with the compromise of the central canal. (c) Axial T2-weighted lumbar MRI is notable for centrally herniated interbody with nerve rootlet compression. Intraoperative images demonstrate (d) the dorsal thecal sac, which is opened sharply using a number 11 blade. (e) The nerve rootlets are gently retracted to either side using a Penfield number 6. (f) The ventral dura is opened sharply, (g) exposing the herniated interbody. (h) A threaded cage inserter is placed into the interbody and (i) gentle rocking motion allows retrieval of the interbody from the disk space, through the ventral dural opening and out of the dorsal dural opening, all while nerve rootlets are visualized and protected. (j) Noncompressed Gelfoam (Pfizer, New York, NY) is placed in the vertebral interspace, and the ventral and dorsal dura are closed in watertight fashion using 6-0 Prolene (Ethicon Endo-Surgery, Inc., Blue Ash, OH) sutures. *Used with permission from Barrow Neurological Institute, Phoenix, Arizona.*

the titanium rods were removed, and each screw was inspected for pseudarthrosis. Bilateral L4 and L5 screws were notably loose and promptly replaced with screws of larger diameter. An L3-4 laminectomy was performed, and L3 pedicle screws were placed. After this, we turned our attention toward the L5-S1 interspace, where the surgical corridor for the original TLIF was unidentifiable secondary to several large osteophytic ridges and extensive scar tissue. Residual lamina at this interspace was identified and removed easily with punch Kerrison rongeurs (Integra LifeSciences, Plainsboro, NJ) until normal midline dura was identified. The surgical microscope was brought in for the transdural portion of the operation. The thecal sac was opened with a number 11 blade in a linear fashion [Figure 1d], and after the egress of CSF, the dura was tacked to the muscle margins. With the retraction of intradural sacral roots [Figure 1e], the herniated interbody was easily visible and palpable through the ventral dura; it was compressing the left-sided exiting sacral rootlets. A Penfield number 2 was used to gently retract the nerve rootlets to either side, and a number 11 blade was once again used to open the ventral dura in a linear fashion directly over the herniated interbody [Figure 1f and 1g]. Once open, the ventral dura was retracted to either side of the herniated interbody, and a graft inserter was threaded into the interbody [Figure 1h]. Using repetitive rocking motions medially/laterally to disrupt any bridging osteophytes attached to the interbody, we carefully shimmed the cage out through the ventral dura, traversing the thecal sac, and finally out through the opening in the dorsal dura [Figure 1i]. The intradural nerve rootlets were inspected for any damage. The dura was closed in sequential fashion, ventrally then dorsally, using 5-0 Prolene sutures (Ethicon Endo-Surgery, Inc., Blue Ash, OH) and buttressed with DuraSeal (Covidien, Mansfield, MA) sealant [Figure 1j]. Segmental fixation was completed with titanium rods locked in place from L3 to S1, along with autograft/allograft bone placed posterolaterally [Figure 2]. A lumbar drain was not



**Figure 2:** Postoperative lumbar radiograph notable for extension of fusion from L3 to S1 and successful retrieval of interbody cage. Used with permission from Barrow Neurological Institute, Phoenix, Arizona.

placed, and the patient was kept flat for 24 h. A few hours postoperatively, the patient noted immediate improvement in her pain but had no improvement in her foot drop. She was up and mobilizing on postoperative day (POD) 2 with the physical therapy team, off all narcotics on POD 3, and discharged to rehabilitation on POD 4. At her 12-month follow-up visit, she was self-ambulatory, performing her normal activities of daily living, and had a complete resolution of pain and some improvement in foot drop (to muscle strength 3/5).

## Discussion

When originally introduced by Cloward in 1945,<sup>[9]</sup> interbody cage fusion was not widely accepted by the surgical community due to a high incidence of unexpected cage migration. The advent of pedicle screw fixation in tandem with interbody fusion introduced several decades later<sup>[10]</sup> served to reduce but not eliminate the incidence of cage migration. In a recent review of 1070 cases, Kimura *et al.* noted that cage migration necessitating surgical revision occurred in <1% of patients, with the cage migration typically resulting in intractable pain or new motor deficits.<sup>[6]</sup> Risk factors include multi-level fusion (no evidence of migration was encountered in single-level fusions), total facetectomy, disk space morphology (wide or pear-shaped), and lack of instrumentation.<sup>[6,7]</sup> Cage subsidence was more often encountered at L5-S1 (66%) and L4-5 (22%), likely due to unfavorable disk space morphology encountered at these levels.

Despite its rare occurrence, the consequences of cage retropulsion can be disabling to the patient, and the pathology poses a formidable surgical challenge to the surgeon. Only a limited number of case reports and small case series are available in the neurosurgical literature discussing the ideal approach to retropulsed interbodies. Both traditional anterior and posterior approaches have been marred by a significant number of iatrogenic complications. Nguyen *et al.* reported a series of 13 patients who had an unexpected migration of an interbody device (four posterior lumbar interbody fusions, five TLIFs, four anterior lumbar interbody fusions) removed via a purely anterior approach.<sup>[11]</sup> The authors reported a 71% complication rate, with vascular injury encountered in nearly 57% of cases and one postoperative death due to multiple catastrophic venous injuries during the surgical approach. Similarly, a posterior approach via the original surgical corridor has been discouraged by some surgeons because of high concern about possible injury to exiting nerve roots and the conus medullaris due to the degree of traction required on the thecal sac in order to access a medially placed interbody.<sup>[8,12]</sup> In addition, excessive and extensive scar and osteophyte formation may obscure the anatomic waypoints necessary to safely navigate the surgical approach.

A posterior-transdural approach to ventrally located pathology in the lumbar spine is not novel, and has been previously well described in the literature. Choudhari *et al.* reported two cases of



intentional durotomies to remove herniated lumbar disks, with navigation between nerve rootlets to access the ventral canal.<sup>[13]</sup> Similarly, Choi *et al.* reported four cases of calcified discs at L1-2 accessed via a posterior-transdural approach with acceptable surgical morbidity, including one patient with a postoperative CSF leak treated with a lumbar drain.<sup>[14]</sup> In both cases, the authors cited avoidance of nerve root and conus medullaris retraction as the reason such an approach was chosen.

Here we describe the first known report of successful retrieval of a herniated transforaminal lumbar interbody cage via a posterior-transdural approach with resultant excellent neurological recovery. This novel approach obviates the catastrophic vascular injuries encountered from an anterior approach, and retraction-related nerve root injury and poor visualization frequently encountered from a posterior-extradural approach. Although not experienced here, increased potential for nerve rootlet injury, persistent CSF leak, meningitis, and arachnoiditis are theoretically possible. However, these are the same risks associated with any transdural approaches for intradural pathology that are commonly performed by neurosurgeons. A large, prospective study with long-term follow-up would be required to elucidate better the efficacy of this approach, but we consider this direct transdural approach ideal for centrally located herniated cages in the lower lumbar spine at the level of the cauda equina. Conversely, we avoid this approach for upper lumbar and thoracic levels where the spinal cord and conus medullaris can potentially be compromised; a ventral approach would be more appropriate in these situations.

## Conclusion

Extensive study of preoperative imaging, review of prior surgical techniques (e.g., including extent of bony removal, interbody type), patient body habitus, medical status, and neurological examination all need to be taken into account when deciding on the surgical approach for retrieval of retropulsed interbodies. We believe a transdural approach may be optimal in a select group of patients, as it provides improved visualization of nerve rootlets and obviates the need for nerve root retraction when scar tissue is present. Further study is necessary to validate these findings and to truly assess the potential complications associated with this approach.

## References

1. Harms J, Rolinger H. A one-stager procedure in operative treatment of spondylolistheses: Dorsal traction-reposition and anterior fusion (author's transl). *Z Orthop Ihre Grenzgeb* 1982;120:343-7.
2. Potter BK, Freedman BA, Verwiebe EG, Hall JM, Polly DW Jr, Kuklo TR. Transforaminal lumbar interbody fusion: Clinical and radiographic results and complications in 100 consecutive patients. *J Spinal Disord Tech* 2005;18:337-46.
3. Seng C, Siddiqui MA, Wong KP, Zhang K, Yeo W, Tan SB, *et al.* Five-year outcomes of minimally invasive versus open transforaminal lumbar interbody fusion: A matched-pair comparison study. *Spine (Phila Pa 1976)* 2013;38:2049-55.
4. Kuslich SD, Ulstrom CL, Griffith SL, Ahern JW, Dowdle JD. The Bagby and Kuslich method of lumbar interbody fusion. History, techniques, and 2-year follow-up results of a United States prospective, multicenter trial. *Spine (Phila Pa 1976)* 1998;23:1267-78.
5. Tsachtsaris A, Efendy JL, Mannion RJ, Wood MJ. Complications from minimally invasive lumbar interbody fusion: Experience from 100 patients. *J Clin Neurosci* 2013;20:813-7.
6. Kimura H, Shikata J, Odate S, Soeda T, Yamamura S. Risk factors for cage retropulsion after posterior lumbar interbody fusion: Analysis of 1070 cases. *Spine (Phila Pa 1976)* 2012;37:1164-9.
7. Chen L, Yang H, Tang T. Cage migration in spondylolisthesis treated with posterior lumbar interbody fusion using BAK cages. *Spine (Phila Pa 1976)* 2005;30:2171-5.
8. Glassman SD, Johnson JR, Raque G, Puno RM, Dimar JR. Management of iatrogenic spinal stenosis complicating placement of a fusion cage. A case report. *Spine (Phila Pa 1976)* 1996;21:2383-6.
9. Cloward RB. The treatment of ruptured lumbar intervertebral discs by vertebral body fusion. I. Indications, operative technique, after care. *J Neurosurg* 1953;10:154-68.
10. Steffee AD, Sitkowski DJ. Posterior lumbar interbody fusion and plates. *Clin Orthop Relat Res* 1988;227:99-102.
11. Nguyen HV, Akbarnia BA, van Dam BE, Raiszadeh K, Bagheri R, Canale S, *et al.* Anterior exposure of the spine for removal of lumbar interbody devices and implants. *Spine (Phila Pa 1976)* 2006;31:2449-53.
12. Nagayama R, Nakamura H, Yamano Y, Yamamoto T, Minato Y, Seki M, *et al.* An experimental study of the effects of nerve root retraction on the posterior ramus. *Spine (Phila Pa 1976)* 2000;25:418-24.
13. Choudhari KA, Fannin TF, Byrnes DP. Transradicular interfascicular approach for lumbar microdiscectomy: A useful technique in difficult circumstances. *Br J Neurosurg* 2001;15:360-2.
14. Choi JW, Lee JK, Moon KS, Hur H, Kim YS, Kim SH. Transdural approach for calcified central disc herniations of the upper lumbar spine. Technical note. *J Neurosurg Spine* 2007;7:370-4.

**How to cite this article:** Zaidi HA, Shah A, Kakarla UK. Transdural retrieval of a retropulsed lumbar interbody cage: Technical case report. *Asian J Neurosurg* 2016;11:84-7.

**Source of Support:** Nil, **Conflict of Interest:** None declared.