

The impact of cranioplasty on cerebral blood flow and its correlation with clinical outcome in patients underwent decompressive craniectomy

Jon Kooi Mah, Rosman Azmin Kass¹

Department of Neurosciences, School of Medical Sciences, Hospital Universiti Sains Malaysia, Kelantan,

¹Department of Neurosurgery, Hospital Sungai Buloh, Jalan University, Selangor, Malaysia

ABSTRACT

Context: Decompressive craniectomy is commonly use as the treatment for medically refractory intracranial hypertension. Unexpected improvement in patient's neurological status has been observed among patients that underwent cranioplasty. Restoration of cerebral blood flow (CBF) hemodynamics is one of the contributing factors. This study was conducted to determine the impact of cranioplasty on CBF and its correlation with clinical outcome.

Aims: This study was done to evaluate the effect of cranioplasty on CBF with computed tomography perfusion (CTP). It also aimed to determine the correlation between postcranioplasty CBF and clinical outcome.

Settings and Design: Prospective observational study.

Subjects and Methods: All patients had CTP done to determine precranioplasty CBF. CTP was repeated at 6 weeks postcranioplasty and clinical assessment at 6 and 24 weeks postcranioplasty.

Statistical Analysis Used: Data analysis was done using Statistical Package for Social Sciences version 12.0.1.

Results: The median value of the ipsilateral CBF was 48.87 and 61.10 ml/min/100 g at precranioplasty and 6 weeks postcranioplasty ($P < 0.001$). Contralateral CBF also showed improvement from 60.55 to 71.84 ml/min/100 g ($P < 0.001$). Median value for mini mental state examination showed a significant difference with value of 22, 25, and 25.5 at precranioplasty, 6 and 24 weeks postcranioplasty ($P = 0.001$ and $P < 0.001$). Median value for frontal assessment battery was 12, 14.5, and 15 ($P = 0.002$ and $P = 0.001$).

Conclusions: Cranioplasty can remarkably improve cortical perfusion for both ipsilateral and contralateral hemisphere. Though we are unable to establish strong correlation, between CBF and clinical outcome, cranioplasty was observed to have a therapeutic role in terms of clinical outcome improvement.

Key words: Cerebral blood flow, clinical outcome, computed tomography perfusion, cranioplasty

Introduction

Decompressive craniectomy (DC) procedure has recently experienced a renewed interest among neurosurgeons

worldwide. Relief of intracranial pressure (ICP) by DC was first described by Cushing in the early 20th century.^[1] Since then surgical decompressive has been advocated as a treatment for severe brain edema associated with brain injury and infarction.^[2]

Many published articles demonstrated good surgical outcome following cranioplasty; however until today, there

Access this article online	
Quick Response Code:	Website: www.asianjns.org
	DOI: 10.4103/1793-5482.172593

This is an open access article distributed under the terms of the Creative Commons Attribution-NonCommercial-ShareAlike 3.0 License, which allows others to remix, tweak, and build upon the work non-commercially, as long as the author is credited and the new creations are licensed under the identical terms.

For reprints contact: reprints@medknow.com

Address for correspondence:

Dr. Jon Kooi Mah, Department of Neurosciences, School of Medical Sciences, Hospital Universiti Sains Malaysia, 16150 Kubang Kerian, Kelantan, Malaysia.
E-mail: Mah_general@yahoo.co.uk

How to cite this article: Mah JK, Kass RA. The impact of cranioplasty on cerebral blood flow and its correlation with clinical outcome in patients underwent decompressive craniectomy. Asian J Neurosurg 2016;11:15-21.

are no clearly defined indication for or optimal timing of the procedure. The good outcomes are thought to be due to improved collateral circulation, reduction in tissue edema and improvement in oxygenation and energy metabolism in injured tissues.^[3]

Currently, the main indications for cranioplasty are cosmetic reconstruction and cerebral protection. Cranioplasty is usually performed several months after DC with the lack of specific guidelines on the timing of surgery. Unexpected improvements in patients neurological status have been observed in many centers. Suzuki *et al.* reported five out of six patients actually showed improvement in neurological signs after cranioplasty.^[4] These findings were also supported by Maekawa *et al.* who reported improvement of neurological outcome in five of the eight patients postcranioplasty.^[5] Until date, the mechanism of improvement remains unclear. Yamaura and Makino in 1977 suggested that atmospheric pressure is transmitted to the cranial cavity through the cranial defect, causing inward rotation of the scalp.^[6] This pressure on the cranial defect can thus cause the neurological deficit. The unprotected brain compression through the cranial defect by the atmospheric pressure can be normalized by cranioplasty.^[7]

Improvement in cerebral perfusion after cranioplasty has since been established by many modalities. Yoshida *et al.*^[8] in their studies using ¹³³Xe computed tomography (CT) and ³¹P magnetic resonance spectroscopy concluded that cranioplasty was able to improve cerebral blood flow (CBF) and energy metabolism. Cerebral perfusion improvement after cranioplasty has also been shown by several other studies using transcranial Doppler.^[7,9,10] More recently, the use of CT perfusion imaging to measure CBF has been gaining popularity. This modality is generally easier to be performed and less operator dependent compared to transcranial Doppler and ¹³³Xe CT. Excellent cooperation from the patient is also needed if the technique of measuring CBF is by using ¹³³Xe CT. Besides that, CBF measurement using CT perfusion (CTP) gained much attention partly due to the improved helical scanning, CT scan machine, and advances in the software used to analyze the data which aid in the accuracy and ease of performing.^[11] The procedure is also minimally invasive with the only intravenous administration of iodinated contrast material. More importantly, CTP has been validated and proven to have excellent correlation with ¹³³Xe CT in the measurement of CBF.^[12] CTP measurement of cranioplasty related perfusion changes were done by Sakamoto *et al.* in 2006 and Sarubbo *et al.* in 2014.^[11,13]

This study was done with the aim to further establish the hypothesis that cranioplasty not only provides cerebral protection and cosmesis but also improve CBF and clinical outcome.

Subjects and Methods

Study design

This was a prospective observational study on patients who have underwent DC for intracranial hypertension requiring reconstructive cranioplasty at Hospital, Sungai Buloh from the period of 1 September 2013 to 1 September 2014.

Study population

All patients aged over 18 and up to 65 years who underwent DC for intracranial hypertension and requiring reconstructive cranioplasty at Hospital Sungai Buloh from 1 September 2013 to 1 September 2014. They or guardians must also consent to be part of this study. Patient with previous bilateral DC, allergy to contrast, pregnant, or nursing woman will be excluded.

Study schedule

During admission for cranioplasty, CBF, and clinical outcome assessment mini mental state examination (MMSE), Glasgow Outcome Score (GOS), and frontal assessment battery (FAB) were done. Postcranioplasty 6 weeks, a repeat of CBF and clinical outcome assessment was repeated. Subsequently, on 24 weeks postcranioplasty clinical outcome assessment was repeated.

Study procedure and evaluations

CTP analysis was performed using 40-slice CT scanner (SIEMENS, SOMATOM Sensation Open) using a 40-slice long continuous (cine) scan. One hundred and twenty axial images were constructed with three 9.6 mm thick sections which covered a total of 28.8 mm from the level of foramen of Monro to the lateral ventricle. The CT scanner protocols were 80 kV, 209 mA, 1 s per rotation and at 0° gantry. The CTP scan was started with a 4 s delay after the injection of 40 ml of nonionic contrast agent Iopamidol (BRACCO, Iopamiro 370) at a rate of 6 ml/s with an infuser pump (STELLANT, medrad). All CTP scans were analyzed with a software package using an imaging workstation (SIEMENS, Syngo multimodality workplace 2010A). CBF map was generated for each patient and was expressed in ml/min/100 g. CBF were measured in three circular regions of interest at a size of 1 cm², manually drawn on the plain CT brain and averaged CTP images in the ipsilateral hemisphere and then automatically reflected onto the contralateral hemisphere in the midline. In each patient, the CBF was averaged to generate a single value for each hemisphere.

Sample size calculation

Prior data indicate that the standard deviation of preoperation hemispheric CBF was 3.4 and standard deviation for postoperation hemispheric CBF was 3.9.^[8] If the mean difference between pre- and post- hemispheric CBF was 2.6, by using Power and Sample Size Calculation software version 3.0.12 (IBM, United States),^[14] with reference to specific objective 1, we will need to study 18 patients to be able to reject the null hypothesis that this response difference is zero with probability (power) 0.8.

The Type 1 error probability associated with this test of this null hypothesis is 0.05. However, after taken into account of 20% dropout rate, the total sample size required were 22 patients.

Results

A total of 22 patients were recruited in this study from the period of 1 September 2013 to 1 April 2014 in the Neurosurgery Department Hospital Sungai Buloh. From the total of 22 patients, 18 patients (81.82%) were male and four patients (18.18%) were female. The patients were aged 19–55 years old with a mean age of 32.73 years old [Table 1].

CBF median value measured in the ipsilateral hemisphere was significantly higher at 6 weeks postcranioplasty (61.10 ml/min/100 g) compared to precranioplasty (48.87 ml/min/100 g) ($P < 0.001$). Similarly, the CBF mean value of the contralateral hemisphere also showed a significant improvement 6 weeks postcranioplasty (71.84 ml/min/100 g) from precranioplasty (60.55 ml/min/100 g) ($P < 0.001$) [Table 2].

The median value for GOS at precranioplasty, 6 weeks and 24 weeks postcranioplasty was four [Figure 1]. There was no difference in the median value at precranioplasty compared

to 6 weeks and 24 weeks postcranioplasty ($P = 0.046$ and $P = 0.014$).

The median value for MMSE at precranioplasty, 6 weeks and 24 weeks postcranioplasty was 22, 25 and 25.5, respectively. It was a statistically significant difference in the median value of MMSE at precranioplasty (22, IQR 12.74) and 6 weeks postcranioplasty (25, IQR 12.50) ($P = 0.001$). At 24 weeks postcranioplasty median value of MMSE (25.5, IQR 13.00), further improved ($P < 0.001$). The median value of MMSE at 6 weeks postcranioplasty (25, IQR 12.50) and 24 weeks postcranioplasty was also significantly different with $P = 0.012$ [Figure 2].

The median value for FAB at precranioplasty, 6 weeks and 24 weeks postcranioplasty was 12, 14.5 and 15, respectively. Median value for FAB precranioplasty showed improvement compared to 6 weeks postcranioplasty from 12 (IQR 10.75) to 14 (IQR 11.35) ($P = 0.002$). At 24 weeks postcranioplasty follow-up, median value for FAB was 15 (11.25) ($P = 0.001$) [Figure 3].

There was no significant correlation between CBF and clinical correlation [Table 3].

Table 1: Demographic analysis

Characteristics	Number of patients (%)
Number of patients	22
Male	18 (81.82)
Female	4 (18.18)
Mean age (years)	32.73±11.87
Ethnic	
Malay	11 (50.00)
Chinese	3 (13.64)
Indian	6 (27.27)
Others	2 (9.09)
Education level	
Primary	8 (36.36)
Secondary	13 (59.10)
Tertiary	1 (4.55)
Laterality of craniectomy	
Right	7 (31.82)
Left	15 (68.18)
Cranioplasty material	
Autologous	11 (50.00)
Acrylic	3 (13.64)
Titanium	8 (36.36)
Indication for decompressive craniectomy	
Trauma	17 (77.27)
Ischemic stroke	1 (4.55)
Hemorrhagic stroke	3 (13.64)
Bleeding vascular lesion (AVM)	1 (4.55)
Mean number of weeks between craniectomy and cranioplasty	67.27±66.33

AVM – Arteriovenous malformation

Table 2: Nonparametric Wilcoxon signed-rank test (median value of CBF for ipsilateral and contralateral hemisphere at precranioplasty and 6 weeks postcranioplasty)

Cerebral hemisphere	Median (IQR) CBF precranioplasty (mL/min/100 g)	Median (IQR) CBF 6 weeks postcranioplasty (mL/min/100 g)	Z statistic ^a	P
Ipsilateral	48.87 (25.05)	61.10 (31.65)	-4.107	<0.001
Contralateral	60.55 (23.61)	71.84 (24.59)	-4.107	<0.001

^aWilcoxon signed-rank test. CBF – Cerebral blood flow; IQR – Interquartile range

Table 3: Nonparametric Spearman's correlation test (CBF and clinical outcome) at 6 weeks postcranioplasty

	Spearman's correlations	
	CBF ipsilateral 6 weeks postcranioplasty	CBF contralateral 6 weeks postcranioplasty
GOS 6 weeks postcranioplasty		
Correlation coefficient	0.018	0.005
Significant (two-tailed)	0.935	0.981
<i>n</i>	22	22
FAB 6 weeks postcranioplasty		
Correlation coefficient	0.076	0.178
Significant (two-tailed)	0.737	0.428
<i>n</i>	22	22
MMSE 6 weeks postcranioplasty		
Correlation coefficient	-0.66	0.120
Significant (two-tailed)	0.770	0.595
<i>n</i>	22	22

CBF – Cerebral blood flow; GOS – Glasgow Outcome Score; FAB – Frontal assessment battery; MMSE – Mini mental state examination

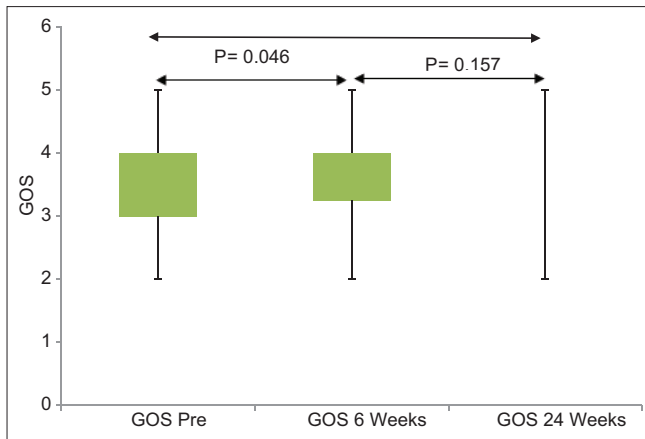


Figure 1: Box plot of Glasgow Outcome Score at precranioplasty, 6 weeks and 24 weeks postcranioplasty

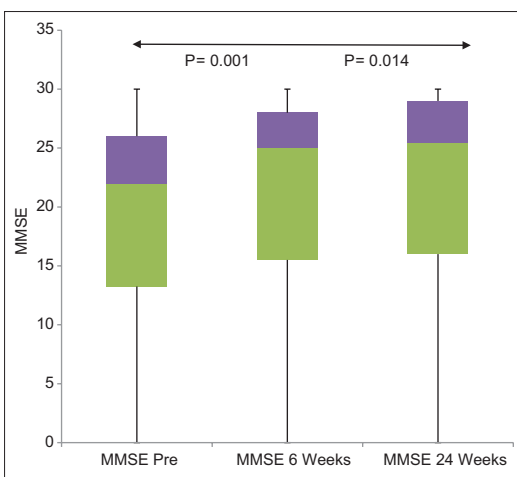


Figure 2: Box plot of mini mental state examination at precranioplasty, 6 weeks and 24 weeks postcranioplasty

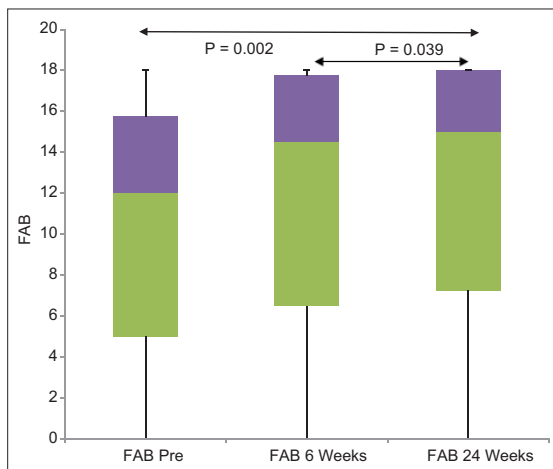


Figure 3: Box plot of frontal assessment battery at precranioplasty, 6 weeks and 24 weeks postcranioplasty

Discussion

DC has been widely used for more than a century for the treatment of medically refractory intracranial hypertension for

multiple reasons. This procedure is efficient, not complicated and straight forward. DC managed to effectively reduce ICP in 85% of patients who have intracranial hypertension refractory to conventional medical treatment.^[15,16] Long-term results (3 years) and good clinical outcome are also seen in up to 40% of patients who were otherwise most likely to die.^[17]

In the past, the majority of patients after DC will undergo reconstructive cranioplasty for cosmesis or protective reasons. Exceptions are to those who are very old, vegetative, and with poor outcome. However, the results of cranioplasty were beyond cosmetic and protective effect. The reconstructive cranioplasty procedure provides important support and restores normal cerebrospinal fluid flow dynamics and protecting vital structures. Some clinicians actually documented clinical improvement in them; therefore in these recent years, the influence of cranioplasty on clinical outcome has garnered much interest. Many studies have been published regarding the improvement of clinical outcome after cranioplasty.^[4,10,18,19] Even back in 1977, Yamaura *et al.* reported that 30% of its patient with sinking skin flap after DC showed unquestionable clinical improvement after cranioplasty.^[20] Globally many researches have concluded from their studies that cranioplasty not only serve as cerebral protection and cosmesis but also for the final patient clinical outcome. Due to the above reason, this study was conducted to evaluate the clinical outcome improvement after cranioplasty, alongside with CBF improved perfusion. These improvements seen were not limited only to a patient with traumatic brain injury, which was a population of interest in most of the previous studies. In fact, clinical improvement was also seen in the nontraumatic cause for DC.^[11] Our sample population therefore not only limited to traumatic brain injury cases that underwent DC but also included cases of DC for other reasons, as we believe these improvements can also be seen in such cases.

Patients commonly after DC exhibit collapsed hemispheric over the side of the cranial defect. A collection of neurological symptoms is attributed to the collapsed hemispheric such as the neurological deficit, headache, dizziness, fatigue, and psychiatric changes. Syndrome of the sinking skin flap is defined as a presence of neurological deficit with depressed skin at the site of the cranial defect after a large DC.^[6] A similar condition, on the other hand, is characterized by subjective symptoms such as a headache, dizziness, vague discomfort, irritability, and lethargy which is known as a syndrome of trephined.^[19] Both of these conditions most likely were due to a similar mechanism of onset as the symptoms caused by these conditions improve rapidly following cranioplasty.^[11] The pathophysiology of both these syndromes may involve many confounding factors such as CBF, cerebrospinal fluid, and atmospheric pressure.^[6,20,21] Atmospheric pressure acting on the unprotected brain at the bone defect site is said to be the main contributing factor. This will then lead to

compression of the dura with irritation of the underlying cortical tissue and eventually gliosis, therefore, causing neurological deficits. Cranioplasty is said to normalize this situation, by preventing atmospheric pressure acting on the unprotected brain.^[21] A more thorough explanation is published by Segal *et al.*, which attributed the abnormal symptoms to the impediment of venous return and presence of cortical scar tissue.^[22] He suggested that scar tissue produced by injury would increase pressure on the cortex and subarachnoid space along with the compressive effect from the atmosphere. These cumulative effects then alter the cerebral hemodynamics with the resultant of increase in local external pressure on the vessels, which would then reduce the CBF in the area of the cranial defect. However, no concrete evidence to support his explanation until of recent years whereby many studies was done that shows improved perfusion with cranioplasty.^[4,8,11,23,24]

In this study, we sought to define the brain cortical CBF changes before and after cranioplasty for both ipsilateral and contralateral hemisphere. CBF assessment on the contralateral side of the lesion was also included in our study as it has been shown before that such improvement does exist.^[4,5] Suzuki *et al.* concluded that five of the six patients in his study showed neurological improvement after cranioplasty with all showing bilateral improvement of CBF measured via dynamic CT. On the other hand, Maekawa *et al.* noted bilateral improvement in the CBF using Xenon CT before and after cranioplasty for all his eight patients. Only five out of eight of his patients showed improvement in neurological signs after cranioplasty.

CBF measurement using Xenon CT was the technique of choice in the past. Recently, newer technologies have made a measurement of CBF more feasible in critically ill patients and less complicated. CTP is currently considered emerging imaging modalities for cerebral hemodynamics measurement.^[11,24] CTP imaging quantitative measurement of CBF gained much attention partly due to the improved helical scanning, CT scan machine and advances in the software used to analyze the data. Besides that, it is also less operator dependent compared to transcranial Doppler and less invasive which only involved intravenous administration of iodinated contrast material. Dynamics of CBF is also proven to be accurately map out by Xenon CT; however, this technique necessitates excellent collaboration from the patient.^[12] Most importantly, CBF measurement via CTP is reported to have good correlation with Xenon CT and, therefore, reliable.^[12]

The selection of candidates was based on convenience sampling mainly due to time and resource limitation in this study. Our patient underwent DC for intracranial hypertension due to multiple initial diagnoses. We did not limit our selection to only traumatic brain injury patient as the objective of our study is to evaluate the improvement of CBF between pre- and

post-cranioplasty regardless of initial diagnosis for DC. More so, Sakamoto *et al.* in his case report had shown improvement in CBF in a patient who underwent bone flap removal during treatment of an epidural abscess due to wound infection after clipping of a ruptured aneurysm.^[11] Therefore, the improvement in CBF is not limited only to cases of traumatic brain injury which was the selection criteria for many previous studies.^[13,23]

In our series, among the 22 patients evaluated by CTP pre- and 6 weeks post- cranioplasty, a statistically significant improvement in CBF was noted for both ipsilateral and contralateral hemisphere. For the ipsilateral hemisphere, median cortical CBF was 48.87 (IQR 25.05) ml/min/100 g at precranioplasty, improved to median cortical CBF of 61.10 (IQR 31.65) ml/min/100 g at 6 weeks postcranioplasty. Similarly, contralateral hemisphere also documented improvement in median cortical CBF with 60.55 (IQR 23.61) ml/min/100 g at precranioplasty to 71.84 (IQR 24.59) ml/min/100 g at 6 weeks postcranioplasty. Both of these findings were statistically significant with $P < 0.001$ (Wilcoxon signed-rank test). Our findings suggest that restorative cranioplasty not only improve on local cortical CBF, but also contralateral cortical CBF. This clinical data were supported by the findings of Sakamoto *et al.* and Sarubbo *et al.* in their studies using CTP and Chibbaro *et al.* by using transcranial Doppler.^[11,13,23] However, in the study of Sarubbo *et al.*, which involved six stable patients with traumatic brain injury after cranioplasty the increment of CBF was only observed between precranioplasty and 7 days postcranioplasty. Further follow-up at 3 months postcranioplasty, CBF actually showed a reduction in value. The explanation to his findings was that the gradual decline in cortical perfusion in the ipsilateral hemisphere over a 3 months period may be due to a restoration of flow compatible with prevailing metabolic demand rather than worsening of perfusion that could trigger ischemic injury as supported by no new clinical deterioration.^[13] For our patients, we believe that the restorative cranioplasty actually normalized the atmospheric pressure acting on the unprotected brain. Therefore, it improved on the ipsilateral and contralateral cerebral hemodynamics in the context of CBF postcranioplasty as suggested by Stula.^[21]

Clinical outcome in terms of GOS, MMSE, and FAB were compared precranioplasty, 6 and 24 weeks postcranioplasty in our series. Both median values of MMSE and FAB showed a significant improvement at precranioplasty compared to 6 and 24 weeks postcranioplasty. These clinical data were corresponding to the studies done by Chibbaro *et al.*, whereby remarkable neurological and cognitive improvement has been recorded at postcranioplasty.^[10,23] However, in their studies the sample populations were limited to those with severe head injury and undergoing early reconstructive cranioplasty. Therefore, cranioplasty was effective not only for cosmesis and

cerebral protection but also for the improvement of CBF and neurological deficits (MMSE and FAB).

On the other hand, the median value of GOS showed no difference between precranioplasty, 6 weeks and 24 weeks postcranioplasty with all giving a median value of 4. These findings were statistically significant. We believe that this finding may not be the actual scenario as GOS has been criticized for its lack of sensitivity to detect small but clinically significant changes in outcome.^[25] In fact, the extended GOS may potentially address this shortcoming.

Interestingly, in our study we noticed that there was no between CBF and clinical outcome (GOS, FAB, and MMSE) at 6 weeks postcranioplasty (Spearman's correlation test, $P > 0.05$). With these findings, it actually suggested that CBF alone may not be the only factor that determine clinical outcome. The selection of our candidates had a wide age range, different education level, different indication for DC (trauma vs. nontrauma), time of cranioplasty (early vs. late), laterality of DC (right vs. left), and choice of cranioplasty material (autologous vs. acrylic vs. titanium), which may have influence on the clinical outcome. Until today, the choice of cranioplasty material and time of cranioplasty (early vs. late) is still inconclusive whether these variables actually affect surgical outcome.^[26-30] But we believe that these variables play a significant role in the surgical outcome and thus affecting the final clinical outcome. Other than that, we also noticed that patient and patient's family member were more actively involved with physiotherapy and rehabilitation activity after cranioplasty. This may be due to the confidence that the patient and patient's family had after the reconstructive cranioplasty which provide cerebral protection. The role of rehabilitation and physiotherapy were undeniably an important factor in contributing to the better clinical outcome. The relationship of rehabilitation intervention and the good functional outcome was also seen in a stroke patient.^[31]

Conclusion

This study suggests that reconstructive cranioplasty after DC for intracranial hypertension can significantly improve cortical CBF not only in ipsilateral but also in the contralateral hemisphere. This is concluded based on higher median CBF value for precranioplasty as compared to 6 weeks postcranioplasty bilaterally.

Significant improvement in clinical outcome (MMSE and FAB) was also noted to improve following cranioplasty.

However, there was no significant correlation between improve CBF and clinical outcome. This finding may be attributed to several other confounding factors that will affect the clinical outcome of cranioplasty. These factors include age of patients, duration of surgery, types of material used for cranioplasty,

duration of bone storage, initial diagnosis for DC, and patient's preoperative nutritional and health status. Although, these factors remained inconclusive and debated with regards to surgical outcome after cranioplasty, we believe it contributes to the final clinical outcome.

Skull defect after DC can severely impair cortical perfusion and clinical outcome. We propose that reconstructive cranioplasty should be done to all patients to improve cerebral perfusion and clinical outcome. Cranioplasty also provides cosmetic correction and cerebral protection which will further boost patient's and caregiver's psychosocial aspect to participate in a rehabilitation program which will then enhance future recovery.

Financial support and sponsorship

Nil.

Conflicts of interest

There are no conflicts of interest.

References

1. Cushing H. I. Subtemporal decompressive operations for the intracranial complications associated with bursting fractures of the skull. *Ann Surg* 1908;47:641-4.
2. Ransohoff J, Benjamin MV, Gage EL Jr, Epstein F. Hemisphericectomy in the management of acute subdural hematoma. *J Neurosurg* 1971;34:70-6.
3. Zweckberger K, Stoffel M, Baethmann A, Plesnila N. Effect of decompression craniotomy on increase of contusion volume and functional outcome after controlled cortical impact in mice. *J Neurotrauma* 2003;20:1307-14.
4. Suzuki N, Suzuki S, Iwabuchi T. Neurological improvement after cranioplasty. Analysis by dynamic CT scan. *Acta Neurochir (Wien)* 1993;122:49-53.
5. Maekawa M, Awaya S, Teramoto A. Cerebral blood flow (CBF) before and after cranioplasty performed during the chronic stage after decompressive craniectomy evaluated by xenon-enhanced computerized tomography (Xe-CT) CBF scanning. *No Shinkei Geka* 1999;27:717-22.
6. Yamaura A, Makino H. Neurological deficits in the presence of the sinking skin flap following decompressive craniectomy. *Neurol Med Chir (Tokyo)* 1977;17 (1 Pt 1):43-53.
7. Wee HY, Kuo JR. Never neglect the atmospheric pressure effect on a brain with a skull defect. *Int Med Case Rep J* 2014;7:67-9.
8. Yoshida K, Furuse M, Izawa A, Iizima N, Kuchiwaki H, Inao S. Dynamics of cerebral blood flow and metabolism in patients with cranioplasty as evaluated by 133Xe CT and 31P magnetic resonance spectroscopy. *J Neurol Neurosurg Psychiatry* 1996;61:166-71.
9. Winkler PA, Stummer W, Linke R, Krishnan KG, Tatsch K. Influence of cranioplasty on postural blood flow regulation, cerebrovascular reserve capacity, and cerebral glucose metabolism. *J Neurosurg* 2000;93:53-61.
10. Chibbaro S, Vallee F, Beccaria K, Poczop P, Makiese O, Fricia M, *et al.* The impact of early cranioplasty on cerebral blood flow and its correlation with neurological and cognitive outcome. Prospective multi-centre study on 24 patients. *Rev Neurol (Paris)* 2013;169:240-8.
11. Sakamoto S, Eguchi K, Kiura Y, Arita K, Kurisu K. CT perfusion imaging in the syndrome of the sinking skin flap before and after cranioplasty. *Clin Neurol Neurosurg* 2006;108:583-5.
12. Wintermark M, Thiran JP, Maeder P, Schnyder P, Meuli R. Simultaneous measurement of regional cerebral blood flow by perfusion CT and stable xenon CT: A validation study. *AJNR Am J Neuroradiol* 2001;22:905-14.

13. Sarubbo S, Latini F, Ceruti S, Chierigato A, d'Esterre C, Lee TY, *et al*. Temporal changes in CT perfusion values before and after cranioplasty in patients without symptoms related to external decompression: A pilot study. *Neuroradiology* 2014;56:237-43.
14. Dupont WD, Plummer WD Jr. Power and sample size calculations for studies involving linear regression. *Control Clin Trials* 1998;19:589-601.
15. Marshall LF. Pediatric traumatic brain injury and elevated intracranial pressure. *J Neurosurg Pediatr* 2008;2:237-8.
16. Aarabi B, Hesdorffer DC, Ahn ES, Aresco C, Scalea TM, Eisenberg HM. Outcome following decompressive craniectomy for malignant swelling due to severe head injury. *J Neurosurg* 2006;104:469-79.
17. Morgalla MH, Will BE, Roser F, Tatagiba M. Do long-term results justify decompressive craniectomy after severe traumatic brain injury? *J Neurosurg* 2008;109:685-90.
18. Stelling H, Graham L, Mitchell P. Does cranioplasty following decompressive craniectomy improve consciousness? *Br J Neurosurg* 2011;25:407-9.
19. Dujovny M, Aviles A, Agner C, Fernandez P, Charbel FT. Cranioplasty: Cosmetic or therapeutic? *Surg Neurol* 1997;47:238-41.
20. Yamaura A, Sato M, Meguro K, Nakamura T, Uemura K. Cranioplasty following decompressive craniectomy – Analysis of 300 cases (author's transl). *No Shinkei Geka* 1977;5:345-53.
21. Stula D. The problem of the “sinking skin-flap syndrome” in cranioplasty. *J Maxillofac Surg* 1982;10:142-5.
22. Segal DH, Oppenheim JS, Murovic JA. Neurological recovery after cranioplasty. *Neurosurgery* 1994;34:729-31.
23. Chibbaro S, Vallee F, Poczos P, Fricia M, Beccaria K, Mateo J, *et al*. The impact of early cranioplasty on cerebral blood flow and metabolism and its correlation with neurological and cognitive outcome: Prospective multi-center study on 34 patients. *Indian J Neurosurg* 2012;1:17.
24. Stiver SI, Wintermark M, Manley GT. Reversible monoparesis following decompressive hemicraniectomy for traumatic brain injury. *J Neurosurg* 2008;109:245-54.
25. Weir J, Steyerberg EW, Butcher I, Lu J, Lingsma HF, McHugh GS, *et al*. Does the extended Glasgow Outcome Scale add value to the conventional Glasgow Outcome Scale? *J Neurotrauma* 2012;29:53-8.
26. Chang V, Hartzfeld P, Langlois M, Mahmood A, Seyfried D. Outcomes of cranial repair after craniectomy. *J Neurosurg* 2010;112:1120-4.
27. Lee CH, Chung YS, Lee SH, Yang HJ, Son YJ. Analysis of the factors influencing bone graft infection after cranioplasty. *J Trauma Acute Care Surg* 2012;73:255-60.
28. Wachter D, Reineke K, Behm T, Rohde V. Cranioplasty after decompressive hemicraniectomy: Underestimated surgery-associated complications? *Clin Neurol Neurosurg* 2013;115:1293-7.
29. Kim H, Sung SO, Kim SJ, Kim SR, Park IS, Jo KW. Analysis of the factors affecting graft infection after cranioplasty. *Acta Neurochir (Wien)* 2013;155:2171-6.
30. Cheng YK, Weng HH, Yang JT, Lee MH, Wang TC, Chang CN. Factors affecting graft infection after cranioplasty. *J Clin Neurosci* 2008;15:1115-9.
31. Cifu DX, Stewart DG. Factors affecting functional outcome after stroke: A critical review of rehabilitation interventions. *Arch Phys Med Rehabil* 1999;80 5 Suppl 1:S35-9.