

Solitary Intraspinal Juvenile Xanthogranuloma in an Infant

Abstract

Juvenile xanthogranuloma (JXG) is a benign, non-Langerhans cell histiocytic proliferative disorder. We report a case of solitary JXG in an infant presenting as an intraspinal mass. Awareness of this mode of presentation is very important as subsequent prognosis differs from other tumors at the same location. JXG is a self-limiting dermatologic disorder usually occurring in first two decades of life. On rare occasion, it has been reported at extra-cutaneous sites such as central nervous system (CNS), eyes, liver, spleen, lungs and kidneys, and in other age groups. Isolated CNS involvement is extremely rare, especially in the spinal cord.

Keywords: Infant, intraspinal, juvenile xanthogranuloma

Introduction

Juvenile xanthogranuloma (JXG) is a benign, non-Langerhans histiocytic proliferative disorder of the skin which mainly occurs in childhood. It is rarely associated with systemic manifestation, and central nervous involvement is extremely rare. Etiology of JXG is not known. We report a case of solitary intraspinal JXG in an infant, presenting as paraplegia which is exceptional. An extensive literature search has revealed only two cases reported in this location in an infant.^[1,2]

Case Report

The mother of a 1-year-old girl initially noticed reduced activity of the lower limbs which worsened over 8 days. On examination paraplegia, exaggerated deep tendon reflexes and positive Babinski sign were noted. No other neurological deficit found. Cutaneous lesions were absent. Magnetic resonance imaging (MRI) of the spine showed intradural extramedullary (IDEM) lesion at D6–D8 level suggestive of a benign nerve sheath tumor [Figure 1].

Total excision of the tumor was done. Gross specimen included multiple bits yellowish-white, soft to firm. Histopathology showed tumor composed of sheets of spherical, ovoid, and spindle cells with vesicular bland nuclei. Many Touton giant cells were seen [Figure 2].

This is an open access article distributed under the terms of the Creative Commons Attribution-NonCommercial-ShareAlike 3.0 License, which allows others to remix, tweak, and build upon the work non-commercially, as long as the author is credited and the new creations are licensed under the identical terms.

For reprints contact: reprints@medknow.com

On immunohistochemistry, the tumor cells were strongly positive for CD68 (histiocytic marker) and weakly for CD163 [Figure 3]. Cells were negative for s100 protein, CD1a, glial fibrillary acidic protein, epithelial membrane antigen. Special stain such as Zeil Neelson, Gomori methenamine silver, and periodic acid-Schiff stain were negative, thus ruling out mycobacteria and fungi as etiologic agents. Thus, a diagnosis of JXG was made. The infant showed full clinical recovery. The patient was managed with regular follow-up only and is doing well until date.

Discussion

In the pediatric age group, dural intraspinal tumors account for about 50% of cases. They include neuroblastomas, Ewing's sarcomas, and more rarely, leukemia, lymphoma, rhabdomyosarcoma or as in our case - JXG.

JXG was first described in 1905 by Adamson as a "congenital xanthoma multiplex."^[1] Histiocytic disorders are further subtyped as (1) dendritic-cell related, (2) macrophage-related, or (3) malignant histiocytic disorders. JXG is an example of a dendritic cell disorder, another being Langerhans cell histiocytosis (LCH). Macrophage-related disorders comprise Rosai-Dorfmann disease (RDD), and hemophagocyte lymphohistiocytosis and Erdheim Chester disease.^[3]

JXG in children are commonly seen at a median age of two years with a male:female

How to cite this article: Shenoy A, Singhal SS, Shinde S. Solitary intraspinal juvenile xanthogranuloma in an infant. *Asian J Neurosurg* 2018;13:172-5.

**Asha Shenoy,
Shruti Shribhagwan
Singhal,
Sweety Shinde**

*Department of Pathology,
Topiwala National Medical
College and B. Y. L. Nair
Hospital, Mumbai, Maharashtra,
India*

Address for correspondence:
Dr. Shruti Shribhagwan Singhal,
C-wing, Flat No. 701,
Sai Shradha Bldg., Phase-1,
Ashokvan, Borivali,
Mumbai - 400 066,
Maharashtra, India.
E-mail: shrutisinglasep@yahoo.
co.in

Access this article online

Website: www.asianjns.org

DOI: 10.4103/1793-5482.180896

Quick Response Code:



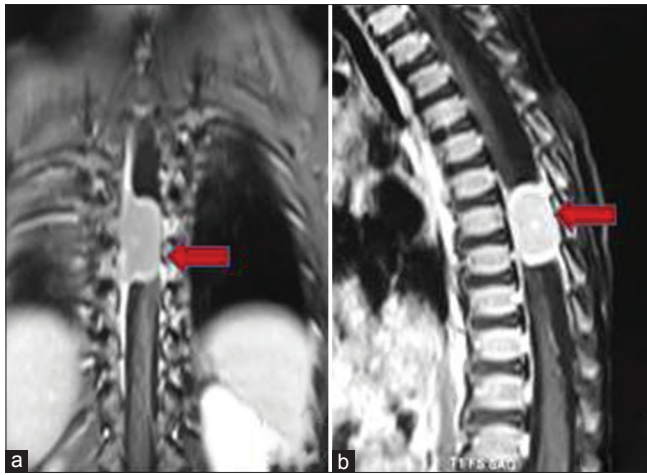


Figure 1: Magnetic resonance imaging T1-weighted post contrast images of dorsal spine coronal (a) images reveal an intradural well defined ovoid lesion along D6 to D8 spine (red block arrows). There is homogenous postcontrast enhancement with hyper enhancing rim. Magnetic resonance imaging T1-weighted postcontrast images of dorsal spine sagittal (b) images reveal an intradural well defined ovoid lesion along D6 to D8 spine (red block arrows). There is homogenous post contrast enhancement with hyper enhancing rim

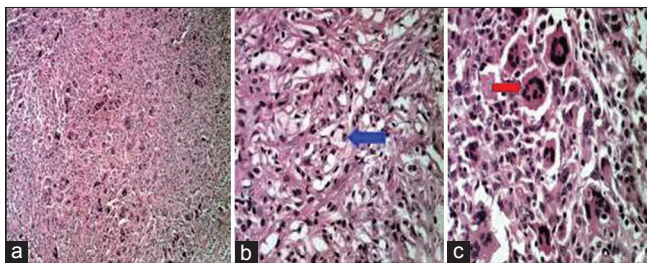


Figure 2: (a) Photomicrograph hematoxylin and eosin stain (x10), showing tumor composed of sheets of spherical, ovoid to spindle shaped cells. (b) xanthoma cells (x40) (blue block arrow). (c) Touton giant cells (x40) (red block arrow)

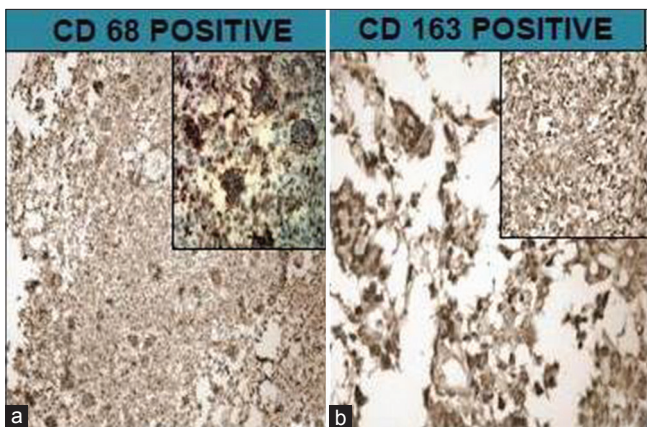


Figure 3: (a) Photomicrograph showing tumor cells positive for CD68 (cytoplasmic stain x10) and with inset, x40. (b) Photomicrograph showing tumor cells positive for CD 163 (membrane stain x10) and with inset, x40

ratio of 1.5:1. The most common sites of cutaneous involvement are on the skin and head. Extracutaneous involvement is uncommon but reported in the uveal tract, oropharynx, heart, lung, liver, and central nervous

system (CNS). The involvement of spine is extremely rare.^[4,5] Until date, only 14 cases have been described in English literature with solitary JXG of the spine.^[2,4,6-17] Table 1 summarizes the details of all the 14 cases. Six of these were in the cervical spine, 3 in the thoracic spine and 5 in the lumbosacral spine. JXG is a slow growing tumor and presents with features according to the location of the tumor. JXG are believed to be the result of altered macrophage response to a nonspecific injury, resulting in a granulomatous reaction. JXG was thought to be a reactive process; however, its clonal nature has recently been demonstrated, and leading credence to its neoplastic origin.^[3]

Spinal JXG presents clinically as an IDEM tumor, as an osteolytic lesion in the vertebral body, with spinal nerve root involvement, or a combination of all these features depending on the location of the tumor.^[3]

MRI is the best method for the localization of tumors and their relationship to adjacent structures. Spinal JXG may appear with variable signal intensity, i.e. a mixture of hypo-, iso-, and hyperintense in T1-weighted (T1W) and T2-weighted (T2W). Furthermore, the lesion may exhibit homogeneous enhancement after contrast media administration. In our case, the tumor showed isointense signal on T1WI and the hypointense signal on T2W with homogeneous contrast enhancement.^[19]

Upon gross anatomic examination, the JXG is a usually well-encapsulated yellowish-to-grayish mass with or without cystic components. Xanthogranuloma is confirmed through histopathological and immunohistochemical (IHC) studies.^[6] Microscopically, there are foamy histiocytic cells with or without Touton giant cells, which can be found in a background of mononuclear cells, and spindle cells. Touton giant cells contain a ring of nuclei surrounding a central homogenous cytoplasm while foamy cytoplasm surrounds the nuclei. On IHC mononuclear cells, giant cells, and spindle cells are positive for the lysozyme stain and CD68 but negative for CD1a (excludes LCH) and S-100 proteins (excludes RDD), as seen in our case.^[7,8,20]

Currently, there is no standard treatment for solitary JXG involving the CNS because of extremely low incidence. Complete surgical resection of the tumor is curative. Recurrence has not been reported. However, the tumors involving the spine may grow slowly without regression and gradually worsens. This characteristic is significantly distinct from the skin lesions which show spontaneous regression. The patient should be followed up for long-term after total resection because the natural course of solitary CNS xanthogranuloma is unknown.^[8]

Conclusion

We report a very rare case of spinal JXG presenting as IDEM tumor.

Table 1: Summary of the reported cases of JXG in the literature

Authors/years	Age/sex	Clinical features	Location	Surgery	Outcome
Shimosawa <i>et al.</i> 1993 ^[13]	13 months/female	Spastic paraparesis	T6-9 IDEM	T6-T9 laminectomy with tumor excision	Improved
Kitchen <i>et al.</i> 1995 ^[14]	15 years/female	Low back pain	S1 nerve root	L5 laminectomy with total excision	Improved
Kim <i>et al.</i> 1996 ^[10]	16 months/female	Paraparesis	T1-2 IDEM	C7-T3 laminectomy with excision of tumor	Resolution by 4 months
Iwasaki <i>et al.</i> 2001 ^[18]	41 years/female	Weakness and numbness in both lower limbs	Cauda equina	L1-L5 laminectomy with tumor excision	Not mentioned
Rampini <i>et al.</i> 2001 ^[8]	34 years/female	Spastic paraparesis	C5-7 IDEM	C5-T1 laminectomy with total excision of tumor	Improved
Dehner 2003 ^[9]	14 years/female	Back pain	L3 vertebral body	Not mentioned	Not mentioned
Cao <i>et al.</i> 2008 ^[4]	18 years/female	Neck pain	C2 root	C1-2 laminectomy with	No recurrence at 2 years
Castro-Gago <i>et al.</i> 2009 ^[6]	14 years/male	Paraparesis	Cauda equine	L2-3 laminectomy with partial excision	Postoperative RT, no recurrence at 2 years
Lee <i>et al.</i> 2011 ^[15]	29 years/male	Hemiparesis with contralateral hypoesthesia below C2	C1-2	C1-2 laminectomy with total excision of tumor	Improved
Jain <i>et al.</i> 2011 ^[16]	22 years/female	Progressive back pain	T7 vertebral body	T7 laminectomy with tumor excision	Improved
Agabegi <i>et al.</i> 2011 ^[12]	47 years/female	Bowel, bladder involvement and back pain	L2 vertebral body	T12-L3 laminectomy with partial excision	Postoperative RT, improved at 8 months
Inoue <i>et al.</i> 2011 ^[7]	38 years/male	Numbness and weakness of right hand	C8 nerve	C7-T1 laminectomy	No recurrence at 2 years
Bhaisora <i>et al.</i> 2013 ^[17]	16 years/male	Spastic quadriparesis with neck pain	C5-6	Anterior cervical approach with tumor excision	Improved with no recurrence at 6 months
Singhvi and Bhargava 2014 ^[2]	9 month/male	Bilateral lower limb weakness	C4-5	Total excision	Asymptomatic at 1 year
Present case, 2014	1 year/female	Paresis of lower limbs	D6-8	Total excision	Improved

IDEM – Intradural extramedullary; RT – Radiotherapy; JXG – Juvenile xanthogranuloma

Total excision of the tumor is the treatment of choice. It is important to distinguish these tumors from other histiocytic disorders pathologically such as LCH, as they may require more aggressive treatment in contrast to the benign nature of JXG.

Financial support and sponsorship

Nil.

Conflicts of interest

There are no conflicts of interest.

References

- Wille DA, Bozinov O, Scheer I, Grotzer MA, Boltshauser E. Isolated intraspinal juvenile xanthogranuloma in an infant presenting as acute paraplegia. *Neuropediatrics* 2013;44:171-3.
- Singhvi S, Bhargava S. Isolated juvenile xanthogranuloma in thoracic spine: Intraoperative cytological diagnosis of a rare presentation. *J Interdiscipl Histopathol* 2014;2:158-62.
- Konar S, Pandey P, Yasha TC Solitary juvenile xanthogranuloma in cervical spine: Case report and review of the literature. *Turk Neurosurg* 2014;24:102-7.
- Cao D, Ma J, Yang X, Xiao J. Solitary juvenile xanthogranuloma in the upper cervical spine: Case report and review of the literatures. *Eur Spine J* 2008;17 Suppl 2:S318-23.
- Janssen D, Harms D. Juvenile xanthogranuloma in childhood and adolescence: A clinicopathologic study of 129 patients from the kiel pediatric tumor registry. *Am J Surg Pathol* 2005;29:21-8.
- Castro-Gago M, Gómez-Lado C, Alvez F, Alonso A, Vieites B. Juvenile xanthogranuloma of the cauda equina. *Pediatr Neurol* 2009;40:123-5.
- Inoue H, Seichi A, Yamamuro K, Kojima M, Kimura A, Hoshino Y. Dumbbell-type juvenile xanthogranuloma in the cervical spine of an adult. *Eur Spine J* 2011;20 Suppl 2:S343-7.
- Rampini PM, Alimehmeti RH, Egidi MG, Zavanone ML, Bauer D, Fossali E, *et al.* Isolated cervical juvenile

- xanthogranuloma in childhood. *Spine (Phila Pa 1976)* 2001;26:1392-5.
9. Dehner LP. Juvenile xanthogranulomas in the first two decades of life: A clinicopathologic study of 174 cases with cutaneous and extracutaneous manifestations. *Am J Surg Pathol* 2003;27:579-93.
 10. Kim DS, Kim TS, Choi JU. Intradural extramedullary xanthoma of the spine: A rare lesion arising from the dura mater of the spine: Case report. *Neurosurgery* 1996;39:182-5.
 11. Adamson NF. Congenital xanthoma multiplex in a child. *Br J Dermatol* 1905;17:222-3.
 12. Agabegi SS, Iorio TE, Wilson JD, Fischgrund JS. Juvenile xanthogranuloma in an adult lumbar spine: A case report. *Spine (Phila Pa 1976)* 2011;36:E69-73.
 13. Shimosawa S, Tohyama K, Shibayama M, Takeuchi H, Hirota T. Spinal xanthogranuloma in a child: Case report. *Surg Neurol* 1993;39:138-42.
 14. Kitchen ND, Davies MS, Taylor W. Juvenile xanthogranuloma of nerve root origin. *Br J Neurosurg* 1995;9:233-7.
 15. Lee SJ, Jo DJ, Lee SH, Kim SM. Solitary xanthogranuloma of the upper cervical spine in a male adult. *J Korean Neurosurg Soc* 2012;51:54-8.
 16. Jain A, Mathur K, Khatri S, Kasana S, Jain SK. Rare presentation of juvenile xanthogranuloma in the thoracic spine of an adult patient: Case report and literature review. *Acta Neurochir (Wien)* 2011;153:1813-8.
 17. Bhaisorra KS, Jaiswal AK, Mehrotra A, Sahu RN, Srivastava A, Jaiswal S, *et al.* Solitary juvenile xanthogranuloma of the cervical spine in a child: A case report and review of literature. *Asian J Neurosurg* 2015;10:57.
 18. Iwasaki Y, Hida K, Nagashima K. Cauda equina xanthogranulomatosis. *Br J Neurosurg* 2001;15:72-3.
 19. Kim SY, Park HJ, Lee SY, Chung EC, Park HW, Kook SH, *et al.* MRI findings of juvenile xanthogranuloma of the spinal cord: A case report. *J Korean Soc Radiol* 2013;68:251-5.
 20. Bhambri S, James Q, Del R, Paul J. Juvenile xanthogranuloma: Case report and review of literature. *Cosmetic Dermatol* 2008;21:21-24.