

## Case Report

## Thoracic Intramedullary Lipoma in a 3-year-old Child: Spontaneous Decrease in the Size Following Incomplete Resection

### Abstract

Nondysraphic intramedullary spinal cord lipomas are even rarer. We present a thoracic intramedullary lipoma which spontaneously decreased in size following surgical debulking. A 3-year-old girl was admitted to our department with complaints of back pain since 1 year and progressive difficulty in walking since 6 months. Her magnetic resonance imaging (MRI) revealed T8-9 intramedullary mass showing increased signal intensity in both T1- and T2-weighted images. The patient was operated with a T8-9 laminoplasty and debulking, and internal decompression of the tumor was made. Histologically, the tumor was uniformly composed of mature adipose tissue revealing a lipoma. First-month control MRI revealed the rest mass almost the half volume of the preoperative mass. The 2<sup>nd</sup> year MRI revealed the size of the lipoma was spontaneously decreased to almost half of postoperative size and 3<sup>rd</sup> year was the same as the 2<sup>nd</sup> year with a mild kyphosis. Decompression and debulking with or without duraplasty is the most appropriate treatment for symptomatic patients. Dietary measures with control of fat intake and long-term follow-up are also suggested.

**Keywords:** Intramedullary, lipoma, spontaneous decrease

### Introduction

Intraspinal lipomas are rare neoplasms accounting for <1% of all spinal cord tumors. Nondysraphic intramedullary spinal cord lipomas are even rarer.<sup>[1-4]</sup> They are believed to be hamartomas occurring as a result of disordered embryogenesis, therefore, the fat tissue of intraspinal lipomas behave according to the general fat metabolism of the patient.<sup>[1,5]</sup> We present a 3-year-old girl with a thoracic intramedullary lipoma which spontaneously decreased in size following surgical debulking.

### Case Report

A 3-year-old girl was admitted to our department with complaints of back pain since 1 year and progressive difficulty in walking since 6 months. Her mother declared she had been aware of spasticity in lower extremities since 6 months and for the last few weeks, she was unable to walk independently and had urinary incontinence. Her neurological examination revealed spastic paraparesis and bilateral extensor Babinski signs and bilateral clonus of the ankles. Her magnetic

resonance imaging (MRI) revealed T8-9 intramedullary mass showing increased signal intensity in both T1- and T2-weighted images [Figure 1]. The patient was operated with a T8-9 laminoplasty and debulking and internal decompression of the tumor was made. Complete resection was not attempted as there was no plane of cleavage between the cord and the tumor. The dura was easily closed primarily without using a graft. Histologically, the tumor was uniformly composed of mature adipose tissue revealing a lipoma. Postoperative period was uneventful and neurological status of the patient get better immediately following surgery. She was mobilized with aid on the postoperative 3<sup>rd</sup> day and at the 1<sup>st</sup> month follow-up visit she was walking independently with a sequela of right ankle spasticity. First month control MRI revealed the rest mass almost the half volume of the preoperative mass. No strict dietary measures were taken but her mother was told to be careful about the weight gain of the patient as this might have the potential of increasing the tumor size. The 1<sup>st</sup> year MRI was almost the same and neurological status was same. The 2<sup>nd</sup> year MRI revealed the size of the lipoma was spontaneously decreased to almost half of postoperative size and 3<sup>rd</sup> year was the same as the

### Cem Yilmaz, Fatih Aydemir<sup>1</sup>

Department of Neurosurgery,  
Faculty of Medicine, Ankara  
Practice and Research Center,  
Baskent University, Ankara,  
<sup>1</sup>Department of Neurosurgery,  
Medical Park Hospital,  
Bursa, Turkey

#### Address for correspondence:

Dr. Fatih Aydemir,  
Department of Neurosurgery,  
Medical Park Hospital,  
Haşim İşcan Caddesi Fomara  
Meydanı No: 1  
Osmangazi/Bursa, Turkey.  
E-mail: md.fatihaydemir@gmail.  
com

#### Access this article online

Website: [www.asianjns.org](http://www.asianjns.org)

DOI: 10.4103/1793-5482.180965

#### Quick Response Code:



**How to cite this article:** Yilmaz C, Aydemir F. Thoracic intramedullary lipoma in a 3-year-old child: Spontaneous decrease in the size following incomplete resection. *Asian J Neurosurg* 2018;13:188-90.

This is an open access article distributed under the terms of the Creative Commons Attribution-NonCommercial-ShareAlike 3.0 License, which allows others to remix, tweak, and build upon the work non-commercially, as long as the author is credited and the new creations are licensed under the identical terms.

For reprints contact: [reprints@medknow.com](mailto:reprints@medknow.com)

2<sup>nd</sup> year with a mild kyphosis [Figure 2]. The patients were observed to gain weight at the lower limit compared to charts of healthy children at this 3 years period.

## Discussion

Nondysraphic intramedullary spinal cord lipomas are rare, and their management is challenging. Almost all authors emphasize that attempts at radical resection are bound to produce significant morbidity as no clear cleavage plane exists between lipoma and spinal cord.<sup>[1,2]</sup> Furthermore the spinal cord is fragile, and lipoma may encase the neural tissues. Therefore debulking and decompression of the spinal cord are usually advised to be the most appropriate surgical treatment for the symptomatic patients. Sharp dissection with microsurgical technique is useful and carbon dioxide laser, and ultrasonographic aspiration can be used if present and additional duraplasty is also advocated by some authors.<sup>[1]</sup>

Continuous intraoperative electrophysiological monitoring is another useful tool to perform safer and more extensive debulking of intramedullary lipomas.<sup>[2,6,7]</sup> Pang *et al.* reported that intraoperative electrophysiological monitoring is the sine qua non in lipoma surgery for total/near-total resection which they believe produce a much better long-term progression-free survival than partial resection.<sup>[8]</sup> They compared long-term outcome of 315 total or near-total resection and 116 partial lipoma resection and concluded that total or near-total resection achieves better long-term protection than partial resection for spinal lipomas related to dysraphism. Yet for the nondysraphic lipomas most authors agree that total resection is not related to a better outcome and even probably worsen neurologic deficit, therefore, surgical debulking and decompression is enough for stabilizing the patients neurologically.<sup>[2,6,7]</sup>

The pathogenesis of intramedullary lipomas suggests a maldevelopmental process at the stage of cleavage of

germ cell layers. Therefore they are considered to be nonneoplastic tissue, indeed they are believed to be truly hamartomas which behave according to the general fat metabolism of the patient.<sup>[1,5]</sup> Giudicelli *et al.* in their study compared the metabolic characteristics of congenital intraspinal lipoma cells with normal adipocytes and found out that they are identical which supports the idea that intraspinal lipomas can increase or decrease in size in accordance with the rest of the fatty pool.<sup>[9]</sup>

The hamartomatous behavior of the fat of the lipoma had been supported by the observation of the growth of lipoma in patients with an increase in body fat and by also reports of a decrease in the size of the lipoma by weight loss.<sup>[10-12]</sup> This brings the idea of suggesting dietary measures to reduce body fat to reduce the size of a lipoma, but this approach is questioned by some those who have observed a rapid lipoma growth.<sup>[13,14]</sup>

In our case, we performed decompression by debulking of the lipoma and at the follow-up period we realized a spontaneous decrease in the size of the lipoma. We think this may be due to grow patients gaining weight at the lower limit compared to charts of healthy children.

## Conclusion

Nondysraphic intramedullary spinal cord lipomas are hamartomas that have the potential of changing size according to the general fat metabolism of the patient. As complete resection have the serious risk of irreversible neural damage, decompression and debulking with or without duraplasty is the most appropriate treatment for symptomatic patients. Dietary measures with control of fat intake and long-term follow-up are also suggested.

## Financial support and sponsorship

Nil.

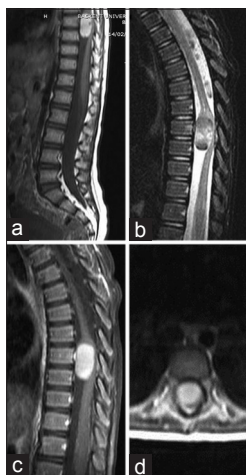

Figure 1: Magnetic resonance imaging revealed T8-9 intramedullary mass showing increased signal intensity in both T1-weighted (a), T2-weighted (b) weighted images and contrast enhanced T1-weighted sagittal (c), axial (d) weighted images

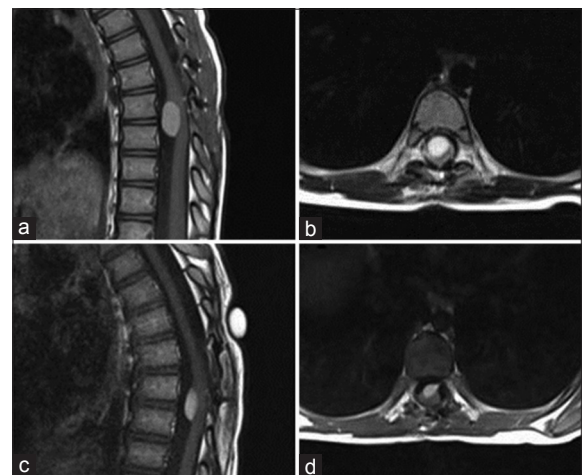


Figure 2: First month control magnetic resonance imaging revealed the rest mass almost the half volume of the preoperative mass (a and b), the 3<sup>rd</sup> year magnetic resonance imaging revealed the size of the lipoma half of postoperative size (c and d)

## Conflicts of interest

There are no conflicts of interest.

## References

1. Klekamp J, Fusco M, Samii M. Thoracic intradural extramedullary lipomas. Report of three cases and review of the literature. *Acta Neurochir (Wien)* 2001;143:767-73.
2. Son DK, Son DW, Choi CH, Song GS. Regrowth of cervical intradural lipoma without spinal dysraphism. *J Korean Neurosurg Soc* 2014;56:157-61.
3. O'Grady J, Kaliaperumal C, O'Sullivan M. Recurrent 'universal tumour' of the spinal cord. *BMJ Case Rep* 2012;2012. pii: bcr1220115284.
4. Lee M, Rezai AR, Abbott R, Coelho DH, Epstein FJ. Intramedullary spinal cord lipomas. *J Neurosurg.* 1995;82:394-400.
5. Takeyama J, Hayashi T, Saito M, Shimanuki Y, Watanabe M, Sasano H, *et al.* Spinal hamartoma associated with spinal dysraphism. *Childs Nerv Syst* 2006;22:1098-102.
6. Naim-ur-Rahman, Shahat AH, Obaideen AM, Ahmed K, Ahmed S. Intramedullary lipoma of the cervicodorsal spinal cord with intracranial extension: Case report. *Surg Neurol* 2006;65:486-9.
7. El Mostarchid B, Ali A, Maftah M, Mansouri A, Laghzioui J, Kadiri B, *et al.* Non-dysraphic intramedullary spinal cord lipoma. A case report. *Joint Bone Spine* 2002;69:511-4.
8. Pang D, Zovickian J, Wong ST, Hou YJ, Moes GS. Surgical treatment of complex spinal cord lipomas. *Childs Nerv Syst* 2013;29:1485-513.
9. Giudicelli Y, Pierre-Kahn A, Bourdeaux AM, de Mazancourt P, Lacasa D, Hirsch JF. Are the metabolic characteristics of congenital intraspinal lipoma cells identical to, or different from normal adipocytes? *Childs Nerv Syst* 1986;2:290-6.
10. Endoh M, Iwasaki Y, Koyanagi I, Hida K, Abe H. Spontaneous shrinkage of lumbosacral lipoma in conjunction with a general decrease in body fat: Case report. *Neurosurgery* 1998;43:150-1.
11. Akyuz M, Goksu E, Tuncer R. Spontaneous decrease in the size of a residual thoracic intradural lipoma. *Br J Neurosurg* 2005;19:53-5.
12. Agraharkar A, McGillicuddy G, Ahuja T, Agraharkar M. Growth of intramedullary lipoma in a renal transplant recipient. *Transplantation* 2000;69:1509-11.
13. Kim KH, Lee YH, Park YS, Kim DS. Rapidly regrowing lipoma in lipomeningomyelocele: A case report. *Childs Nerv Syst* 2009;25:1149-51.
14. Aoki N. Rapid growth of intraspinal lipoma demonstrated by magnetic resonance imaging. *Surg Neurol* 1990;34:107-10.