

Nontraumatic Subdural Hematoma and Intracystic Hemorrhage Associated with a Middle Fossa Arachnoid Cyst

Abstract

Intracranial arachnoid cysts (ACs) are relatively common findings that can be seen in up to 2% of patients. They are generally found incidentally with a benign clinical course and can be usually managed by observation. We report an unusual case of a middle fossa AC presenting with spontaneous intracystic hemorrhage along with subdural hematoma (SDH) causing significant mass effect and midline shift requiring surgical treatment. Even though the risk of hemorrhage in patients with AC is very low, the presence of AC is a known risk factor for SDH. Fortunately, the clinical outcome of patients who present with hemorrhage associated with AC is generally favorable with early recognition and prompt surgical treatment. Our case highlights the fact that both intracystic hemorrhage and SDH can occur in association with AC even in the absence of trauma and should be kept in mind when counseling patients with incidental AC about the natural history of these lesions.

Keywords: Arachnoid cyst, hemorrhage, intracystic hemorrhage, spontaneous, subdural hematoma, trauma

Introduction

Arachnoid cysts (ACs) are congenital cerebrospinal fluid (CSF) filled cavities circumscribed by arachnoidal membrane that have settled in the cisternae and major cerebral fissures.^[1] These lesions are usually asymptomatic and often diagnosed incidentally on cranial radiological work-up for unrelated reasons.^[2] When symptomatic, they usually present with symptoms of raised intracranial pressure or may present with abnormal head shape, seizures, and focal neurological deficits in children. Hemorrhage within AC with associated subdural or epidural hematoma though known is rare and usually occurs following trauma.^[3-9] The increasing availability and the wide utilization of modern imaging modalities have led to an increased number of incidentally diagnosed AC with a prevalence up to 2.6%.^[1] Understanding the natural history of such incidentally diagnosed lesions is important to obviate unnecessary treatment. Though often considered controversial, recent reports point toward a benign natural course arguing in favor of conservative management in both children and adults. While patients with AC can present with nonspecific symptoms, hemorrhage

associated with AC is an uncommon but serious complication that often require surgical treatment. Hemorrhage associated with AC can be intracystic or subdural and is usually associated with trauma.^[10] We report a rare case of spontaneous intracystic and subdural hemorrhage (SDH) associated with an AC to highlight the fact that both intracystic hemorrhage and SDH can occur even in the absence of trauma in patients with ACs.

Case Report

A 47-year-old previously healthy male presented to our Emergency Department with complaints of 1 week of progressive headaches and 3 days of dizziness, unsteady gait, nausea, and emesis. He reported no history of head trauma. There patient was not on any anticoagulants or antiplatelet. On admission, his neurological exam was unremarkable. A computed tomography (CT) of the brain demonstrated a large left-sided SDH with significant mass effect and midline shift. Magnetic resonance imaging (MRI) demonstrated a separate collection along the left sphenoid wing of the lateral ventricle, consistent with an AC with intracystic blood and surrounding SDH [Figure 1]. Craniotomy and evacuation

**Megan Christine Kaszuba,
Lee Ang Tan,
Roham Moftakhar,
Manish Kumar Kasliwal**

*Department of Neurosurgery,
Rush University Medical Center,
Chicago, IL, USA*

Address for correspondence:
Dr. Manish Kumar Kasliwal,
Department of Neurosurgery,
Rush University Medical Center,
Chicago, IL-60612, USA.
E-mail: manish_kasliwal@rush.edu

Access this article online

Website: www.asianjns.org

DOI: 10.4103/1793-5482.181124

Quick Response Code:



How to cite this article: Kaszuba MC, Tan LA, Moftakhar R, Kasliwal MK. Nontraumatic subdural hematoma and intracystic hemorrhage associated with a middle fossa arachnoid cyst. *Asian J Neurosurg* 2018;13:116-8.

This is an open access article distributed under the terms of the Creative Commons Attribution-NonCommercial-ShareAlike 3.0 License, which allows others to remix, tweak, and build upon the work non-commercially, as long as the author is credited and the new creations are licensed under the identical terms.

For reprints contact: reprints@medknow.com

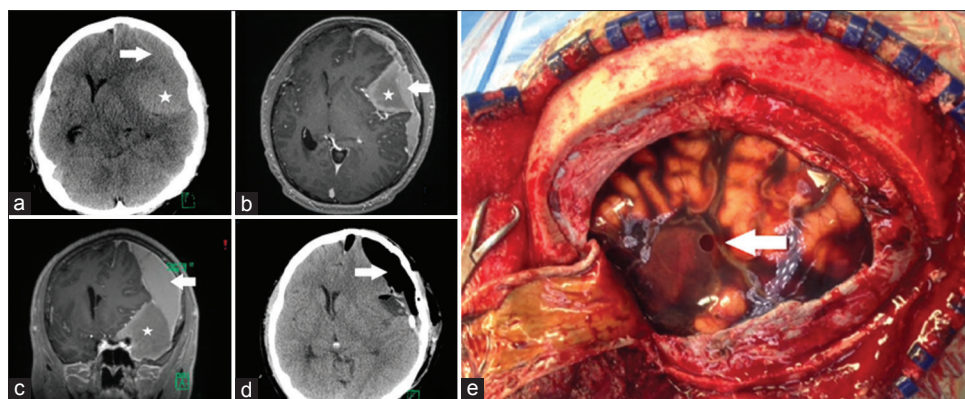


Figure 1: Noncontrast computed tomography and magnetic resonance imaging of the brain demonstrating a large subdural hematoma (arrow in images) (a-c) along with a separate collection 3.7 cm in width along the left sphenoid wing of the lateral ventricle, (star in images) (a-c) consistent with an arachnoid cyst with intracystic blood and surrounding subdural hematoma. (d) Postoperative computed tomography demonstrating interval improvement in midline shift following the evacuation of the hematoma. (e) Intraoperatively, a middle cranial fossa arachnoid cyst with significant hemorrhage and a small hole (arrow) communicating with the subdural space were visualized

of the SDH and intracystic hemorrhage were performed. Upon opening the dura, acute, and subacute SDH was visualized. A middle cranial fossa AC with significant hemorrhage and a small hole communicating with the subdural space was visualized. [Figure 1]. Postoperative CT demonstrated interval improvement in midline shift following the evacuation of the hematoma [Figure 1]. The patient was discharged home and was neurologically intact at follow-up with complaints of occasional left-sided headaches.

Discussion

Prevalence of AC is estimated at 0.3–1.7% in adults and 2.6% in children.^[1] The middle cranial fossa is the most common location and tends to be the one which is generally symptomatic as compared to those occurring at other locations.^[1,3,5,7] Though often incidental, AC can present with a myriad of symptoms.^[1,2,5,7,8]

AC is known to cause chronic SDH, as well as acute SDH after trauma. Hemorrhage may result from decreased compliance of the cyst wall or magnification of pressure changes related to CSF flow in the cyst following minor traumas, leading to rupture of bridging veins in the cyst wall.^[6,7,9] While pathogenesis of AC formation is not completely understood, lesions may arise from small developmental anomalies within the arachnoid membrane.^[3,4] These anomalies may predispose to SDH formation by altering the normal interaction of the arachnoid with dural border cells, thus predisposing to bleeding into this potential space.^[4] Prior studies have suggested the presence of abnormal vasculature surrounding AC with hematoma formation resulting from rupture of bridging veins and fragile vessels overlying or floating within the cyst.^[7,9] Histological studies of AC membranes, which are lined with mesothelial cells,^[3,5] have demonstrated that blood products filter through the cyst membrane, suggesting that frank blood within an AC is an

indicator of tears in the membrane.^[7] However, case series reports indicate hematomas visualized grossly both within and outside the cyst membrane.^[9]

Although head injury is generally considered important to the pathophysiological mechanism of hematoma formation,^[4] this case illustrates an example of hemorrhage and hematoma formation with no known inciting trauma. AC is an important consideration in a young- or middle-aged adult patient presenting with chronic SDH after minor trauma, as hematoma formation following minor trauma is uncommon except at the extremes of age.^[7] Patients with AC may benefit from avoidance of sports or activities with increased risk for head trauma.^[6] While few patients with these lesions go on to become symptomatic or require surgery, the risk of hemorrhage into the cyst or surrounding brain is present and must not be ignored when counseling patients on the potential clinical course of the AC. When hemorrhage is present, symptoms are often due to mass effect from the hematoma rather than from the AC itself.^[4] Treatment options for AC with SDH include open craniotomy with cyst fenestration as was used in this case, cystoperitoneal shunt, endoscopic cyst fenestration, burr hole drainage, and drainage of the hematoma without intervention on the cyst.^[2-4,7] However, recurrence of the hematoma may be more likely in cases in which the cyst is not fenestrated or fully opened or removed.^[7]

The natural course for most AC lesions is benign, and surgical intervention is generally not required.^[1-3] In cases in which an AC is clearly responsible for a patient's symptoms, many authors support surgical management.^[2] Hemorrhage into cysts is possible but is likely a rare event, especially when considering the prevalence of these lesions in the general population.^[1,2] Outcome following surgery in patients who does present with hemorrhage is universally benign and should favor nonsurgical management in patients who are otherwise asymptomatic.

Conclusions

AC is frequently discovered lesions on neuroimaging with prevalence up to 2.6% in the general population. Watchful observation is the preferred course of management in these benign lesions, which infrequently present with focal neurological findings or hemorrhage. While AC generally follow a benign course, patients should be counseled on the possibility of future surgery for treatment of complications including hemorrhage. As in this case, reported outcomes of surgical management are universally benign.

Financial support and sponsorship

Nil.

Conflicts of interest

There are no conflicts of interest.

References

1. Al-Holou WN, Terman S, Kilburg C, Garton HJ, Muraszko KM, Maher CO. Prevalence and natural history of arachnoid cysts in adults. *J Neurosurg* 2013;118:222-31.
2. Al-Holou WN, Yew AY, Boomsaad ZE, Garton HJ, Muraszko KM, Maher CO. Prevalence and natural history of arachnoid cysts in children. *J Neurosurg Pediatr* 2010;5:578-85.
3. Bilginer B, Onal MB, Oguz KK, Akalan N. Arachnoid cyst associated with subdural hematoma: Report of three cases and review of the literature. *Childs Nerv Syst* 2009;25:119-24.
4. Domenicucci M, Russo N, Giugni E, Pierallini A. Relationship between supratentorial arachnoid cyst and chronic subdural hematoma: Neuroradiological evidence and surgical treatment. *J Neurosurg* 2009;110:1250-5.
5. Iaconetta G, Fusco M, Cavallo LM, Cappabianca P, Samii M, Tschabitscher M. The abducens nerve: Microanatomic and endoscopic study. *Neurosurgery* 2007;61 3 Suppl: 7-14.
6. Kertmen H, Gürer B, Yilmaz ER, Sekerci Z. Chronic subdural hematoma associated with an arachnoid cyst in a juvenile taekwondo athlete: A case report and review of the literature. *Pediatr Neurosurg* 2012;48:55-8.
7. Kwak YS, Hwang SK, Park SH, Park JY. Chronic subdural hematoma associated with the middle fossa arachnoid cyst: Pathogenesis and review of its management. *Childs Nerv Syst* 2013;29:77-82.
8. Seddighi A, Seddighi AS, Baqdashti HR. Asymptomatic presentation of huge extradural hematoma in a patient with arachnoid cyst. *Br J Neurosurg* 2012;26:917-8.
9. Takayasu T, Harada K, Nishimura S, Onda J, Nishi T, Takagaki H. Chronic subdural hematoma associated with arachnoid cyst. Two case histories with pathological observations. *Neurol Med Chir (Tokyo)* 2012;52:113-7.
10. Pascoe HM, Phal PM, King JA. Progressive post traumatic tearing of an arachnoid cyst membrane resulting in intracystic and subdural haemorrhage. *J Clin Neurosci* 2015;22:897-9.