

Management of Obstructive Hydrocephalus in Pregnant Patient

Abstract

De novo obstructive hydrocephalus is a rare event during pregnancy. There are only case reports presented in literature. We aimed to discuss the pathophysiological basis and management options with an exemplary case presentation and review of the current literature. A 28-year-old G2P1 patient presented to our clinic with headache, vomiting, and deteriorated vision at the 8th week of gestation. She had no history of central nervous system infection or trauma. A brain magnetic resonance imaging was obtained. There was hydrocephalus due to cerebral aqueduct stenosis (Evan's index of 58%). She was managed conservatively with bed rest and diuretics; however, she got no relief. A ventriculoperitoneal shunt was inserted at the 13th week of gestation. At the 38th week, she had cesarean section (C/S) due to previous history of C/S in the first pregnancy and present cord entanglement of the fetus. C/S was conducted under epidural anesthesia after conforming she had no increased intra cranial pressure findings. Delivery was uneventful with a healthy newborn. Obstructive hydrocephalus is a very rare complication during pregnancy. Hydrocephalus becomes obvious and necessitates treatment, before the third trimester of pregnancy. Timely diagnosis, especially differentiation from preeclampsia, is a life-saving step. If no complication happens during intervention for hydrocephalus, spontaneous vaginal delivery is a safe way of delivery for both mother's and newborn's well-being. C/S should be saved for obstetrical indications and can be conducted under epidural anesthesia if intracranial pressure is kept under control. Interdisciplinary approach of neurosurgeons and anesthesiologists is pivotal for delicate care of the patient and the baby.

Keywords: *Delivery, hydrocephalus, pregnancy, ventriculoperitoneal shunt*

Introduction

Hydrocephalus is a neurosurgical disorder with major constraints both in pediatric and adult population.^[1] Prevalence of hydrocephalus is 0.9–1.2/1.000.^[2] There are two subtypes as communicating and noncommunicating (obstructive) hydrocephalus. *De novo* obstructive hydrocephalus developing during pregnancy is a rarely reported event. There are only case reports presented in literature [Table 1].^[3-14] We aimed to discuss the pathophysiological basis and management options for obstructive hydrocephalus diagnosed during pregnancy with an illustrative case presentation and review of the current literature.

Case Report

A 28-year-old G2P1 patient presented to our clinic with headache, vomiting, and deteriorated vision at the 8th week of gestation. At her admission, fundoscopic

examination revealed papilledema and optic atrophy. She had no history of central nervous system infection or trauma. A brain magnetic resonance (MR) imaging was obtained. There was hydrocephalus due to cerebral aqueduct stenosis (Evan's index of 58%) [Figure 1]. She was managed conservatively with bed rest and diuretics; however, she got no relief. A ventriculoperitoneal (VP) shunt was inserted at the 13th week of gestation. Third generation cephalosporin was given to patient I.V. during shunt procedure. The surgery was uneventful, and she recovered completely in a stepwise manner after the surgery. Her fundoscopic findings regressed in follow-ups. At the 38th week, she had a cesarean section (C/S) due to the previous history of C/S in the first pregnancy and present cord entanglement of the fetus. C/S was conducted under epidural anesthesia after conforming she had no increased intracranial pressure (ICP) findings. Delivery was uneventful with a healthy newborn. Ampicillin and gentamicin were given for 48 h after the delivery.

This is an open access article distributed under the terms of the Creative Commons Attribution-NonCommercial-ShareAlike 3.0 License, which allows others to remix, tweak, and build upon the work non-commercially, as long as the author is credited and the new creations are licensed under the identical terms.

For reprints contact: reprints@medknow.com

How to cite this article: Eksi MS, Öğrenci A, Batçık OE, Koban O. Management of obstructive hydrocephalus in pregnant patient. *Asian J Neurosurg* 2018;13:123-7.

**Murat Şakir Ekşi,
Ahmet Öğrenci¹,
Osman Ersegun
Batçık²,
Orkun Koban³**

Department of Orthopedic Surgery, University of California at San Francisco, San Francisco, CA, USA, ¹Department of Neurosurgery, Batman State Hospital, Batman, ²Department of Neurosurgery, Recep Tayyip Erdoğan University, Rize, ³Department of Neurosurgery, Goztepe Medical Park, Istanbul, Turkey

Address for correspondence:

*Dr. Murat Şakir Ekşi,
Department of Orthopedic Surgery, University of California at San Francisco,
500 Parnassus Avenue,
MU320 West, San Francisco,
CA 94143-0728, USA.
E-mail: muratsakireksi@gmail.com*

Access this article online

Website: www.asianjns.org

DOI: 10.4103/1793-5482.181127

Quick Response Code:



Table 1: Literature review of patients with hydrocephalus developed during their pregnancies

Authors/year	Age (years)	Presentation	Mode of treatment	Time of treatment*	Delivery method	Complications	Notes
Monfared et al. (1979)	25	Headache, nausea, vomiting	VA	27	SVD	None	-
Howard and Herrick (1981)	25	N/A	VP	12	SVD	None	Ampicillin/gentamicin given at time of labor and delivery
Nugent and Hoshek (1986)	30	Headache, nausea, depressed sensorium	VP	7	SVD	Shunt displacement (extra-abdominal)	Extra-abdominal cyst formation 3 weeks postpartum
Wisoff et al. (1991)	N/A	N/A	VPL	In last 2 trimester**	C/S	None	She was operated for posterior fossa mass lesion after delivery
Naidoo and Bhigjee (1998)	26	Headache, vomiting, neck pain, diplopia, inability to walk	VP (with resection of posterior fossa hemangioblastoma)	7	C/S	Symptoms worsened 3 months later with increase in tumor size	She recovered after delivery and tumor size decreased with stable follow-up
Suarez and Iannucci (1999)	21	Headache, vomiting, deterioration of consciousness	Ventriculostomy (switched to VP after delivery)	33.5	SVD	VP shunt dysfunction 4 months later	Neurocysticercosis diagnosed and treated with albendazole and prednisone. VP shunt was revised due to its obstruction
Beni-Adani et al. (2001)	24	Headache, papilledema, ataxia, multiple cranial nerve weakness	VP	35	C/S	None	She was operated for vestibular schwannoma after delivery
Bharti et al. (2002)	27	Headache, nausea, vertigo, hearing impairment, blurred vision	VP	30	C/S	Symptoms resolved after surgery, yet worsened 2 weeks later and delivery of baby done with recovery of symptoms	Radiation therapy was planned for posterior fossa meningioma
Chopra et al. (2004)	25	Headache, nausea, vomiting, blurred vision	VP	25	N/A	VP shunt dysfunction 4 months later	Stereotactic biopsy of bilateral thalamic lesion revealed to be Grade II astrocytoma. VP shunt revision due to knot formation in the peritoneal part of VP shunt
Watanabe et al. (2005)	39	Headache, nausea, deterioration of consciousness	E3V (after ventricular drainage)	19***	C/S	None	-
Riffaud et al. (2006)	36	Headache, memory disturbance	E3V	28	C/S (spinal anesthesia)	None	She was operated for temporal lobe cavernoma and tectal plate glioma (Grade I) after delivery
	22	Headache, vomiting, seizure	E3V	8	C/S (general anesthesia)	None	She was followed-up for tectal plate lesion

Contd...

Table 1: Contd...

Authors/year	Age (years)	Presentation	Mode of treatment	Time of treatment*	Delivery method	Complications	Notes
Shah and Chamoun (2014)	20	Headache, nausea, vomiting, gait imbalance, left facial weakness, left ear hearing loss	VP	26	C/S	Worsening respiratory status, dysphagia (due to mass lesion)	She was operated for vestibular schwannoma after delivery
Presented case	28	Headache, vomiting, vision disturbance	VP	13	C/S (epidural anesthesia)	None	Ampicillin/gentamicin given at time of labor and delivery

*Weeks of gestation; **Detailed information was not given in the source; ***Time of ventricular drainage insertion. SVD – Spontaneous vaginal delivery; C/S – Cesarean section; VP – Ventriculoperitoneal; VA – Ventriculoatrial; VPL – Ventriculopleural; E3V – Endoscopic third ventriculostomy; N/A – Not available

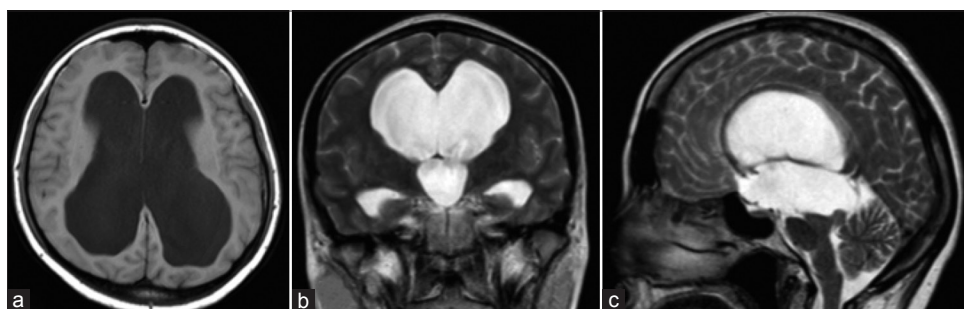


Figure 1: Hydrocephalus secondary to cerebral aqueduct obstruction is seen on T1-weighted axial (a), T2-weighted coronal (b) T2-weighted sagittal brain magnetic resonance images (c)

At the 6th month following her delivery, brain computed tomography (CT) depicted size of ventricles has decreased with a patent VP shunt function [Figure 2].

Discussion

Cerebral (sylvian) aqueduct is the most common intraventricular site for obstructive hydrocephalus.^[15] Cerebral aqueduct stenosis contributes 6–66% of pediatric onset and 5–49% of adult-onset hydrocephalus.^[16,17] Etiology is diverse as infectious (bacterial, viral), genetic X-linked, central nervous system malformations, head traumas, tumors, and hemorrhage.^[15] However, only one out of each four cases has an underlying identifiable cause for stenosis. Remaining cases are named as “idiopathic.” Cerebral aqueduct stenosis is a dynamic event affected with ongoing intracranial changes such as pregnancy in which many physiological changes occur, especially supratentorial cerebrospinal fluid (CSF) excess may disrupt the already tight aqueduct.^[18] Based on this assumption, we should further understand physiological changes that occur throughout pregnancy.

Heart rate, cardiac left ventricular volume, cardiac output, central venous pressure, and total body water increase whereas mean arterial blood pressure, peripheral vascular resistance, and plasma oncotic pressure decrease in

addition to hemodilution (approximately 10%).^[13,19,20] In the brain, resistance to vasoconstrictor metabolites increases, blood brain barrier stability increases with increment in number of efflux transporter proteins, autoregulatory range of cerebral perfusion pressure increases (in animal models), cerebral blood flow (CBF) velocity decreases; hence, CBF increases (approximately 20%), selective remodeling of parenchymal arterioles (thinning of vessel wall with larger vessel lumen) happens, capillary density increases in the posterior circulation.^[21–27] CSF volume also increases throughout pregnancy with venous dilatation.^[4,13,28] All these changes may lead to increased ICP hence facilitate obstructive hydrocephalus by further narrowing the cerebral aqueduct, which is already tight just before the pregnancy.^[6,18] Furthermore, some radiological changes are in progress during pregnancy. While the brain decreases in volume (4.1–6.6%), ventricular size increases (17.3–29.5%) until term. From delivery to 24th week postpartum, normalization in brain volume and ventricular size continues.^[29]

In 14 pregnant patients with new onset hydrocephalus presented in the literature, nine patients had mass lesions and secondary hydrocephalus. Mean and median ages of the patients were 26.76 and 25 years, respectively (range = 20–39 years). Presenting symptoms

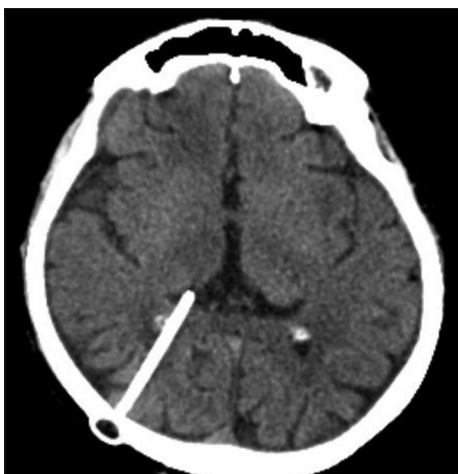


Figure 2: Postoperative brain computed tomography shows resolution of hydrocephalus following ventriculoperitoneal shunt insertion

were headache (most common), nausea and/or vomiting, depressed sensorium, seizure, memory disturbance, and vision problem.^[3-14] Clinical presentation can be easily confused with preeclampsia.^[6] In cases with concomitant brain tumor, tumor-related signs and symptoms were also observed.^[7,9,10,14] Hence, imaging test in suspected cases should be conducted. In emergency circumstances, brain CT imaging is the best modality of choice. However, pregnancy is a contradiction for ionizing radiation; hence, MR imaging and neurological examination become vital tools of evaluation. Diagnoses of the mass lesions in nine patients were glioma, hemangioblastoma, meningioma, vestibular schwannoma, and neurocysticercosis infection. Shunt systems (8 VP, 1 ventriculoatrial, 1 ventriculopleural), endoscopic third ventriculostomy (three patients), and transient ventriculostomy (one patient) were preferred management tools for hydrocephalus in these patients. The patient with ventriculostomy had a revision surgery to turn to VP shunt after delivery. Mean and median times of intervention for hydrocephalus were 20.8 and 25 weeks of gestation, respectively (range = 7–35 weeks). All newborns were healthy at the time of delivery in cases where deliveries were conducted.^[3-14]

After treatment of hydrocephalus, the next question will be which way of delivery is the best option for the patient. If the patient is in well status without any symptoms, spontaneous vaginal delivery will be a good option. In spontaneous vaginal delivery, the second stage of labor, which needs intense straining resulting in increased ICP should be kept at minimum. In unstable patients and in cases with obstetric indications, C/S under general anesthesia should be conveyed with motorization of patients' fluid status, central venous pressure. In severe cases, diuretics and steroid can be used. In circumstances with controlled ICP, epidural anesthesia can be conveyed during C/S.^[3,6,30,31]

Although there is no comprehensive data recommending absolute use of peripartum antibiotics in patients with CSF

shunts, some rare cases of shunt infection after vaginal delivery or C/S were reported.^[32,33] There are contrary papers debating on prophylactic antibiotic use both in vaginal delivery and C/S for patients with CSF shunts.^[3,6,34] During C/S, the abdominal tip of VP shunt can be contaminated directly or indirectly due to bacteremia, especially if there is a known colonization of the mother.^[31,32] In the case of antibiotic prophylaxis, ampicillin (2 g I.V. for every 6 h) and gentamicin (1.5 mg/kg I.V. every 8 h) are the main treatment regimens with an ongoing 48 h of postpartum therapy.^[6]

Postpartum shunt dysfunction and shunt infection risks were reported to be present until 6 months to 1 year.^[6,33] Hence, continuous clinical follow-ups even after the delivery are necessary to prevent such complications in a timely manner.

Conclusion

Obstructive hydrocephalus is a very rare complication during pregnancy. Hydrocephalus becomes obvious and necessitates treatment before the third trimester of pregnancy. Timely diagnosis, especially differentiation from preeclampsia, is a life-saving step. If no complication happens during intervention for hydrocephalus, spontaneous vaginal delivery is a safe way of delivery for both mother's and newborn's well-being. C/S should be saved for obstetrical indications and can be conducted under epidural anesthesia if ICP is kept under control. Interdisciplinary approach of neurosurgeons and anesthesiologists is pivotal for delicate care of the patient and the baby.

Acknowledgements

Murat Şakir Ekşi, M.D. was supported by a grant from Tubitak (The Scientific and Technological Research Council of Turkey), Grant number: 1059B191400255.

Financial support and sponsorship

Nil.

Conflicts of interest

There are no conflicts of interest.

References

1. Stagno V, Navarrete EA, Mirone G, Esposito F. Management of hydrocephalus around the world. *World Neurosurg* 2013;79 (2 Suppl):S23.e17-20.
2. Oi S. Classification and definition of hydrocephalus-origin, controversy and assignment of the terminology. In: Cinalli G, Sainte-Rose C, Maixner W, editors. *Pediatric Hydrocephalus*. Italia: Springer-Verlag; 2005. p. 95-112.
3. Monfared AH, Koh KS, Apuzzo ML, Collea JV. Obstetric management of pregnant women with extracranial shunts. *Can Med Assoc J* 1979;120:562-3.
4. Howard TE Jr, Herrick CN. Pregnancy in patients with ventriculoperitoneal shunts: Report of two cases. *Am J Obstet Gynecol* 1981;141:99-101.
5. Nugent P, Hoshek S. Large extra-abdominal cyst as a postpartum

- complication of peritoneal shunt. Case report. *J Neurosurg* 1986;64:151-2.
6. Wisoff JH, Kratzert KJ, Handwerker SM, Young BK, Epstein F. Pregnancy in patients with cerebrospinal fluid shunts: Report of a series and review of the literature. *Neurosurgery* 1991;29:827-31.
 7. Naidoo K, Bhigjee AI. Multiple cerebellar haemangioblastomas symptomatic during pregnancy. *Br J Neurosurg* 1998;12:281-4.
 8. Suarez VR, Iannucci TA. Neurocysticercosis in pregnancy: A case initially diagnosed as eclampsia. *Obstet Gynecol* 1999;93 (5 Pt 2):816-8.
 9. Beni-Adani L, Pomeranz S, Flores I, Shoshan Y, Ginosar Y, Ben-Shachar I. Huge acoustic neurinomas presenting in the late stage of pregnancy. Treatment options and review of literature. *Acta Obstet Gynecol Scand* 2001;80:179-84.
 10. Bharti N, Kashyap L, Mohan VK. Anesthetic management of a parturient with cerebellopontine-angle meningioma. *Int J Obstet Anesth* 2002;11:219-21.
 11. Chopra I, Gnanalingham K, Pal D, Peterson D. A knot in the catheter – An unusual cause of ventriculo-peritoneal shunt blockage. *Acta Neurochir (Wien)* 2004;146:1055-6.
 12. Watanabe Y, Oki S, Sumida M, Isobe N, Kanou Y, Takeda M. A case of aqueductal stenosis with acute progressive hydrocephalus during pregnancy. *No Shinkei Geka* 2005;33:59-63.
 13. Riffaud L, Ferre JC, Carsin-Nicol B, Morandi X. Endoscopic third ventriculostomy for the treatment of obstructive hydrocephalus during pregnancy. *Obstet Gynecol* 2006;108 (3 Pt 2):801-4.
 14. Shah KJ, Chamoun RB. Large vestibular schwannomas presenting during pregnancy: Management strategies. *J Neurol Surg B Skull Base* 2014;75:214-20.
 15. Spennato P, Tazi S, Bekaert O, Cinalli G, Decq P. Endoscopic third ventriculostomy for idiopathic aqueductal stenosis. *World Neurosurg* 2013;79 (2 Suppl): S21.e13-20.
 16. Hirsch JF, Hirsch E, Sainte Rose C, Renier D, Pierre-Khan A. Stenosis of the aqueduct of Sylvius. Etiology and treatment. *J Neurosurg Sci* 1986;30:29-39.
 17. Jellinger G. Anatomopathology of non-tumoral aqueductal stenosis. *J Neurosurg Sci* 1986;30:1-16.
 18. Kulkarni AV, Hui S, Shams I, Donnelly R. Quality of life in obstructive hydrocephalus: Endoscopic third ventriculostomy compared to cerebrospinal fluid shunt. *Childs Nerv Syst* 2010;26:75-9.
 19. Clapp JF 3rd, Capeless E. Cardiovascular function before, during, and after the first and subsequent pregnancies. *Am J Cardiol* 1997;80:1469-73.
 20. Gordon MC. Maternal physiology. In: Gabbe SG, Niebyl JR, Simpson JL, editors. *Obstetrics: Normal and Problem Pregnancies*. 5th ed. London: Churchill Livingstone; 2007.
 21. Johnson AC, Cipolla MJ. The cerebral circulation during pregnancy: Adapting to preserve normalcy. *Physiology (Bethesda)* 2015;30:139-47.
 22. Belfort MA, Tooke-Miller C, Allen JC Jr, Saade GR, Dildy GA, Grunewald C, et al. Changes in flow velocity, resistance indices, and cerebral perfusion pressure in the maternal middle cerebral artery distribution during normal pregnancy. *Acta Obstet Gynecol Scand* 2001;80:104-12.
 23. Chan SL, Cipolla MJ. Relaxin causes selective outward remodeling of brain parenchymal arterioles via activation of peroxisome proliferator-activated receptor- γ . *FASEB J* 2011;25:3229-39.
 24. Cipolla MJ, Sweet JG, Chan SL. Cerebral vascular adaptation to pregnancy and its role in the neurological complications of eclampsia. *J Appl Physiol* (1985) 2011;110:329-39.
 25. Nevo O, Soustiel JF, Thaler I. Maternal cerebral blood flow during normal pregnancy: A cross-sectional study. *Am J Obstet Gynecol* 2010;203:475.e1-6.
 26. Serra-Serra V, Kyle PM, Chandran R, Redman CW. Maternal middle cerebral artery velocimetry in normal pregnancy and postpartum. *Br J Obstet Gynaecol* 1997;104:904-9.
 27. Williams K, Wilson S. Maternal middle cerebral artery blood flow velocity variation with gestational age. *Obstet Gynecol* 1994;84:445-8.
 28. Hopkins EL, Hendricks CH, Cibils LA. Cerebrospinal fluid pressure in labor. *Am J Obstet Gynecol* 1965;93:907-16.
 29. Oatridge A, Holdcroft A, Saeed N, Hajnal JV, Puri BK, Fusi L, et al. Change in brain size during and after pregnancy: Study in healthy women and women with preeclampsia. *AJNR Am J Neuroradiol* 2002;23:19-26.
 30. Hirs I, Grbcic P. Cesarean section in spinal anesthesia on a patient with mesencephalic tumor and ventriculoperitoneal drainage – A case report. *Korean J Anesthesiol* 2012;63:263-5.
 31. Olatunbosun OA, Akande EO, Adeoye CO. Ventriculoperitoneal shunt and pregnancy. *Int J Gynaecol Obstet* 1992;37:271-4.
 32. Kane JM, Jackson K, Conway JH. Maternal postpartum group B beta-hemolytic *Streptococcus* ventriculoperitoneal shunt infection. *Arch Gynecol Obstet* 2004;269:139-41.
 33. Fox BC. Delayed-onset postpartum meningitis due to group B *Streptococcus*. *Clin Infect Dis* 1994;19:350.
 34. Landwehr JB Jr, Isada NB, Pryde PG, Johnson MP, Evans MI, Canady AI. Maternal neurosurgical shunts and pregnancy outcome. *Obstet Gynecol* 1994;83:134-7.