

## Axillary Nerve Schwannoma: A Rare Case Report

### Abstract

Primary tumors of the brachial plexus are a rare cause of an axillary swelling. Schwannomas are benign tumors arising from Schwann cells. Most of the schwannomas occur in the head and neck region and in the flexor aspect of the limbs. We present a case of a 60-year-old female who presented with pain in the left axilla radiating to the left upper limb since 2 years and a painful swelling in her left axilla for 3 months. The diagnosis is made by fine needle aspiration cytology and magnetic resonance imaging, and confirmed by histopathological examination as schwannoma.

**Keywords:** Axillary swelling, brachial plexus, schwannoma

### Introduction

Schwannomas are benign encapsulated perineural tumors arising from Schwann cells of nerve sheath of peripheral or cranial nerves. About 25% of all schwannomas occur in the head and neck region. They rarely occur in the axillary nerve or brachial plexus. We report here one such case of an axillary schwannoma, which is rare and unusual in its site of occurrence.

### Case Report

A 60-year-old female patient presented to Victoria Hospital with pain in the left axilla since 2 years, insidious in onset, radiating to left upper limb and associated with tingling sensation up to the tip of all fingers. She noticed a painful swelling in her left axilla 3 months back. On examination, a solitary, tender, firm swelling of 4 cm × 3 cm in its greatest dimension was situated in the left axilla. Lymph nodes were not palpable. There were no neurological deficits detected on the left upper limb.

All hematological investigations were within normal limits. Fine-needle aspiration cytology showed several fragments of closely packed, oval to spindle cells with focal, minimal atypia and few fragments of fibrous tissue, suggestive of a benign cellular spindle lesion. Ultrasound of left axilla showed well-defined hypochoic lesion measuring 2.5 cm × 2.5 cm with internal vascularity, giving the differential diagnosis of lymph node, or soft tissue

This is an open access article distributed under the terms of the Creative Commons Attribution-NonCommercial-ShareAlike 3.0 License, which allows others to remix, tweak, and build upon the work non-commercially, as long as the author is credited and the new creations are licensed under the identical terms.

For reprints contact: reprints@medknow.com

tumor (nerve sheath tumor). Magnetic resonance imaging (MRI) showed a well-defined solid, homogeneously enhancing, T1 hypo and T2/proton density fat saturation hyperintense lesion continuous with the axillary nerve sheath in left axillary fat with no locoregional lymphadenopathy [Figure 1a-d].

The patient underwent excision of the tumor that was found to be arising from the axillary nerve sheath [Figure 2a-d]. The patient did not have any neurological deficit after the procedure, except for the pain in the axilla. Post-operatively and after discharge, the patient was advised physiotherapy. The patient came for follow-up after 1 month without any neurological deficit. Histopathological examination (HPE) showed encapsulated lesion consisting of proliferating fibroblasts with scanty collagen and organoid arrangement of cells at places, without cellular atypia, suggestive of schwannoma.

### Discussion

Schwannoma (neurilemmoma) is a benign tumor, arising from Schwann cells.<sup>[1]</sup> They usually have a peak incidence in the third to fifth decades of life, affecting both sexes equally. Schwannoma is a slow growing, solitary, firm, well-circumscribed, and encapsulated round or ovoid tumor<sup>[2]</sup> ranging from 1.5 to 3 cm in diameter.<sup>[3,4]</sup> The presence of large tumors, as well as rare cases of multiple neoplasms, has been reported.<sup>[5-7]</sup> An extracranial schwannoma may present as a solitary swelling anywhere in the body, the most common

**How to cite this article:** Kumar PA, Islary B, Ramachandra R, Naik T. Axillary nerve schwannoma: A rare case report. *Asian J Neurosurg* 2017;12:787-9.

**Prem A. Kumar,  
Biju Islary,  
Ramya  
Ramachandra,  
Thippeswamy Naik**

*Department of General Surgery,  
Bangalore Medical College and  
Research Institute, Bengaluru,  
Karnataka, India*

### Address for correspondence:

*Dr. Biju Islary,  
Department of General Surgery,  
Bangalore Medical College and  
Research Institute, Fort,  
KR Road, Bengaluru - 560 002,  
Karnataka, India.  
E-mail: islarybiju@yahoo.com*

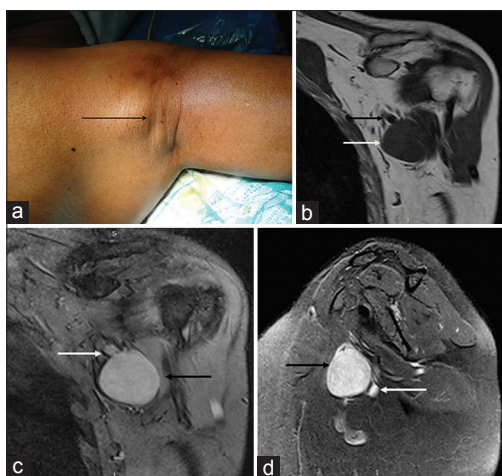
### Access this article online

Website: [www.asianjns.org](http://www.asianjns.org)

DOI: 10.4103/1793-5482.181147

### Quick Response Code:





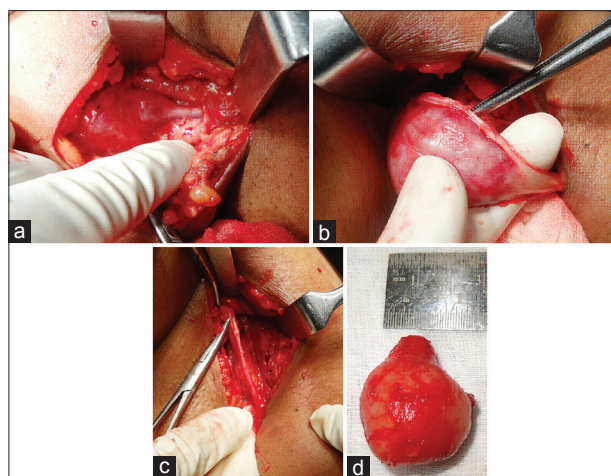
**Figure 1:** (a) Axillary swelling, preoperative. (b-d) Magnetic resonance image showing well-defined solid, homogeneously enhancing, T1 hypo and T2/proton density fat saturation hyperintense lesion continuous with the axillary nerve sheath (white arrow = axillary nerve, black arrow = lesion)

sites being the head and neck, flexor surfaces of the upper and lower limbs, posterior mediastinum in the thorax and on the trunk.<sup>[8]</sup> However, a schwannoma in the axilla is of unusual occurrence, such that a schwannoma presenting as a brachial plexus tumor accounts to only about 5% of Schwannomas.<sup>[9]</sup> Thus, on account of their rare occurrence and involvement of unusual sites, they pose a significant challenge to diagnosis and treatment.

MRI is an important and preferred diagnostic tool. On imaging scans, schwannoma is visualized as a well-defined homogeneously enhancing lesion, usually fusiform in shape, isointense to surrounding muscles on T1-weighted images, and hyperintense on T2-weighted images and enhanced with gadolinium.<sup>[10]</sup> Biopsy for HPE is also an important tool for diagnosis. On HPE, schwannomas are found to contain a varying proportion of two different areas. Antoni type A areas are highly cellular and contain closely packed spindle-shaped cells forming palisades called Verocay bodies. Antoni type B areas are composed of loosely arranged spindle-shaped cells in a mucinous matrix.<sup>[11]</sup>

The first choice of treatment for schwannoma is surgical excision of the tumor, while sparing the nerve trunk to avoid neurological deficits. Extracapsular excision is a commonly used operative technique in this regard. The intracapsular technique was used by Date *et al.*<sup>[12]</sup> Reports comparing results obtained after extracapsular and intracapsular enucleation of schwannoma have found the latter to be a better technique due to lower risk of complications.<sup>[12]</sup>

However, determining the margins of tumor excision is always difficult and controversial. The involved nerve may have to be sometimes sacrificed to achieve complete resection of the tumor. A significant risk of neurological complications is associated with any intraoperative damage



**Figure 2:** (a) Intraoperative photo showing the tumor continuous with axillary nerve. (b) Intraoperative photo showing axillary nerve dissected from the tumor. (c) Intraoperative photo showing the axillary nerve after excision of the tumor. (d) Gross tumor specimen after removal

to nerve fascicles. In recent reports, intraoperative nerve action potential recording has been shown to avoid nerve damage during the procedure.<sup>[13]</sup>

## Conclusion

We have presented a rare case of axillary schwannoma. They pose a significant challenge to diagnosis on account of their rare occurrence in unusual sites. Hence, a clinician has to bear in mind the possibility of a schwannoma in patients presenting with a swelling in the axilla. MRI has a valuable diagnostic importance, and surgical excision of these tumors is associated with a good prognosis.

## Financial support and sponsorship

Nil.

## Conflicts of interest

There are no conflicts of interest.

## References

- Zhou J, Man XY, Zheng M, Cai SQ. Multiple plexiform schwannoma of a finger. *Eur J Dermatol* 2012;22:149-50.
- Ackerman LV, Taylor FH. Neurogenous tumors within the thorax; a clinicopathological evaluation of forty-eight cases. *Cancer* 1951;4:669-91.
- Kehoe NJ, Reid RP, Semple JC. Solitary benign peripheral-nerve tumours. Review of 32 years' experience. *J Bone Joint Surg Br* 1995;77:497-500.
- Malizos K, Ioannou M, Kontogeorgakos V. Ancient schwannoma involving the median nerve: A case report and review of the literature. *Strategies Trauma Limb Reconstr* 2013;8:63-6.
- Kang HJ, Shin SJ, Kang ES. Schwannomas of the upper extremity. *J Hand Surg Br* 2000;25:604-7.
- Ozdemir O, Ozsoy MH, Kurt C, Coskunol E, Calli I. Schwannomas of the hand and wrist: Long-term results and review of the literature. *J Orthop Surg (Hong Kong)* 2005;13:267-72.
- Strickland JW, Steichen JB. Nerve tumors of the hand and

- forearm. *J Hand Surg Am* 1977;2:285-91.
8. Ku HC, Yeh CW. Cervical schwannoma: A case report and eight years review. *J Laryngol Otol* 2000;114:414-7.
  9. Huang JH, Samadani U, Zager EL. Brachial plexus region tumors: A review of their history, classification, surgical management, and outcomes. *Neurosurg Q* 2003;13:151-61.
  10. Ergun T, Lakadamyali H, Derincek A, Tarhan NC, Ozturk A. Magnetic resonance imaging in the visualization of benign tumors and tumor-like lesions of hand and wrist. *Curr Probl Diagn Radiol* 2010;39:1-16.
  11. Traistaru R, Enachescu V, Manuc D, Gruia C, Ghilusi M. Multiple right schwannoma. *Rom J Morphol Embryol* 2008;49:235-9.
  12. Date R, Muramatsu K, Ihara K, Taguchi T. Advantages of intra-capsular micro-enucleation of schwannoma arising from extremities. *Acta Neurochir (Wien)* 2012;154:173-8.
  13. Kwok K, Davis B, Kliot M. Resection of a benign brachial plexus nerve sheath tumor using intraoperative electrophysiological monitoring. *Neurosurgery* 2007;60 4 Suppl 2:316-20.