

A Rare Primary Dumbbell Lipoblastoma

Abstract

Lipomas and lipoblastomas are benign tumors of mesenchymal origin in contrast to liposarcoma that is a malignant tumor. Atypical lipomatous lesion arising from embryonal fat cells is termed as lipoblastoma. In the present case report 9-month-old male presented to us with painless, rapidly progressing mass over back, power was normal in all four limbs, fine needle aspiration cytology was suggestive of cellular tissue, magnetic resonance imaging suggestive of well-defined enhancing mass in paravertebral location, extending from D3 to D10 vertebrae with intraspinal extension, communicating through neural foramina at level of D7. Intraoperatively, it was dumbbell-shaped, looked like neurofibroma based on the gross findings and it was adherent to dorsal nerve root also. Single level laminectomy with complete surgical excision of lesion done with sacrifice of dorsal nerve root. Histopathology was suggestive of lipoblastoma. Postoperative recovery was uneventful.

Keywords: Dorsal spine, dumbbell, lipoblastoma

Introduction

Tumors arising from adipocytes comprise around 6% of all soft tissue tumors. Of these, around 94% are lipomas, 4.7% are lipoblastomas, and 1.7% are liposarcomas.^[1] Lipoblastomas are subdivided into two types: Lipoblastoma, which is well-encapsulated, well-circumscribed lesion, and lipoblastomatosis, that is, nonencapsulated, multicentric infiltrative tumor. It is a tumor of pediatric age group with a higher incidence in males. Lipoblastomas most commonly occur in extremities followed by trunk, abdomen, and head and neck.^[2] Jung *et al.* found a higher incidence in head and neck.^[3] Spine and spinal cord involvement in lipoblastoma in most of the cases is secondary, and that may be from neck lesion, mediastinal lesion or from the pelvis and may result in a neurological deficit. Though there are various reports of lipoblastoma with spinal extension, we have not found any case of primary spinal lipoblastoma.

Case Report

A 9-month-old male presented to us with painless, rapidly progressing mass over back since 6 months, which was nonpulsatile, nontranslucent with overlying healthy skin. On examination, there was no motor deficit. Fine needle aspiration

cytology was inconclusive. Magnetic resonance imaging (MRI) study of spine revealed large well-defined enhancing mass in left paraspinal region with intraspinal extension at D7 level, extending from D3 to D10 vertebrae with compression of thecal sac. The patient underwent single level D7 laminectomy. Extradural intraspinal extension, communicating through neural foramina at the level of D7 was noticed. It was well-defined, fleshy yellowish mass, avascular was firm to hard in consistency and was removed completely with microsurgical techniques. Histopathology report was suggestive of lipoblastoma. Postoperative recovery was uneventful. The patient had no added postoperative deficit [Figures 1-5].

Discussion

Term lipoblastoma was proposed by Jaffe in 1926.^[4] It is a tumor of pediatric age group with 55% of cases diagnosed before 1-year of age and almost all reported cases diagnosed in the first decade of life.^[5] Occurrence of lipoblastoma in adults is rare. Male:female incidence is 3.8:1.^[6] Lipoblastomas most commonly occur in extremities (60%), followed by trunk (15%), abdomen (14%), and head and neck (14%).^[2] Lipoblastomas show rearrangement in chromosome 8q11-13.^[7] Rapid growth of lipoblastoma can give rise to compressive symptoms. On radiological

**Gulzar Gupta,
Rajveer Garg,
Chetan Wadhwa,
Hanish Bansal,
Rakesh Kumar
Kaushal**

*Department of Neurosurgery,
DMCH, Ludhiana, Punjab,
India*

Address for correspondence:

*Dr. Rajveer Garg,
77-D, Kitchlu Nagar, Ludhiana,
Punjab, India.
E-mail: dr.rg2482@gmail.com*

Access this article online

Website: www.asianjns.org

DOI: 10.4103/1793-5482.185054

Quick Response Code:



How to cite this article: Gupta G, Garg R, Wadhwa C, Bansal H, Kaushal RK. A rare primary dumbbell lipoblastoma. *Asian J Neurosurg* 2018;13:83-5.

This is an open access article distributed under the terms of the Creative Commons Attribution-NonCommercial-ShareAlike 3.0 License, which allows others to remix, tweak, and build upon the work non-commercially, as long as the author is credited and the new creations are licensed under the identical terms.

For reprints contact: reprints@medknow.com

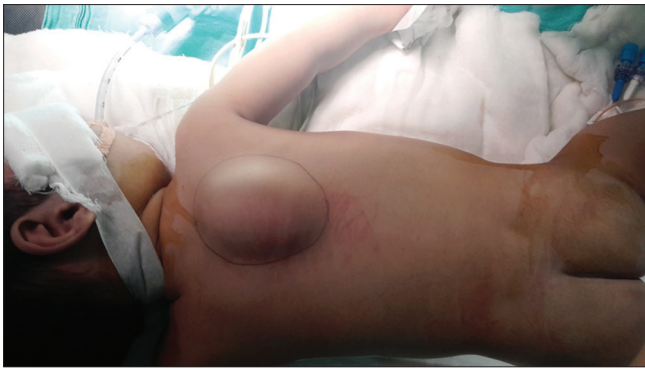

Figure 1: Preoperative photo

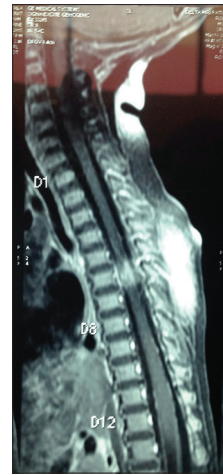


Figure 2: Magnetic resonance imaging dorsal spine T1-weighted imaging contrast sagittal view

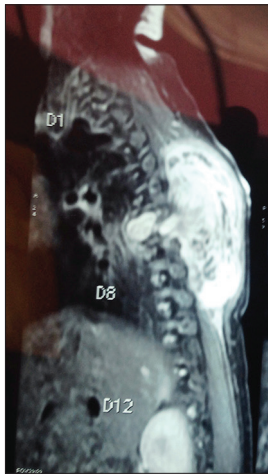


Figure 3: Sagittal view

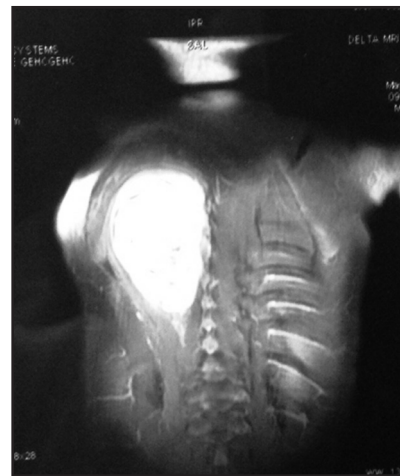

Figure 4: Coronal view

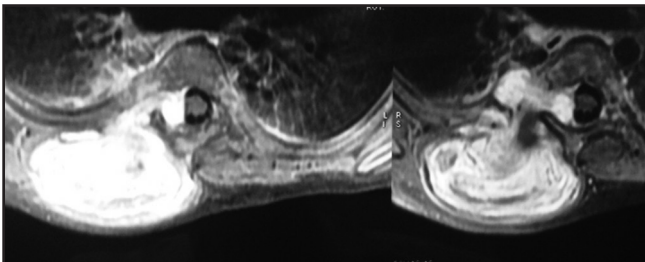


Figure 5: Magnetic resonance imaging dorsal spine axial view

examination, lipoblastoma appears as nonspecific soft-tissue mass without bone erosion.^[7] MRI is an investigation of choice that classically shows high signal intensity on T1-weighted imaging and T2-weighted imaging identical to fat.^[1] However, increased cellularity secondary to the myxoid and mesenchymal component may lead to lower T1-weighted signals.^[8] Grossly size of lipoblastoma varies significantly. It is pale yellow lobulated lesion which is soft in consistency with moderate vascularity. Differential diagnosis includes lipoma, hibernoma, and liposarcoma.^[9] Lipoma is the closest differential of lipoblastoma and can be differentiated by the presence of abundant vacuolation in the cytoplasm.^[10] In lipoblastoma, there is varying degree of cellular differentiation. Hibernoma is completely formed

of brown fat with a central nucleus.^[9] There is abundant finely granular cytoplasm. Apart from cellular atypia and hyperchromasia, liposarcoma can be differentiated by the prominence of plexiform capillaries.^[9] There is the absence of lobulation in liposarcoma.

Complete surgical excision is the treatment of choice in lipoblastoma. Incomplete resection is significantly associated with recurrence. Lipoblastoma arising from back and neck have a significant risk of recurrence.

In our case, there was primary involvement of the spine with spread to the paraspinal region communicating through neural foramina giving rise to a dumbbell configuration. The erosion of pars interarticularis secondary to mass effect and spread to para spinal region is seen uncommonly in lipoblastoma. T1-weighted MRI showed decreased signal intensity which is unusual for tumor arising from adipocytes. This decreased signal intensity can be explained by occasionally increased cellularity, that is, myxoid and mesenchymal components of lipoblastoma.

Lipoblastoma is a rare benign tumor of adipocytes. Preoperative diagnosis may be difficult due to varying picture on imaging. Though benign lesion, it can cause dysfunction of the organ by its mass effect. It can erode the bone and can spread to adjacent planes. Complete excision of the tumor not only clinches the diagnosis but also prevent recurrence.

Financial support and sponsorship

Nil.

Conflicts of interest

There are no conflicts of interest.

References

1. Gardikis S, Kambouri K, Tsalkidis A, Chatzimicael A, Vaos G. Lipoblastoma on the posterior side of the neck. *Turk J Pediatr* 2009;51:287-9.
2. Arda IS, Senocak ME, Gögüs S, Büyükpamukçu N. A case of benign intrascrotal lipoblastoma clinically mimicking testicular torsion and review of the literature. *J Pediatr Surg* 1993;28:259-61.
3. Jung SM, Chang PY, Luo CC, Huang CS, Lai JY, Hsueh C. Lipoblastoma/lipoblastomatosis: A clinicopathologic study of 16 cases in Taiwan. *Pediatr Surg Int* 2005;21:809-12.
4. Jaffe RH. Recurrent lipomatous tumors of the groin: Liposarcoma and lipomapseudomyxomatodes. *Arch Pathol* 1926;1:381-7.
5. Coffin CM. Adipose and myxoid tumors. In: Coffin CM, Dehner LP, O'Shea PA, editors. *Pediatric Soft Tissue Tumors: A Clinical, Pathological, and Therapeutic Approach*. New Salt Lake City, Utah: JA Majors Company; 1997. p. 254-76.
6. Collins MH, Chatten J. Lipoblastoma/lipoblastomatosis: A clinicopathologic study of 25 tumors. *Am J Surg Pathol* 1997;21:1131-7.
7. Rasalkar DD, Chu WC. Lipoblastomatous tumours, a rare entity: Report of two cases in children Hong Kong *J Radiol* 2010;13:209-12.
8. Wang SF, Chang CY, Wu HD. Lipoblastomatosis of the shoulder: Unusual MR appearance. *Br J Radiol* 1998;71:884-5.
9. Brodsky JR, Kim DY, Jiang Z. Cervical lipoblastoma: Case report, review of literature, and genetic analysis. *Head Neck* 2007;29:1055-60.
10. López-Ferrer P, Jiménez-Heffernan JA, Yébenes L, Vicandi B, Viguer JM. Fine-needle aspiration cytology of lipoblastoma: A report of two cases. *Diagn Cytopathol* 2005;32:32-4.