

## Use of Detachable Coils Without the Need of a Double Marker Microcatheter: Technical Note

### Abstract

When using detachable coils for cerebral aneurysm embolization, it is necessary to place a microcatheter with radiopaque markers at 2 sites (tip and 3 cm proximal from the tip) in most cases. Detachable coils that can be positioned independently from the proximal marker may facilitate new applications utilizing their characteristics. Herein, we report 2 cases that were treated with new applications. Detachable coils that function to electrically detect the moment they come out of the microcatheter were used. In one patient with a large aneurysm with an irregular shape, coil embolization was applied by advancing the catheter more than 3 cm from the aneurysm neck to the caudally protruded compartment near the proximal end of the neck, which was difficult to reach with the coil. In the other patient with cerebral arteriovenous malformation (AVM), microcatheters for AVM without a proximal marker were used for coil embolization before Onyx injection: Coil embolization was applied through one microcatheter to a site more proximal than the tip of the other microcatheter, followed by Onyx injection through the distal catheter, by which the nidus was continuously penetrated from the initiation of injection, obtaining an effect similar to that of the plug and push technique. Through the use of detachable coils, which are not dependent on the visibility of the proximal marker, the limitation of catheter positioning is reduced and the applicable types of catheter increase, which may facilitate to enable its use for new clinical indications.

**Keywords:** *Aneurysm, arteriovenous malformation, detachable coil*

### Introduction

To apply the detachable coils that are currently available, it is necessary to use a microcatheter with double markers to identify the positional relationship between the microcatheter tip and coil.<sup>[1]</sup> The double markers are radiopaque markers that are attached to the tip (distal marker) and 3 cm from the tip (proximal marker). Since a radiopaque marker is located 3 cm from the tip of the detachable coil delivery wire, when the coil region and detachment zone of the detachable coil come completely out of the microcatheter, it overlaps with the proximal marker of the microcatheter. Since the microcatheter tip is hidden in the coil mass within the actual intra-aneurysmal embolization, it becomes invisible and whether or not the entire coil region came out of the catheter, i.e., whether it is present at the detachable position, is confirmed based on the positional relationship between the proximal marker and the marker on the delivery wire.<sup>[1]</sup> Accordingly, detachable coils can only be applied with

a microcatheter and a proximal marker, and when the proximal marker is invisible for some reason, their application becomes difficult. In general, these conditions occur when coils are placed into an aneurysm through a significantly tortuous parent artery or many coils are placed within a large aneurysm. The coil mass and parent artery overlap in two-dimensional fluoroscopic images, and the proximal marker in the parent artery becomes invisible. The direction of the fluoroscope is generally changed to avoid overlapping, but it may not be easy in some cases.

The proximal marker is not always visible, as described above. If the positional relationship of the detachable coils can be identified without visually confirming the proximal marker, detachable coils are useful for the conditions described above. In addition to this general advantage, by actively applying this property, a microcatheter can be inserted deeply, burying its proximal marker region within the aneurysm, or coils can be used with a microcatheter without a proximal marker.

This is an open access article distributed under the terms of the Creative Commons Attribution-NonCommercial-ShareAlike 3.0 License, which allows others to remix, tweak, and build upon the work non-commercially, as long as the author is credited and the new creations are licensed under the identical terms.

For reprints contact: reprints@medknow.com

**How to cite this article:** Sadato A, Hayakawa M, Adachi K, Kato Y, Hirose Y. Use of detachable coils without the need of a double marker microcatheter: Technical note. *Asian J Neurosurg* 2018;13:119-22.

**Akiyo Sadato,  
Motoharu  
Hayakawa,  
Kazuhide Adachi,  
Yoko Kato,  
Yuichi Hirose**

*Department of Neurosurgery,  
Fujita Health University,  
Toyoake City, Aichi 470-1192,  
Japan*

### Address for correspondence:

*Dr. Akiyo Sadato,  
Department of Neurosurgery,  
Fujita Health University, 1-98  
Dengakugakubo, Kutsukake-cho,  
Toyoake City, Aichi 470-1192,  
Japan.  
E-mail: asadato@fujita-hu.ac.jp*

### Access this article online

Website: [www.asianjns.org](http://www.asianjns.org)

DOI: 10.4103/1793-5482.185058

### Quick Response Code:



We applied these advantages to the treatment of a large irregular shaped aneurysm and a case of arteriovenous malformation (AVM).

## Device

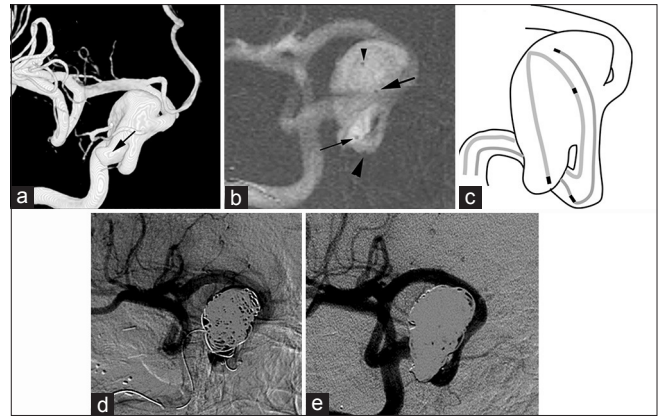
ED coils (Kaneka Medix, Osaka, Japan) are instantaneous electrically detachable coils made of platinum, which were previously reported as immediately electrically detachable coils, and they have been commercialized and used clinically in Japan to treat cerebral aneurysms.<sup>[2-5]</sup> Coils are detached by melting polyvinyl alcohol (PVA) connecting the coil and delivery wire with a 1.2 W monopole high-frequency current.<sup>[2]</sup> The generator box applying a high-frequency current can detect changes in the electrical resistance of a circuit formed by connecting electrodes to the proximal end (handling region) of the delivery wire and the return electrode or a needle inserted into the patient's skin. When the coil and PVA of the detachment zone are pushed out of the microcatheter, the electrode at the distal end of the delivery wire is exposed outside the catheter and directly contacts blood, which rapidly decreases the resistance of the circuit. This decrease is detected and informed to the operator through changes in an alarm sound and an indicator lamp on the generator box. In response to this, the operator ceases advancement of the coil and pushes an energization button on the generator box to detach the coil. This coil is also equipped to confirm the position through visibility of the second marker, similar to other detachable coils, and the positional relationship between the coil and catheter can be identified using these two methods. The primary diameters of the coils are 0.010 (ED10) and 0.014 inches (ED14). ED10 can also be applied with a Marathon (ev3. Endovascular, Plymouth, MN, USA) and Magic 18 (Balt, Montmorency, France) used for AVM. The coil and delivery wire are soft, and friction caused by coil insertion into the catheter results in only a small amount of stress, which is another characteristic of this approach.

In one of the new techniques, a microcatheter is advanced more than 3 cm into the aneurysm and the region close to the proximal neck is also tightly packed. The other is applied for embolization of AVM, in which coils are placed as a proximal plug before injection of Onyx (ev3. Endovascular, Plymouth, MN, USA) to promote Onyx penetration into the nidus.

## Case Reports

### Case 1

A patient with a non-ruptured right internal carotid aneurysm with a maximum diameter of 22 mm and a depth (height) of 10 mm. The aneurysm had an irregular shape extending toward the caudal side [Figure 1a]. To ensure placement of the coils in the caudal extended region, it was necessary to deeply insert a microcatheter. Through the transfemoral approach, a 5-Fr guiding sheath was

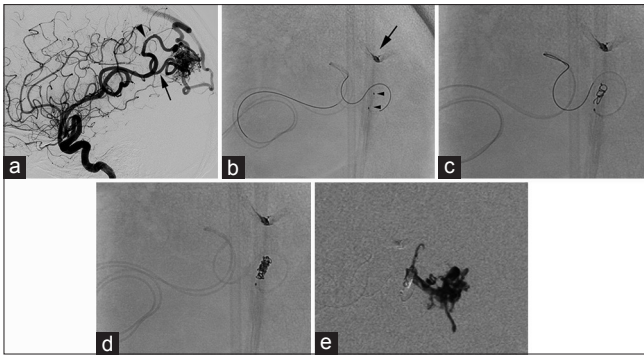


**Figure 1:** (a) Three-dimensional angiogram shows a large aneurysm of right internal carotid artery with caudally extended sac (arrow). (b) Two microcatheters are positioned in the aneurysm. The one (Excelsior 1018) is advanced along inside the aneurysm wall and its tip reaches the caudal sac (small arrow). Its proximal marker is also inside the aneurysm (arrow). The other microcatheter (Excelsior SL10) is positioned in the mid of the aneurysm (small arrow head) and its proximal marker is in the parent internal carotid artery (arrow head). (c) Schematic image of the course and position of microcatheters and their markers in the Figure 1b. (d) Several coils delivered from the Excelsior SL10 are positioned in cranial two-thirds of the sac and are not distributed into the caudal sac. The proximal marker of the Excelsior 1018 is behind the coil mass and invisible anymore. (e) Several ED coils (ED14) are added via the Excelsior 1018 positioned in the caudal sac and complete occlusion is achieved

placed in the right internal carotid artery (ICA). Excelsior 1018 (Striker, Kalamazoo, MI, USA) was advanced along inside the aneurysm wall and its tip was advanced to the protruded region on the caudal side so that the second marker was also present inside the aneurysm, followed by placement of an Enterprise stent (Cordis, Miami, FL, USA) in neck region and transcatheter advancement of the Excelsior SL10 (Striker). The tip of the second catheter was placed near the center of the aneurysm, and the second marker was placed in the ICA (outside the aneurysm) to prepare for the use of various coils other than ED coils [Figure 1b and c]. When the coils (ED14 and Orbit Galaxy; Cordis) were inserted through the catheter placed near the center, the coils could not be distributed to the caudal extended region [Figure 1d]. The proximal marker of the Excelsior 1018 is behind the coil mass and invisible anymore. The caudally extruded region could be filled with ED coils (ED14) placed via the deeply inserted catheter, achieving complete occlusion [Figure 1e]. On follow-up angiography after 1 year, no recanalization was observed.

### Case 2

For an incidentally diagnosed cerebral AVM in the left occipital lobe, embolization, and excision of the nidus were scheduled [Figure 2a]. The main feeder from the middle cerebral artery bifurcated near the nidus to a superior and inferior branches. The superior branch was embolized with Onyx, but the microcatheter was obstructed by solidified Onyx during the plug-forming process, which prevented Onyx permeation into the nidus. Thus, for the remaining feeder, we decided to use balloon catheter or to



**Figure 2:** (a) Left carotid angiogram shows left occipital arteriovenous malformation supplied from feeders arising from left middle cerebral artery. The feeder bifurcates to superior (arrow head) and inferior (arrow) division at close to the nidus. (b) Plain skull X-ray film shows that two Marathon catheters were advanced close to the nidus in the inferior feeder. The tip of the one Marathon is positioned slightly proximal to the other (arrow heads). The arrow indicates previously injected Onyx in the superior feeder that did not successfully penetrate into the nidus. (c) Plain skull X-ray film: Via the proximal Marathon catheter, ED coil (ED10-extrasoft 2.5 mm × 3 cm) is delivered just proximal to the tip of the other distal Marathon catheter. (d) Plain skull X-ray film: The proximal Marathon catheter was advanced into the coil mass and 3 ED coils were added to make a compact and short plug. Tip of the proximal Marathon catheter is hidden in the coil mass. The feeder was packed at the proximal side of the distal Marathon's tip. (e) Onyx 18 is infused from the distal Marathon and infiltrated into the nidus from the beginning

make a plug with coils to facilitate Onyx penetration into the nidus. Endovascular surgery was performed via the transfemoral approach. A 5-Fr guiding sheath was placed in the left internal carotid artery and Scepter XC double lumen balloon (Terumo, Tokyo) catheter was tried to advance into the feeder. However, the balloon catheter did not reach close enough to the nidus due to the tortuosity of the feeder. The balloon catheter was removed, and 2 Marathon catheters were advanced into the feeder close to the nidus [Figure 2b]. An ED-Extrasoft coil (2.5 mm × 3 cm) was placed through the proximal Marathon to cover just proximal to the tip of the Marathon on the distal side [Figure 2c]. The proximal Marathon catheter was advanced into the coil mass, and 3 ED-extrasoft coils (2 mm × 4 cm, 1.5 mm × 2 cm and 1.5 mm × 2 cm) were added to make a compact and short plug. Tip of the proximal Marathon catheter is hidden in the coil mass, but coil positioning for detachment was easily and precisely done independently on the visibility of positional relation of the coil and the microcatheter [Figure 2d]. After confirming obstruction of the feeder, Onyx 18 was injected slowly but continuously through the distal Marathon to embolize the nidus. It was not necessary to prepare a plug on the proximal side by Onyx reflux. Onyx penetrated the nidus from the initiation of injection [Figure 2e], and the compartment perfused by this feeder was filled.

## Discussion

In the use of detachable coils, the proximal marker is generally confirmed visually to identify the positional relationship between the microcatheter tip and coil. However, the moment of exposure of the detachment zone

from the microcatheter can be detected instantaneously based on the changes in electrical resistance of a circuit formed by the patient's body and the delivery wire. Guglielmi reported this mechanism and pointed out that removal of a proximal marker allows softening of the device and overcomes the deficit: Formation of the curved shape of the microcatheter tip by heating shortens the catheter, which shortens the distance between the 2 markers, thus reducing the reliability of the proximal marker.<sup>[6]</sup> In addition, consideration of the visibility of the proximal marker while positioning the microcatheter is no longer necessary, which may widen the range of applications with respect to the use of microcatheters without a proximal marker.

When a microcatheter is inserted into a large wide-necked aneurysm, it is inserted from the distal end of the neck and advanced along the aneurysm wall. Thus, the region near the proximal end of the neck is the farthest and most difficult to reach. In particular, when a large daughter aneurysm is present near the proximal end of the neck, this region may not be sufficiently filled with coils unless the microcatheter can reach it. To place the microcatheter tip near the proximal end of the neck, it is necessary to advance the catheter by drawing a circle along the aneurysm wall. Even though a strongly bent microcatheter tip can be directed to a site near the proximal end of the neck through a short cut, the catheter is unstable because it is not supported within the aneurysm, and its direction will be altered toward the distal end of the neck when a coil is inserted. For catheterization by drawing a circle along the wall of a large aneurysm, long distance advancement is necessary, and the coil detachment position cannot be confirmed based on visibility of the second marker because it also enters the aneurysm. Since ED coils do not require visibility, this roll technique can be applied freely. Miyachi *et al.* reported a similar method to prevent localized coil distribution due to the limitation of microcatheter mobility in stent-assisted coil embolization, in which a microcatheter is advanced about 1.5 circumferences of the inner aneurysm wall as one and a half round microcatheterization technique, and ED coils were used because the proximal marker became invisible.<sup>[4]</sup> In this technique, the catheter tip is positioned at the distal dome, without targeting specific compartment or bleb. To embolize protruded compartment or bleb, a microcatheter may have to be advanced to it and to make a circle inside the aneurysm. In such a situation, ED coil is an exclusively useful device.

The plug and push technique using Onyx effectively fills the nidus, but as described by Weber *et al.*, it requires the patience of the operators.<sup>[7]</sup> Plug formation by Onyx reflux requires the procedure be repeated, little by little, slowly, and catheter obstruction may occur in the process. Thus, the use of a balloon and coils, instead of Onyx plug, has been considered, but it is sometimes difficult for balloon catheters to reach to the periphery of a tortuous feeder.



Chapot *et al.* reported a technique to make a proximal plug with injectable or detachable coil and n-Butyl Cyanoacrylate (NBCA) through a microcatheter positioned proximally to a dimethyl sulfoxide-compatible microcatheter with detachable tip (Sonic, Balt Extrusion, Montmorency, France) (Pressure cooker technique).<sup>[8]</sup> Our technique is similar to it but differ in making a compact and short plug with detachable coils alone. The tip of a microcatheter is hidden in the coil mass to make a dense coil mass, but ED coil is precisely positioned for detachment in such situation because it does not depend on the visibility of even distal tip of the microcatheter as well as the proximal marker. The fact that the ED coil is well applicable through Marathon catheter is already described by Horie *et al.*,<sup>[9,10]</sup> though it is not combined with Onyx infusion in their experiences. They used ED coil through Marathon catheter to treat vascular diseases of peripheral vessels such as AVM and dural arteriovenous fistulas (AVF) to block a feeder with coils alone or to reduce feeding flow before the NBCA injection from the same catheter. Our method to make proximal coil plug to facilitate Onyx infusion is another way of utilization of unique characteristics of ED coil.

In addition to the methods described above, several authors have reported a method aiming at the reduction of flow in high-flow AVM and AVF, in which the lesions were initially filled with coils, followed by injection of Onyx from the proximal side of the coil mass.<sup>[11-13]</sup> With the use of ED coils, both coil and Onyx embolization can be applied through a single Marathon catheter in this method, and we currently employ this method.

## Conclusion

Through the use of detachable coils, which are not dependent on the visibility of the proximal marker, the limitation of catheter positioning is reduced and the applicable types of catheter increase, which may facilitate to enable its use for new clinical indications.

## Financial support and sponsorship

Nil.

## Conflicts of interest

There are no conflicts of interest.

## References

1. Guglielmi G, Viñuela F, Duckwiler G, Dion J, Lylyk P, Berenstein A, *et al.* Endovascular treatment of posterior circulation aneurysms by electrothrombosis using electrically detachable coils. *J Neurosurg* 1992;77:515-24.
2. Sadato A, Taki W, Ikada Y, Nakahara I, Matsumoto K, Tanaka M, *et al.* Immediately detachable coil for aneurysm treatment. *AJNR Am J Neuroradiol* 1995;16:1459-62.
3. Sadato A, Taki W, Ikada Y, Kikuchi H. Effect of electrical thrombosis on coil embolization of experimental aneurysms. *J Neurovasc Dis* 1997;2:235-45.
4. Miyachi S, Matsubara N, Izumi T, Asai T, Yamanouchi T, Ota K, *et al.* The 'one and a half round microcatheterization technique' for stent-assisted coil embolization of intracranial aneurysm: Technical case series. *J Neurointerv Surg* 2014;6:357-62.
5. Harada K, Morioka J. Initial experience with an extremely soft bare platinum coil, ED coil-10 extra soft, for endovascular treatment of cerebral aneurysms. *J Neurointerv Surg* 2013;5:577-81.
6. Guglielmi G. Accurate positioning of detachable coils using alternate electric current. A technical note. *Interv Neuroradiol* 2006;12:103-7.
7. Weber W, Kis B, Siekmann R, Kuehne D. Endovascular treatment of intracranial arteriovenous malformations with Onyx: Technical aspects. *AJNR Am J Neuroradiol* 2007;28:371-7.
8. Chapot R, Stracke P, Velasco A, Nordmeyer H, Heddier M, Stauder M, *et al.* The pressure cooker technique for the treatment of brain AVMs. *J Neuroradiol* 2014;41:87-91.
9. Horie N, Hayashi K, Morikawa M, Nagata I. Selective coil embolization through flow-directed microcatheter for intracranial arteriovenous malformations. *Acta Neurochir (Wien)* 2012;154:989-91.
10. Horie N, Hayashi K, Morikawa M, Izumo T, Nagata I. A novel method for super-selective coil embolization using an extremely soft bare coil through a liquid embolic delivery microcatheter. *Neurol Med Chir (Tokyo)* 2015;55:605-9.
11. Gordhan A. Onyx embolization of high-flow spontaneous cervical vertebral arteriovenous fistula. *Vasc Endovascular Surg* 2012;46:484-6.
12. Shi ZS, Loh Y, Gonzalez N, Tateshima S, Feng L, Jahan R, *et al.* Flow control techniques for Onyx embolization of intracranial dural arteriovenous fistulae. *J Neurointerv Surg* 2013;5:311-6.
13. John S, Jaffari N, Lu M, Hussain MS, Hui F. Spontaneous vertebral arteriovenous fistula causing cervical myelopathy and acute ischemic strokes treated by endovascular balloon-assisted coiling and Onyx embolization. *J Clin Neurosci* 2014;21:167-70.