

## Pneumocephalus following Dorsal Laminectomy: An Unusual Complication

### Abstract

A 16-year-old male presented at Bangur Institute of Neurosciences Neurosurgery Outpatient Department with history of gradually progressive paraparesis for 5 months associated with stiffness, urinary hesitancy, and urge incontinence for last 2 months. Magnetic resonance imaging spine was done which showed cystic intradural extramedullary space occupying lesion at D4/D5 to D9. Patient had 2 episodes of generalized tonic-clonic seizure on the day 4. Computed tomography scan showed pneumocephalus. Histopathological examination report was that of nonspecific inflammatory cyst.

**Keywords:** *Dorsal laminectomy, inflammatory cyst, pneumocephalus*

### Introduction

Pneumocephalus is the entry of air into the cranium and can be classified as epidural, subdural, subarachnoid, ventricular, and intracerebral.<sup>[1]</sup> The epidural type is usually seen in patients with a frontal sinus fracture in which the dura mater remains intact, whereas in the subdural type, a dural defect accompanies the cranial fracture. In subarachnoid and ventricular types, the arachnoid is torn in addition to the dural defect. Pneumocephalus after a spinal operation is rare. We present a patient with pneumocephalus after a spinal laminectomy for space occupying lesion (SOL) without any recognized perioperative dural injury.

### Case Report

A 16-year-old male presented at Bangur Institute of Neurosciences Neurosurgery Outpatient Department with history of gradually progressive paraparesis for 5 months associated with stiffness, urinary hesitancy, and urge incontinence for last 2 months. Lower limb (LL) power at the time of admission was 1/5 with normal upper limbs (UL) power 5/5. There was no past history of significant illness. No history of trauma and tuberculosis. On examination, tone was increased in both LLs without any wasting of muscles. Power in both LLs was 1/5. Knee and ankle deep tendon reflex were 4+ in both with the presence of ankle clonus. Planter response

was bilateral extensor. ULs and neck were normal. Magnetic resonance imaging spine was done which showed cystic intradural extramedullary SOL at D4/D5 to D9 [Figure 1] causing cord compression at D6–D8 level. A provisional diagnosis of cystic nerve sheath tumor was made. Patient was operated on April 03, 2014, and total removal was done. The tumor was purely extradural, cystic in nature. There was no recognized dural injury at time of operation. The patient had two episodes of generalized tonic-clonic seizure on the day 4, for which a plain computed tomography (CT) scan was done. CT scan showed pneumocephalus [Figure 2]. Antiepileptics were added and patient improved on conservative management. There were no more seizure episodes. CT myelogram [Figure 3] was done on the postoperative day 8 which suggested that there may be contained cerebrospinal fluid (CSF) leak. However, no definite conclusion could be drawn. LL power improved significantly (4-/5 in both LLs) in the postoperative period and the patient was discharged on the postoperative day 10 on antiepileptics. Histopathological examination report was that of nonspecific inflammatory cyst.

### Discussion

Symptomatic spontaneous pneumocephalus after a spinal fusion for spondylolisthesis without injury to the dura mater is rare.<sup>[2]</sup> Pneumocephalus is not regarded

**Brajesh Kumar,  
Chirantan  
Banerjee<sup>1</sup>,  
Samarendra Nath  
Ghosh**

*Department of Neurosurgery,  
Bangur Institute of  
Neurosciences and IPGME&R,  
<sup>1</sup>Department of Neurosurgery,  
Medical College, Kolkata,  
West Bengal, India*

#### Address for correspondence:

*Dr. Brajesh Kumar,  
Flat 3A, 17, Gobind Bose Lane,  
Kolkata - 700 025, West Bengal,  
India.*

*E-mail: drbrajesh78@gmail.com*

#### Access this article online

**Website:** [www.asianjns.org](http://www.asianjns.org)

**DOI:** 10.4103/1793-5482.185059

#### Quick Response Code:



**How to cite this article:** Kumar B, Banerjee C, Ghosh SN. Pneumocephalus following dorsal laminectomy: An unusual complication. *Asian J Neurosurg* 2017;12:772-3.

This is an open access article distributed under the terms of the Creative Commons Attribution-NonCommercial-ShareAlike 3.0 License, which allows others to remix, tweak, and build upon the work non-commercially, as long as the author is credited and the new creations are licensed under the identical terms.

**For reprints contact:** [reprints@medknow.com](mailto:reprints@medknow.com)

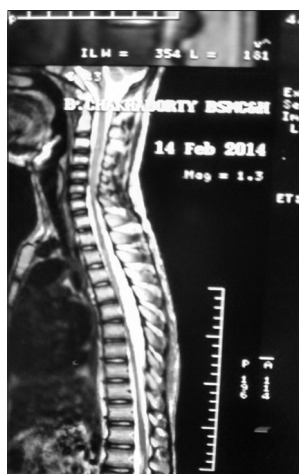

Figure 1: Magnetic resonance imaging dorsal spine showing cystic lesion

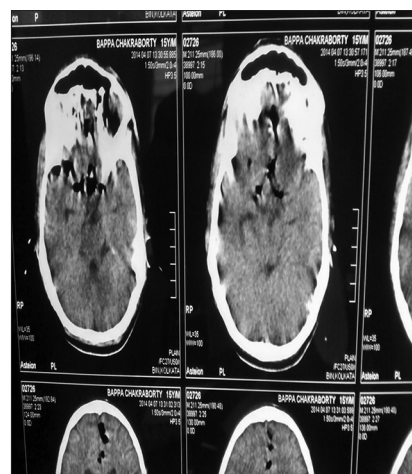


Figure 2: Computed tomography scan showing pneumocephalus

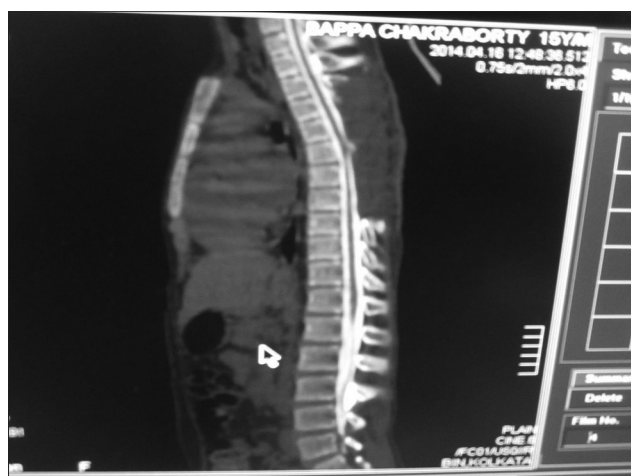

Figure 3: Computed tomography myelogram nonconclusive

as recognized complication of dorsal laminectomy. There are only a few reports of tension pneumocephalus after spinal operations.<sup>[2]</sup> Various theories have been postulated to describe pathophysiology of pneumocephalus, inverted bottle mechanism,<sup>[3]</sup> and Ball valve mechanism.<sup>[3]</sup> According to inverted bottle mechanism<sup>[3]</sup> hypothesis, the continuous leakage of CSF causes negative intracranial pressure within subarachnoid space and negative pressure substitute's air for lost CSF. This substitution ends by balancing the pressure difference. In Ball valve mechanism,<sup>[3]</sup> the air enters the intracranial cavity through a defect whenever extracranial pressure exceeds intracranial pressure (e.g., from the

paranasal sinuses during coughing, sneezing, and swallowing). Ayberk *et al.*<sup>[2]</sup> reported a symptomatic case of pneumocephalus after a spinal fusion that did not involve dural tears. They concluded that increased intra-abdominal pressure due to prone position might have caused the tension pneumocephalus. Use of vacuum drain in the presence of dural leak increases the chance of developing pneumocephalus.<sup>[4]</sup> In our case, the cause may be unrecognized dural leak which closed spontaneously or may be due to increased intra-abdominal pressure.<sup>[2]</sup>

#### Financial support and sponsorship

Nil.

#### Conflicts of interest

There are no conflicts of interest.

#### References

1. Markham JW. The clinical features of pneumocephalus based upon a survey of 284 cases with report of 11 additional cases. *Acta Neurochir (Wien)* 1967;16:1-78.
2. Ayberk G, Yaman ME, Ozveren MF. Symptomatic spontaneous pneumocephalus after spinal fusion for spondylolisthesis. *J Clin Neurosci* 2010;17:934-6.
3. Walker FO, Vern BA. The mechanism of pneumocephalus formation in patients with CSF fistulas. *J Neurol Neurosurg Psychiatry* 1986;49:203-5.
4. Turgut M, Akyüz O. Symptomatic tension pneumocephalus: An unusual post-operative complication of posterior spinal surgery. *J Clin Neurosci* 2007;14:666-8.