

Subcutaneous Schwannoma in the Head Region

Abstract

Schwannoma is a benign neural tumor derived from Schwann cells surrounding the nerves. It occurs primarily in subcutaneous tissues and muscles with a tendency for distal extremities, head, and neck area. Treatment of schwannoma is surgical excision. Lipomas are the most common soft-tissue lesions. A case is presented to increase awareness on differential diagnosis of head and neck subcutaneous masses.

Keywords: *Head and neck tumor, schwannoma, subcutaneous mass*

Introduction

Schwann cell, which separates and insulates nerve cells, is a form of glial cell of the peripheral nervous system. Schwannoma is a benign, nonrecurring tumor arising from cranial nerves, bones, and gastrointestinal tract. It differentiates from Schwann cells.^[1] They are also known as neurilemmoma. It occurs primarily in subcutaneous tissue and muscles with a tendency for distal extremities, head, and neck area. Treatment of schwannomas is surgical excision. Schwannomas are actually a proliferation of the nerve sheath. They are easily noticeable and hence readily separable from the tumor by careful dissection during surgical excision. True capsule is simplifying the surgical dissection. These are benign tumors and malignant transformation is very rare. The aim of our study is to present a case to increase awareness on the differential diagnosis of head and neck subcutaneous masses.

Case Report

A 23-year-old female admitted to our clinic with a painless and fast growing lesion on the scalp. She had no neurological deficits. A palpable and mobile tumor was observed on the right parietooccipital region. Computed tomography showed a lesion [Figure 1] which has a long axis of 30 mm. Radiographic imaging has provided limited information. Certain diagnosis of schwannomas is provided by histopathological study of the pathological

specimen. She was operated and tumor was totally resected [Figure 2]. The streptavidin-biotin peroxidase method revealed nuclear and cytoplasmic positivity for S-100, and Ki-67 proliferation index was found to be 5%. The Antoni A and B patterns were seen. It was diagnosed as schwannoma.

Discussion

Schwannoma is a neural tumor derived from Schwann cells surrounding the nerves.^[1] Occurrence in the head and neck region is common.^[2] Extracranial schwannomas occur in the head and neck region (25–45%).^[3] They can appear at any age but are most commonly seen between the ages of 20 and 50.^[4] Two-thirds of the study population were female in a study by Torossian *et al.* observing female predominance in extracranial cephalic schwannomas.^[5] On the other hand, Leu and Chang's series shows male predominance.^[6]

Schwannomas often appear as painless and slow-growing tumor, without neurological symptoms initially.^[7] Depending on the original nerve and localization, the mass effect can cause symptoms such as cough, dysphagia, cranial nerve paralysis, Horner syndrome, or even hearing loss.^[7] The patient presented in this paper had a fast growing tumor in 3 months and had no neurological deficits.

Clinically, these benign tumors are easily mistaken for other lesions such as lipoma and pleomorphic adenoma.^[8,9] This is

**Umit Eroglu,
Fatih Yakar,
Murat Zaimoglu,
Emre Sayaci,
Onur Ozgural,
İhsan Dogan,
Hasan Caglar Ugur**

*Department of Neurosurgery,
Ankara University Medical
School, İbni Sina Hospital,
Ankara, Turkey*

Address for correspondence:

*Dr. Umit Eroglu,
Ankara University Medical
School, İbni Sina Hospital,
06100 Ankara, Turkey.
E-mail: umitkovikeroглу@
hotmail.com*

Access this article online

Website: www.asianjns.org

DOI: 10.4103/1793-5482.185064

Quick Response Code:



How to cite this article: Eroglu U, Yakar F, Zaimoglu M, Sayaci E, Ozgural O, Dogan I, *et al.* Subcutaneous schwannoma in the head region. *Asian J Neurosurg* 2018;13:96-7.

This is an open access article distributed under the terms of the Creative Commons Attribution-NonCommercial-ShareAlike 3.0 License, which allows others to remix, tweak, and build upon the work non-commercially, as long as the author is credited and the new creations are licensed under the identical terms.

For reprints contact: reprints@medknow.com

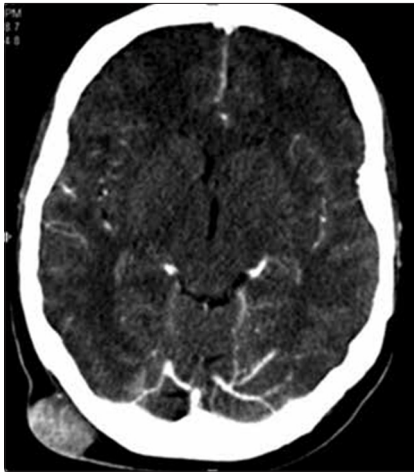

Figure 1: Computed tomography scan of subcutaneous mass

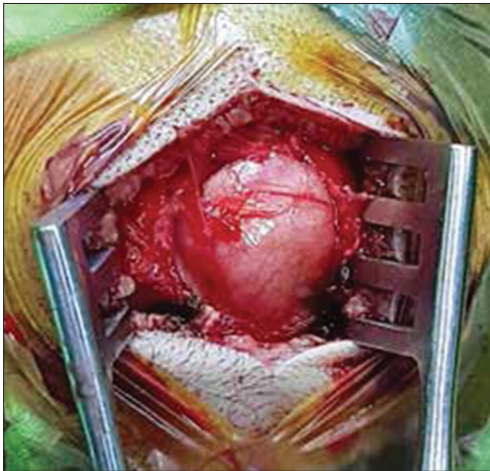


Figure 2: Intraoperative view of lesion

mainly because of their slow growth and absence of neurological symptoms. In our case, our preoperative diagnosis was lipoma. Lipomas are the most common soft-tissue tumor and contain adipose fat.^[10] Hence, we did not plan a biopsy and operated with a straight incision. There was no evidence of malignancy despite the fast growing nature of lesion intraoperatively and so, we performed only lesionectomy.

Metastatic or reactive lymphadenopathy, paraganglioma, angioma, carotid artery aneurysm, branchial cleft cyst,

and other neurogenic tumors should be included in the differential diagnosis of schwannomas.^[11]

Conclusion

An important conclusion is that the differential diagnosis of small painless nodules in the head and neck should include schwannomas.

Financial support and sponsorship

Nil.

Conflicts of interest

There are no conflicts of interest.

References

1. Eroglu U, Bozkurt M, Ozates O, Akturk S, Tuna H. Sciatic nerve schwannoma: Case report. *Turk Neurosurg* 2014;24:120-2.
2. Yasumatsu R, Nakashima T, Miyazaki R, Segawa Y, Komune S. Diagnosis and management of extracranial head and neck schwannomas: A review of 27 cases. *Int J Otolaryngol* 2013;2013:973045.
3. Colreavy MP, Lacy PD, Hughes J, Bouchier-Hayes D, Brennan P, O'Dwyer AJ, *et al.* Head and neck schwannomas – A 10 year review. *J Laryngol Otol* 2000;114:119-24.
4. Malone JP, Lee WJ, Levin RJ. Clinical characteristics and treatment outcome for nonvestibular schwannomas of the head and neck. *Am J Otolaryngol* 2005;26:108-12.
5. Torossian JM, Beziat JL, Abou Chebel N, Devouassoux-Shisheboran M, Fischer G. Extracranial cephalic schwannomas: A series of 15 patients. *J Craniofac Surg* 1999;10:389-94.
6. Leu YS, Chang KC. Extracranial head and neck schwannomas: A review of 8 years experience. *Acta Otolaryngol* 2002;122:435-7.
7. Ku HC, Yeh CW. Cervical schwannoma: A case report and eight years review. *J Laryngol Otol* 2000;114:414-7.
8. Pfeifle R, Baur DA, Paulino A, Helman J. Schwannoma of the tongue: Report of 2 cases. *J Oral Maxillofac Surg* 2001;59:802-4.
9. Zachariades N, Skoura C, Papageorgiou G, Chrissomali E. Giant ancient neurilemmoma of the cervical region: Report of case. *J Oral Maxillofac Surg* 2001;59:668-72.
10. Murphey MD, Carroll JF, Flemming DJ, Pope TL, Gannon FH, Kransdorf MJ. From the archives of the AFIP: Benign musculoskeletal lipomatous lesions. *Radiographics* 2004;24:1433-66.
11. Hood RJ, Reibel JF, Jensen ME, Levine PA. Schwannoma of the cervical sympathetic chain. The Virginia experience. *Ann Otol Rhinol Laryngol* 2000;109:48-51.