

Vertex Extradural Hematoma: A Diagnostic Dilemma

Abstract

Extradural hematomas (EDHs) of vertex are rarely seen and form a small percentage of all EDH. Usual cause of an EDH located at the vertex is tearing of the superior sagittal sinus. A 35-year-old male patient was admitted to our department, with history of fall and lucid interval. Imaging studies showed contusion in the right frontal region with midline shift and bilateral EDH located at vertex which was misinterpreted as artifact or subdural hematoma. We present this rare case and briefly review the literature regarding its etiopathology and associated clinico-radiological findings. The principles of management of this rare entity are also discussed.

Keywords: *Lucid interval, superior sagittal sinus, vertex extradural hematoma*

Introduction

Extradural hematomas (EDHs) located at vertex form a very small percentage of all EDH. The usual cause of EDH located at vertex is a tear in superior sagittal sinus, unlike at other places where the source is an arterial one. The EDH located at vertex frequently causes diagnostic confusion, both clinically and radiologically. Patient presents with features of raised intracranial pressure which do not contribute to the establishment of a specific diagnosis. Computed tomography (CT) scan of the head, especially the coronal view, can help diagnose a vertex EDH; however, attention has to be given not to mistake it for an artifact or subdural hematoma. Magnetic resonance imaging (MRI) is a better diagnostic tool and further helps in confirming the diagnosis. Vertex EDH may be managed conservatively or surgically depending on the size of hematoma, clinical status of the patient and other associated radiological findings.

Case Report

A 45-year-old male was admitted to our department after about 6 h of falling from a rooftop. His relatives gave a history of brief loss of consciousness for 15 min following the fall, after which he regained consciousness and complained of headache. The patient also had multiple episodes of

This is an open access article distributed under the terms of the Creative Commons Attribution-NonCommercial-ShareAlike 3.0 License, which allows others to remix, tweak, and build upon the work non-commercially, as long as the author is credited and the new creations are licensed under the identical terms.

For reprints contact: reprints@medknow.com

vomiting and attacks of convulsions after the injury. There was a scalp swelling and laceration (1" linear wound) in the right frontal region. At the time of admission, the patient was unconscious with Glasgow coma scale (GCS) score of E2V3M4 (9/15) with weakness of left side. CT scan of head [Figure 1] showed a large heterogeneous density in the frontoparietal region more on the right side with right frontal contusion and midline shift. There was no evidence of any fracture.

Urgent surgery was offered to the patient and his family to which they agreed. On raising the bone flap, the brain was found to be tense. Large vertex EDH was evacuated from the right side, and dural tenting was done. After the removal of EDH brain became lax. Right frontal dura was opened for evacuation of the contusion and lax duraplasty was performed. The patient was discharged on postoperative day 14 with a GCS of E3V4M6 (13/15) with no apparent weakness of the left side of the body. Postoperative CT scan of the head [Figure 2] showed resolving right frontal contusion with small residual vertex EDH. The postoperative period was uneventful, and he returned for follow-up after 2 months, with a GCS of 15/15 and without any fresh complaints.

Discussion

Guthrie, in 1862, reported the first case of vertex EDH.^[1] Ramesh *et al.* reported

How to cite this article: Kumar J, Prakash A, Harsh V, Kumar A. Vertex extradural hematoma: A diagnostic dilemma. *Asian J Neurosurg* 2017;12:718-20.

**Jayendra Kumar,
Anand Prakash¹,
Viraat Harsh¹,
Anil Kumar¹**

*Department of Neurosurgery,
Narayan Medical College and
Hospital, Sasaram, Bihar;*

*¹Department of Neurosurgery,
Rajendra Institute of Medical
Sciences, Ranchi,
Jharkhand, India*

Address for correspondence:

*Dr. Jayendra Kumar,
Department of Neurosurgery,
Narayan Medical College and
Hospital, Sasaram, Bihar, India.
E-mail: drjayendra00@gmail.com*

Access this article online

Website: www.asianjns.org

DOI: 10.4103/1793-5482.215758

Quick Response Code:



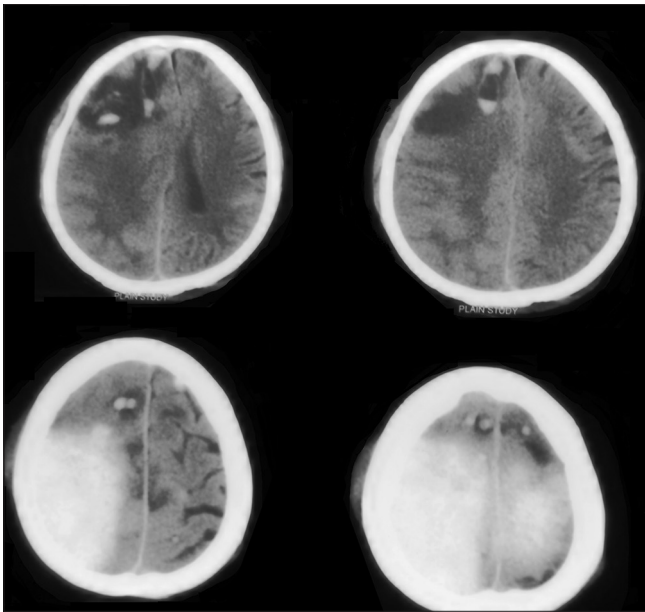


Figure 1: Vertex extradural hematoma more in right with right frontal contusion

the largest series of vertex EDH of 29 cases from a retrospective study of over 17 years.^[2] Vertex EDH constitutes about 1–8% of all EDH.^[2] They had a mortality of 18–50% in the pre-MRI period.^[3] The cause of vertex EDH is either sagittal sinus tear or the dural stripping from inner table of the skull or from fracture line itself, although spontaneous vertex EDH has also been reported in literature.^[4]

Vertex EDH presents with nonspecific clinical features; hence, clinically localizing the lesion is difficult. Vertex EDH may be acute or chronic. Acute presentation usually occurs with large tear in the superior sagittal sinus or the source of bleeding may be arterial. Morbidity and mortality in such cases are very high.

Worsening headache and vomiting are the most common symptoms. Wylene and Nanda^[5] reported paraplegia in a case of vertex EDH. Borzone *et al.* also found hemiplegia in their series.^[6] Our case presented with left hemiparesis. Compression of the motor homunculus where upper and lower limbs lie in close proximity, may have caused the hemiparesis.

Vertex EDH can easily be missed on a CT scan unless high axial cuts and coronal views have been ordered. Misinterpreting vertex EDH as an artifact is also common. The first case in the literature in which MRI was used to diagnose a vertex EDH was reported by Ramesh and Sivakumar in 1995.^[7]

Management of these cases depend on clinical signs and symptoms, clot volume, amount of displacement or distortion of sagittal sinus, and mass effect on brain. Pathophysiology of vertex hematoma is entirely different from the EDH on other sites; hence, even a small amount

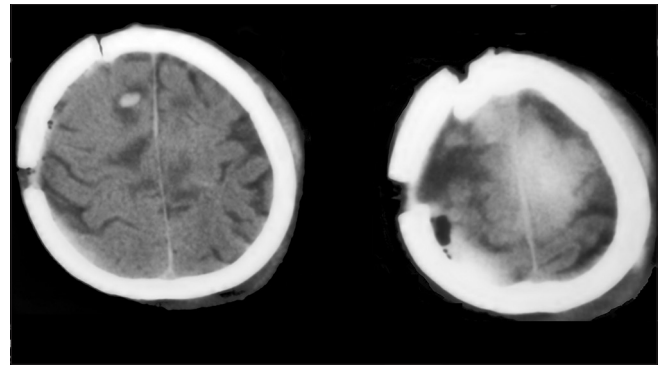


Figure 2: Postoperative computed tomography scan showing residual vertex extradural hematoma

of bleed may need surgery.^[8] At the same time, an asymptomatic small EDH may not need surgery.^[9] During surgery, a tear in the sagittal sinus may get exposed and may lead to significant blood loss and even lead to air embolism. In our case too, the source of EDH was draining venous sinus tear although intraoperatively there was no obvious sagittal sinus tear.

Conclusion

Any degree of confusion on high axial head CT scan should prompt a neurosurgeon to do coronal CT scan or MRI of the brain to exclude a vertex EDH. Early diagnosis and treatment may help decrease the mortality and morbidity in this rare disease pathology.

Financial support and sponsorship

Nil.

Conflicts of interest

There are no conflicts of interest.

References

1. Guthrie GJ. Commentaries on the Surgery of the Portugal, Spain, France and the Netherlands, from the Battle of Rolicia in 1808 to that of Waterloo, in 1815; with Additions Relating to those in the Crimean in 1854-1855. Showing the Improvements Made During and Since that Period in the Great Art and Science of Surgery and All the Subjects to Which They Relate. 6th ed. Philadelphia: J. B. Lippincott; 1862.
2. Ramesh VG, Kodeeswaran M, Deiveegan K, Sundar V, Sriram K. Vertex epidural hematoma: An analysis of a large series. *Asian J Neurosurg* 2017;12:167-71.
3. Miller DJ, Steinmetz M, McCutcheon IE. Vertex epidural hematoma: Surgical versus conservative management: Two case reports and review of the literature. *Neurosurgery* 1999;45:621-4.
4. Dufour H, Métellus P, Manera L, Fuentes S, Do L, Grisoli F. Spontaneous vertex extradural hematoma: Considerations about causes. Case report and review of the literature. *J Neurosurg* 2001;94:633-6.
5. Wylene EL, Nanda A. Vertex epidural hematoma with coronal suture diastasis presenting with paraplegia. *J Trauma* 1998;45:413-5.
6. Borzone M, Gentile S, Perria C, Rivano C, Rosa M. Vertex

- epidural hematomas. *Surg Neurol* 1979;11:277-84.
7. Ramesh VG, Sivakumar S. Extradural hematoma at the vertex: A case report. *Surg Neurol* 1995;43:138-9.
 8. Song JH, Park JY, Lee HK. Vertex epidural hematomas: Considerations in the MRI era. *J Korean Med Sci* 1996;11:278-81.
 9. Hadley MN, Carter LP. Nonoperative treatment of epidural hematomas. *Neurosurgery* 1985;16:435.