

## Scrotal Migration of Tubing: An Unusual Complication after Ventriculo-peritoneal Shunt

### Abstract

Scrotal migration of peritoneal end of ventriculo-peritoneal (VP) shunt into the patent processus vaginalis (PPV) is a rare complication. Its exact incidence is not mentioned in the literature till date. This may be because of the rarity of this complication, and also because all previous articles related to the complication were case reports. We, in our series, had an incidence of 0.9%. This prospective study has been conducted on 437 patients in the age group of 1 month–3 years who underwent VP shunt for hydrocephalus over a period of 5 years from 2007 to 2011. The incidence of a hernia manifesting after shunt insertion has been reported to be around 16.8%. The average age of patients at the time of insertion of the shunt was 27.25 months (3–48 months). All our patients presented with swollen right sided scrotum after an average of 4 months (3–5 months) after shunt insertion. Shunt migration was more common on the right which is consistent with the incidence of hernias in children. The proper management of such cases includes repositioning of the catheter with the proper closure of the PPV. Usually, shunt revision is not required. We discuss the etiology, treatment and preventive measures of this rare entity.

**Keywords:** Complications, hernia, patent processus vaginalis, shunt migration, ventriculo-peritoneal shunt

### Introduction

Ventriculo-peritoneal (VP) shunt is a commonly done procedure for the treatment of hydrocephalus. The procedure is inherent with many reported complications related to the entire shunt system. However, a large majority of complications are related to the distal catheter migration. We here report four cases of scrotal migration of the distal shunt catheter.

### Materials and Methods

The study was conducted on 437 cases of congenital hydrocephalus who underwent VP shunt over a period of 5 years (2007–2011). We had four cases of scrotal migration of the distal end of the shunt catheter. The incidence of this complication was 0.9% in our series for both congenital hydrocephalus (3/329) and lumbosacral meningocele with hydrocephalus (1/108). The average age of patients at the time of insertion of the shunt was 27.25 months (3–48 months). All our patients presented with swollen right side scrotum after an average of 4 months (3–5 months) after shunt insertion.

This is an open access article distributed under the terms of the Creative Commons Attribution-NonCommercial-ShareAlike 3.0 License, which allows others to remix, tweak, and build upon the work non-commercially, as long as the author is credited and the new creations are licensed under the identical terms.

For reprints contact: reprints@medknow.com

There were no other complaints. The shunt of three of the four patients was functioning well while one patient had slow refill with noncompressible shunt chamber. All were placed a low-pressure Chhabra shunt, with the peritoneal end in the supra-hepatic space, without reduction of the length of the peritoneal end. Other demographic data of the patients are shown in Table 1. An erect abdominal roentgenogram confirmed the presence of shunt tubing in the scrotum [Figure 1].

### Discussion

Since the first case description by Grosfeld and Cooney,<sup>[1]</sup> there have been 28 cases reported of this complication. A review by Kita *et al.*<sup>[2]</sup> revealed that this complication occurred at age <18 months and at an average of 3–4 months after shunt surgery. In our series, we had similar results. However, one case has also been reported in adult at 57 years in a lumbo-peritoneal shunt.<sup>[3]</sup> In the original series by Grosfeld and Cooney<sup>[1]</sup> the average time for this complication after shunt surgery was 6.8 months. Shunt migration was more common on the right which is consistent with the

**How to cite this article:** Bawa M, Garge S, Garg R, Narasimha Rao KL. Scrotal migration of tubing: An unusual complication after ventriculo-peritoneal shunt. *Asian J Neurosurg* 2017;12:738-40.

**Monika Bawa,  
Saurabh Garge,  
Ravi Garg,  
Katragadda  
Lakshmi Narasimha  
Rao**

Department of Pediatric Surgery, Advanced Pediatric Center, Post Graduate Institute of Medical Education and Research, Chandigarh, India

**Address for correspondence:**  
Dr. Monika Bawa,  
Department of Pediatric Surgery, Advanced Pediatric Center, Post Graduate Institute of Medical Education and Research, Sector 12, Chandigarh - 160 012, India.  
E-mail: monikabawa@hotmail.com

#### Access this article online

Website: www.asianjns.org

DOI: 10.4103/1793-5482.215783

#### Quick Response Code:



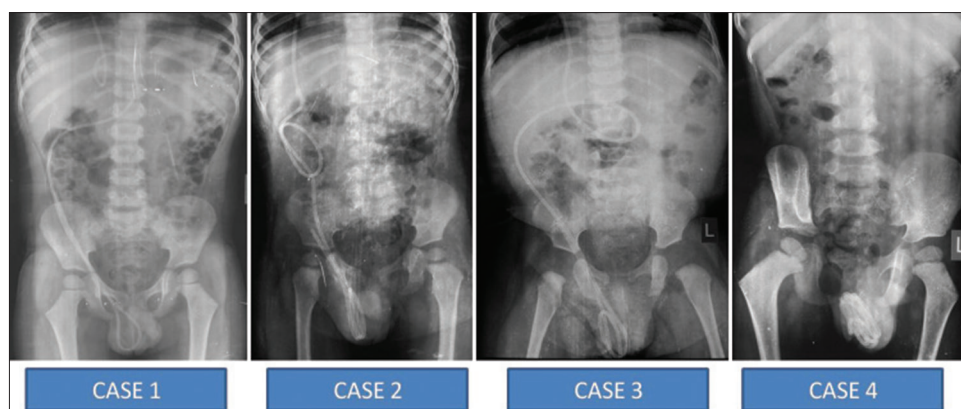


Figure 1: Abdominal X-rays showing migration of the shunt catheter

Table 1: Presentation and characteristics of the patients

	Age at shunt insertion	Time of presentation after shunt insertion	VHR at shunt insertion (%)	Type of shunt	Shunt functional	Associated morbidity	Treatment
Case 1	3 months	4 months	54	Chhabra (LP)	Yes	LSMMC + CTEV	Herniotomy + shunt replacement in suprahepatic space
Case 2	4 years	3 months	66	Chhabra (LP)	Yes	Seizures	Herniotomy + shunt replacement in suprahepatic space
Case 3	10 months	5 months	78	Chhabra (LP)	Yes	None	Herniotomy + shunt replacement in suprahepatic space
Case 4	4 years	4 months	56	Chhabra (LP)	No	None	Herniotomy + shunt removal + Lt side VP Shunt

LP – Low pressure; VHR – Ventriculo-hemispheric ratio; LSMMC – Lumbosacral meningomyelocele; CTEV – Congenital talipes equino varus; VP – Ventriculo peritoneal

incidence of hernias in children (right - 60%, left - 30%, bilateral - 10%).<sup>[2]</sup>

The incidence of a hernia manifesting after shunt insertion has been reported to be around 16.8%.<sup>[1,2]</sup> However, the incidence of scrotal migration of peritoneal end of the shunt into the hernia sac has not been mentioned in various series. This may be because of the rarity of this complication, and also because all previous articles related to the complication were case reports. We in our series had an incidence of 0.9%.

Various mechanisms for scrotal migration have been described in the literature. The most accepted mechanism of scrotal migration is due to an increased incidence of inguinal hernias believed secondary to increased intra-abdominal pressure (15–20% vs. 1–5% in term infants). The presence of raised intra-abdominal fluid and/or pressure may prevent the natural closure of the processus vaginalis (PV). With time this raised pressure may convert a patent PV (PPV) from a potential to a clinical hernia. The PV remains patent in 90% of boys at birth, 40–60% at 1 year, 40% between 2–16 years, and 15–30% in adulthood. The peritoneal volume is related to the body surface area (80 ml/m<sup>2</sup>).<sup>[1-6]</sup> Thus young children with a small peritoneal cavity and PPV are more prone for scrotal migration. Moreover at this young age the inguinal canal is vertical and combined with a “trough effect”

created by the PPV and raised intra-abdominal pressure leads to easier migration of shunt tube in the scrotum.<sup>[1-6]</sup>

Other theories put forth include muscular weakness in cases with associated meningomyeloceles, increased abdominal pressures after the closure of large meningomyelocele, bowel peristalsis causing traction on the catheter and impaired absorbing capacity of the peritoneal cavity. These can also be contributory to the above theory of raised intra-abdominal pressure.<sup>[5]</sup>

The proper management of such cases includes repositioning of the catheter with the proper closure of the PPV. Usually, shunt revision is not required.<sup>[1-8]</sup> Some authors have advised for a contralateral exploration too.<sup>[7,8]</sup> However, we recommend frequent checks for palpable hernias after VP shunt placement. The removal of detached shunt tube has also been described laparoscopically.<sup>[9]</sup> Laparoscopic procedure apart from the traditional advantages of minimal invasiveness has other advantages too. First, during laparoscopy the contralateral side can also be seen and dealt with. Second, it can help in proper placement of the distal catheter, especially in cases with multiple adhesions. The scrotal migration of catheter is not a very threatening complication but may present with an acute scrotum,<sup>[7]</sup> incarcerated hernia (high chances in infants and younger children),<sup>[1,5]</sup> or can be confused with a para-testicular tumor,<sup>[10]</sup> with scrotal perforation also been reported.<sup>[11]</sup>

Even though benign, the complication must be prevented, which again can be difficult. Use of lengthy catheters in order to avoid frequent shunt change and use of low-pressure shunts in all cases leading to increased drainage can be some of the modifiable factors to prevent this complication. Avoiding extra tight sutures at the connections can also be done. Use of laparoscopy to place distal catheters can also be used. The technique adopted by us varies in a step where the long shunt is formed into a coil by using loose catgut sutures and then placing the coil in the right subdiaphragmatic space.<sup>[1,2]</sup> How much help does this step offers are questionable, but the lower incidence of this complication in our cases can be attributed to this. This step theoretically prevents the shunt tube displacement at least in the early postoperative period, when the chances of scrotal migration are reported to be the highest in all previous series.<sup>[1,2]</sup>

Transscrotal migration of shunt is a rare but benign complication of shunt surgery. Its treatment is easy. However the prevention is difficult. The above methods can help in preventing some cases.

#### Financial support and sponsorship

Nil.

#### Conflicts of interest

There are no conflicts of interest.

#### References

- Grosfeld JL, Cooney DR. Inguinal hernia after ventriculoperitoneal shunt for hydrocephalus. *J Pediatr Surg* 1974;9:311-5.
- Kita D, Hayashi Y, Kinoshita M, Ohama K, Hamada J. Scrotal migration of the peritoneal catheter of a ventriculoperitoneal shunt in a 5-year-old male. Case report. *Neurol Med Chir (Tokyo)* 2010;50:1122-5.
- Kimura T, Tsutsumi K, Morita A. Scrotal migration of lumboperitoneal shunt catheter in an adult – Case report. *Neurol Med Chir (Tokyo)* 2011;51:861-2.
- Agarwal T, Pandey S, Niranjana A, Jain V, Mishra S, Agarwal V. Unusual complication of ventriculoperitoneal shunt surgery. *J Pediatr Neurosci* 2009;4:122-3.
- Mohammadi A, Hedayatiasl A, Ghasemi-Rad M. Scrotal migration of a ventriculoperitoneal shunt: A case report and review of literature. *Med Ultrason* 2012;14:158-60.
- Ho CC, Jamaludin WJ, Goh EH, Singam P, Zainuddin ZM. Scrotal mass: A rare complication of ventriculoperitoneal shunt. *Acta Medica (Hradec Kralove)* 2011;54:81-2.
- Shahizon AM, Hanafiah M, Hing EY, Julian MR. Migration of a fractured ventriculoperitoneal shunt into the scrotum: A rare complication. *BMJ Case Rep* 2013;2013:1-3.
- Shankar B, Narayanan R, Paruthikunnan SM, Kulkarni CD. Scrotal migration of ventriculoperitoneal shunt. *BMJ Case Rep* 2014;2014:1-2.
- Jackson CC, Chwals WJ, Frim DM. A single-incision laparoscopic technique for retrieval and replacement of disconnected ventriculoperitoneal shunt tubing found in the peritoneum. *Pediatr Neurosurg* 2002;36:175-7.
- Silver RI, Docimo SG. A ventriculoperitoneal shunt masquerading as a paratesticular tumor. *J Pediatr Surg* 2000;35:1407-8.
- Rehm A, Bannister CM, Victoratos G. Scrotal perforation by a ventriculoperitoneal shunt. *Br J Neurosurg* 1997;11:443-4.
- Pandey A, Gangopadhyay AN, Sharma SP, Upadhyaya VD, Kumar V, Gopal SC, *et al.* Placement of the peritoneal end of a ventriculoperitoneal shunt in the suprahepatic space: Does it improve prognosis? *Pediatr Neurosurg* 2009;45:6-10.