

Endoscopic Management of a Fourth Ventricular Cyst

Abstract

We report a case of a 12-year-old boy with previously shunted congenital hydrocephalus, presenting with a progressive headache, nausea, vomiting, and lethargy. In the brain magnetic resonance imaging, a large cyst was seen in the superior recess of the fourth ventricle extending through the cerebral aqueduct toward the third ventricle. Endoscopic dual fenestration of the cyst was performed successfully using the posterior suboccipital approach through the foramen of Magendie, which resulted in the relief of symptoms without any complications, and the patient was symptom-free in the subsequent follow-up visits for 4 years.

Keywords: Cerebral aqueduct, cyst, endoscopy, hydrocephalus, raised intracranial pressure, ventricle

Introduction

Intraventricular cystic lesions can cause noncommunicating hydrocephalus and compress the adjacent neural tissue. The cyst might be overlooked in the brain magnetic resonance imaging (MRI) because it is often difficult to appreciate the delicate wall of the cyst; the image might be mistakenly interpreted simply as dilation of the ventricle if the cyst occupies most of the ventricular space.^[1,2] Proper identification of the cyst is necessary to ensure appropriate management.^[3]

We report the case of a large cystic lesion located inside the fourth ventricle extending up through the cerebral aqueduct toward the third ventricle.

Case Report

A 12-year-old boy presented with the signs of raised intracranial pressure including a progressive headache, nausea/vomiting, and lethargy following a minor head trauma. The patient had a history of prematurity (gestational age of 30 weeks) due to premature rupture of the membranes. Diagnosed with hydrocephalus in the early infancy, he had undergone ventriculoperitoneal (VP) shunting at the age of 6 months and had several shunt revision surgeries since then. The medical records including previous brain imaging

and the reports of surgeries performed in other institutions were not available. There was no notable family history. Physical examination revealed delayed filling of the shunt's pump. Neurological examination was unremarkable.

A brain MRI with and without contrast showed dilation of the cerebral aqueduct and enlargement of the fourth ventricle. A cystic area existed within the fourth ventricle, extending through the cerebral aqueduct toward the third ventricle. The cyst contained a fluid with the signal intensity similar to the cerebrospinal fluid (CSF) and was not enhanced after administration of the intravenous contrast. These findings were compatible with an intraventricular arachnoid cyst.

Based on these findings, we scheduled two procedures: Replacement of the pump of the shunt and endoscopic fenestration (ECF) of the cyst. A midline suboccipital craniotomy was made. Cerebellar tonsils were identified and separated, and a straight rigid endoscope (Gaab®, KARL STROZ®, Tuttlingen, Germany) was inserted into the fourth ventricle through the median aperture. Subsequently, the inferior wall of the cyst was visualized and was delicately punctured; a clear CSF-like fluid was drained from the cyst to the ventricular cavity. The endoscope was then gently introduced into the cyst, which allowed inspection of the interior cavity as well

**Saba Jafarpour^{1,2},
Morteza Faghih
Jouibari³,
Leila Aghaghazvini⁴,
Vafa
Rahimi-Movaghar^{2,3,5}**

¹Department of Neurology, Boston Children's Hospital, Boston, MA, USA, ²Sina Trauma and Surgery Research Center, Tehran University of Medical Sciences, Departments of ³Neurosurgery and ⁴Radiology, Shariati Hospital, Tehran University of Medical Sciences, ⁵Research Centre for Neural Repair, University of Tehran, Tehran, Iran

Address for correspondence:
Prof. Vafa Rahimi-Movaghar,
Sina Trauma and Surgery
Research Center, Sina Hospital,
Hassan-Abad Square, Imam
Khomeini Ave., Tehran
University of Medical Sciences,
Tehran 11365-3876, Iran.
E-mail: v_rahimi@sina.tums.
ac.ir; v_rahimi@yahoo.com

Access this article online

Website: www.asianjns.org

DOI: 10.4103/1793-5482.228533

Quick Response Code:



How to cite this article: Jafarpour S, Jouibari MF, Aghaghazvini L, Rahimi-Movaghar V. Endoscopic management of a fourth ventricular cyst. Asian J Neurosurg 2018;13:503-6.

This is an open access journal, and articles are distributed under the terms of the Creative Commons Attribution-NonCommercial-ShareAlike 4.0 License, which allows others to remix, tweak, and build upon the work non-commercially, as long as appropriate credit is given and the new creations are licensed under the identical terms.

For reprints contact: reprints@medknow.com

as the superior wall of the cyst. There was no solid or nodular tissue within the cyst, and no signs of infection or hemorrhage were noted. The cyst had extended to the cerebral aqueduct, entering the third ventricle, and both internal cerebral veins were visible through the superior wall of the cyst. An opening was made in the most anterior and superior part of the cyst wall, resulting in a free flow of CSF from the third ventricle. After the surgery, the patient recovered favorably and was discharged in a good condition.

The patient remained asymptomatic during the subsequent follow-up visits. In a visit 4 years postsurgery, evaluation of cognitive function revealed an impairment; the patient was not able to proceed more than the fifth grade. The function of VP shunt was satisfactory on examination. MRI study with and without contrast revealed the persistence of the cyst albeit with a reduced size as compared to before the ECF. The cyst was not associated with any significant mass effect [Figure 1].

Discussion

Based on the clinical and imaging features, the lesion was most consistent with an intraventricular arachnoid cyst. However, the restricted field of action during the endoscopic procedure did not allow us to harvest adequate sample for the histopathological study. In the absence of histopathological examination, it is not possible to confirm the nature of the cyst. For instance, ependymal cysts cannot

be differentiated from arachnoid cysts solely based on radiological characteristics.^[2] In a recent report of a cystic lesion of the fourth ventricle with a pre- and intra-operative diagnosis of arachnoid cyst, the lesion turned out to be a neuroepithelial cyst after performing histopathological examinations.^[4]

The lesion appeared to be an acquired cyst rather than congenital, as no cyst had been noted in several magnetic imaging studies performed in the prior years from early childhood up to the time of presentation. Arachnoid cysts are usually congenital, but can also be acquired on rare occasions. There are reports of secondary arachnoid cysts developed after trauma, surgery, or infection.^[5] A case of a post-traumatic arachnoid cyst was described by Guzel *et al.*^[6] In addition, Shiba *et al.* described the case of a secondary arachnoid cyst of the third ventricle in a patient who had a history of the previous excision of a colloid cyst located in the third ventricle, accompanied by VP shunting which further required several shunt revisions. The authors postulated that the arachnoid membrane might have been pushed into or seeded into the ventricular cavity during the prior surgical manipulations.^[1] This assumption makes a secondary arachnoid cyst more probable.

Endoscopic cyst fenestration is considered the procedure of choice for initial decompression of the symptomatic arachnoid cysts,^[7-9] as it is less invasive and causes less postoperative complications. Endoscopic management

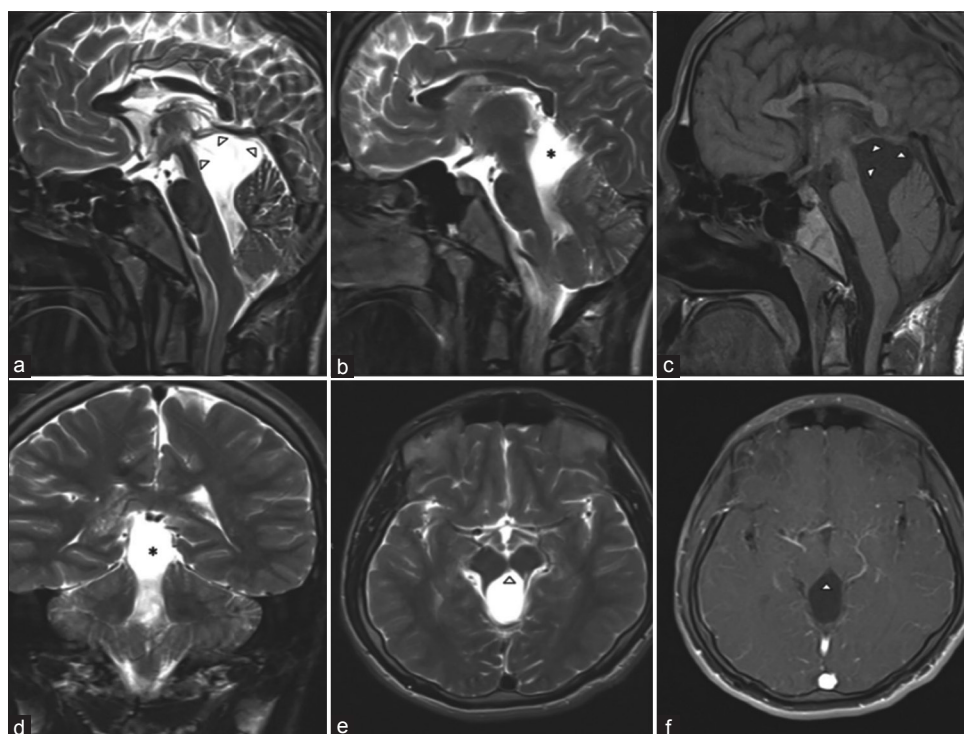


Figure 1: Intraventricular cyst causing dilation of the fourth ventricle and cerebral aqueduct. (a, b, d and e) Mid-sagittal, coronal, and transverse T2-weighted sequences. (c) T1-weighted mid-sagittal section. (f) T1-weighted transverse section after intravenous contrast administration. The content of the cyst (asterisks) exhibits signal intensity comparable to the cerebrospinal fluid in all sequences, distinguished from the turbulent flow of the intraventricular cavity outside the cyst. The fine cyst wall is noticeable in the superior and anterior portions (arrow heads)

of arachnoid cyst has been shown to be an effective and safe method.^[10-12] Microsurgical cyst fenestration or shunting procedures can be performed subsequently if the endoscopic procedure failed.^[9,13] Microsurgical complete cyst resection was associated with the complete recovery and resolution of the cyst;^[2,3,14-18] however, a case of postoperative mortality due to cerebral ischemic stroke was reported.^[19] Complete surgical cyst resection is presumed the definitive treatment.^[2,3] However, there have been complications such as postoperative malignant irreversible global cerebral edema.^[20]

Open surgery is shown to have a high success rate (54–96%) in terms of control of clinical symptoms and reduction of the cyst size, yet has a complication rate of 8.3–28%. A disadvantage of the open surgery is that abrupt cyst drainage, especially in case of large cysts that exert substantial pressure on the surrounding tissue, has the risk of sudden change in cerebral blood flow dynamics and failure of auto-regulatory mechanisms to re-adjust to the new condition, resulting in reperfusion injury and cerebral edema which could be life-threatening. This complication was reported by Baldawa *et al.*^[20] A 21-year-old woman died following surgical decompression of a fourth ventricular arachnoid cyst due to the development of malignant irreversible global cerebral edema. More gradual CSF drainage and slow decompression, which could be achieved by ECF of the cyst, would avoid such complications.^[11] On the other hand, open surgery has the advantage of providing a wider field of view and enabling full resection of membranes, with a better control of the bleeding.^[21]

Endoscopic approach is shown to have a success rate comparable to open surgery: 87–97% in cyst opening, 66–96% in the improvement of clinical symptoms, and up to 80% in cyst size reduction.^[21] Modern neuroendoscopic techniques offer direct and close visualization of the cyst,^[5] and their minimal invasiveness leads to less postoperative complications than the open surgery.^[12]

The shunting procedure has its own complications: 10–40% risk of malfunction and 5–10% rate of infection. In the case of previously shunted patients, endoscopic treatment alone is considered a valid alternative to open surgery. It has a good success rate in terms of relief of the clinical symptoms and reduction of the cyst size.^[21] Some authors suggest that cyst fenestration, no matter endoscopic or open, should always be accompanied by a cystoventricular shunt placement. However, Tamburrini *et al.*^[21] showed that it is not necessary to place second shunts in previously VP-shunted patients. Nevertheless, there might be an increased risk of VP shunt malfunction after the ECF procedure due to the increase in the protein level of CSF as a result of the release of cyst content into the ventricular cavity after cyst opening.

We preferred an endoscopic approach through the foramen of Magendie for performing the cyst fenestration in our

case. This approach has the advantage of a two-sided cyst opening without invading into the brain tissue. The alternative approach, i.e., through the third ventricle, would provide the opportunity to perform an endoscopic third ventriculostomy (ETV).^[12] Since the patient already had a VP shunt, we did not find it necessary to perform an additional ETV. Thus, we chose the closer and safer route to the cyst.

The recurrence rate of arachnoid cysts is relatively high, ranging from 31% to 60%.^[1,22] Due to the risk of cyst re-accumulation, routine follow-up and serial imaging are recommended in cases of fenestration or partial cyst removal even in the absence of clinical symptoms to avoid rare but life-threatening complications.^[22]

In conclusion, intraventricular cysts can be managed surgically or endoscopically. Endoscopic management is a safe and sound option with a good outcome and minimal complications.

Financial support and sponsorship

Nil.

Conflicts of interest

There are no conflicts of interest.

References

- Shiba M, Muramatsu M, Tanaka K, Hori K, Hatazaki S, Taki W. Acquired intraventricular arachnoid cyst of the third ventricle – Case report. *Neurol Med Chir (Tokyo)* 2010;50:509-12.
- Bonde V, Muzumdar D, Goel A. Fourth ventricle arachnoid cyst. *J Clin Neurosci* 2008;15:26-8.
- Westermaier T, Vince GH, Meinhardt M, Monoranu C, Roosen K, Matthies C. Arachnoid cysts of the fourth ventricle-short illustrated review. *Acta Neurochir (Wien)* 2010;152:119-24.
- Hasegawa M, Nouri M, Nagahisa S, Hayashi T, Adachi K, Hirose Y, *et al.* Neuroepithelial cyst of the fourth ventricle. *Childs Nerv Syst* 2015;31:155-9.
- Chernov MF, Kamikawa S, Yamane F, Hori T. Double-endoscopic approach for management of convexity arachnoid cyst: Case report. *Surg Neurol* 2004;61:483-6.
- Guzel A, Tatli M, Kilincer C, Yilmaz F. Posttraumatic intraventricular arachnoid cyst accompanied by pseudomeningoencephalocele in a child. *J Clin Neurosci* 2007;14:1210-3.
- Pradilla G, Jallo G. Arachnoid cysts: Case series and review of the literature. *Neurosurg Focus* 2007;22:E7.
- Kim MH. The role of endoscopic fenestration procedures for cerebral arachnoid cysts. *J Korean Med Sci* 1999;14:443-7.
- Schroeder HW, Gaab MR, Niendorf WR. Neuroendoscopic approach to arachnoid cysts. *J Neurosurg* 1996;85:293-8.
- Shin M, Nishihara T, Iai S, Eguchi T. Benign aqueductal cyst causing bilateral internuclear ophthalmoplegia after external ventricular drainage. Case report. *J Neurosurg* 2000;92:490-2.
- Yadav YR, Basoor A, Todorov M, Parihar V. Endoscopic management of large multicompartmental intraventricular arachnoid cyst extending from foramen magnum to foramen of Monro. *Neurol India* 2010;58:481-4.

12. Martinoni M, Toni F, Lefosse M, Pozzati E, Marliani AF, Mascari C. Endoscopic treatment of a fourth ventricle arachnoid cyst via the third ventricle: A case report. *Neurosurgery* 2014;10 Suppl 2:E374-7.
13. Paladino J, Rotim K, Heinrich Z. Neuroendoscopic fenestration of arachnoid cysts. *Minim Invasive Neurosurg* 1998;41:137-40.
14. Di Rocco C, Di Trapani G, Iannelli A. Arachnoid cyst of the fourth ventricle and “arrested” hydrocephalus. *Surg Neurol* 1979;12:467-71.
15. Korosue K, Tamaki N, Fujiwara K, Matsumoto S. Arachnoid cyst of the fourth ventricle manifesting normal pressure hydrocephalus. *Neurosurgery* 1983;12:108-10.
16. Makiuchi T, Kadota K, Asakura T, Uchimura K, Todoroki K, Oda H. Arachnoid cyst of the fourth ventricle. Case report. *Neurol Med Chir (Tokyo)* 1990;30:848-52.
17. Turgut M, Ozcan OE, Onol B. Case report and review of the literature: Arachnoid cyst of the fourth ventricle presenting as a syndrome of normal pressure hydrocephalus. *J Neurosurg Sci* 1992;36:55-7.
18. Bang JS, Oh C, Kim MS, Choe GY, Cho B, Hong S, *et al.* Two cases of intraventricular arachnoid cysts – Case report. *J Korean Neurosurg Soc* 2001;30:928-33.
19. Acar O, Kocaogullar Y, Güney O. Arachnoid cyst within the fourth ventricle: A case report. *Clin Neurol Neurosurg* 2003;105:93-4.
20. Baldawa S, Anvekar B, Valsangkar A, Valsangkar S. Malignant irreversible global cerebral edema as a complication of fourth ventricular arachnoid cyst. *Br J Neurosurg* 2014;28:799-801.
21. Tamburrini G, D’Angelo L, Paternoster G, Massimi L, Caldarelli M, Di Rocco C. Endoscopic management of intra and paraventricular CSF cysts. *Childs Nerv Syst* 2007;23:645-51.
22. Prezerakos GK, Kouyialis AT, Ziaka DS, Boviatsis EJ. Sudden death due to 4th ventricle arachnoid cyst. *Ir J Med Sci* 2011;180:769-70.