

## Choroidal Type of Vein of Galen Aneurysmal Malformation in Adult Patient with Unusual Presentation of Orthostatic Headache

### Abstract

Vein of Galen aneurysmal malformations (VGAMs) are rare vascular malformations occurring commonly in the pediatric age group. They comprise only 1% of all intracranial vascular malformations, but in pediatric population, they represent 30% of all intracranial vascular malformations. They are of two types-mural and choroidal. Choroidal type of VGAM is more primitive and most severe form of disease. It usually causes high cardiac output failure in newborn period because of multiple high flow fistulas. Adult presentation of choroidal type VGAM is very rare, and only few cases have been reported in literature so far. A 21-year-old female patient presented with an orthostatic headache. Neuroimaging showed the choroidal type of VGAM. Staged embolization was planned through transarterial route. Partial embolization was done in the first stage. Patient's symptoms were disappeared thereafter. As per our knowledge, orthostatic headache has not been described previously in literature. With a very few existing case reports of adult true vein of Galen malformations, we believe that this case can help in understanding the natural history of vein of Galen malformations and the pathophysiology of its development.

**Keywords:** Choroidal, orthostatic headache, Vein of Galen aneurysmal malformation

### Introduction

Vein of Galen aneurysmal malformations (VGAMs) are rare vascular malformations and comprise only 1% of all intracranial vascular malformations, but in pediatric population, they represent 30% of all intracranial vascular malformations.<sup>[1]</sup> They are of two types-mural and choroidal. Choroidal type of VGAM is more primitive and most severe form of disease. It usually causes high cardiac output failure in newborn period because of multiple high flow fistulas. Adult presentation of choroidal type VGAM is very rare, and only few cases have been reported in literature so far.<sup>[2-5]</sup> We describe here a case of choroidal type VGAM in 21-year-old female patient with an unusual presentation of an orthostatic headache.

### Case Report

A 22-year-old female patient presented with a complaint of headache whenever she sit or stand from lying down position. On neurological examination, the patient was conscious and oriented and her mental status examination was normal. Her visual

acuity and fundus examination were also normal. There was no significant past medical history. A computed tomography was performed and showed a cystic lesion in the quadrigeminal cistern with calcification of its wall [Figure 1a]. Contrast-enhanced magnetic resonance imaging showed a large contrast filled pouch in a quadrigeminal cistern with dilated straight sinus and both transverse sinuses along with multiple dilated vascular channels around it [Figure 1b]. Digital subtraction angiography (DSA) was done, which showed VGAM. Bilateral posterior choroidal arteries and left anterior choroidal artery were feeding arteries to dilated median prosencephalic vein, which was draining into falcine sinus [Figure 2a-c]. DSA was suggestive of choroidal type VGAM. Since the patient was symptomatic so endovascular embolization through the transarterial route was planned.

The procedure was performed under general anesthesia, through the right femoral artery. Both posterior choroidal arteries were embolized using N-butyl cyanoacrylate (NBCA) with lipiodol (1:1). Check DSA showed flow reduction from both posterior choroidal arteries [Figure 3a-c].

This is an open access journal, and articles are distributed under the terms of the Creative Commons Attribution-NonCommercial-ShareAlike 4.0 License, which allows others to remix, tweak, and build upon the work non-commercially, as long as appropriate credit is given and the new creations are licensed under the identical terms.

For reprints contact: reprints@medknow.com

**How to cite this article:** Pareek K, Shrivastava T, Sinha VD. Choroidal type of vein of galen aneurysmal malformation in adult patient with unusual presentation of orthostatic headache. *Asian J Neurosurg* 2018;13:418-20.

**Kapil Pareek,  
Trilochan  
Shrivastava,  
Virendra Deo Sinha**

*Department of Neurosurgery,  
SMS Medical College, Jaipur,  
Rajasthan, India*

### Address for correspondence:

*Dr. Kapil Pareek,  
Department of Neurosurgery,  
SMS Medical College,  
Jaipur - 302 004, Rajasthan,  
India.  
E-mail: dr.kapilpareek1@gmail.  
com*

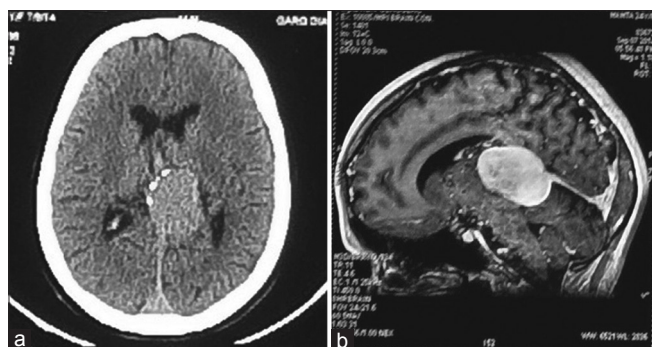
### Access this article online

**Website:** www.asianjns.org

**DOI:** 10.4103/1793-5482.228542

### Quick Response Code:





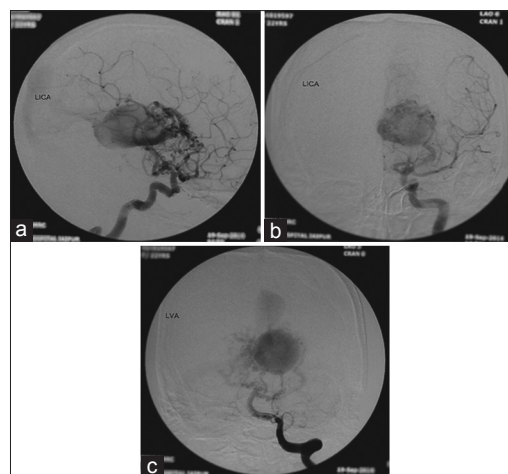
**Figure 1:** (a) Contrast-enhanced computed tomography shows a cystic lesion in the quadrigeminal cistern with calcification of its wall. (b) Contrast-enhanced magnetic resonance imaging shows a large contrast filled pouch in quadrigeminal cistern with dilated straight sinus and both transverse sinuses with multiple dilated vascular channels around it

Embolization of the left anterior choroidal artery feeder was planned in next setting. Postprocedure patient had relieved her symptoms dramatically. Thereafter, patient did not given the consent for next sitting of embolization, so the patient was discharged. In last 1 year follow-up, the patient is asymptomatic.

## Discussion

VGAMs are midline vascular malformation in the choroidal fissure. These vascular malformations believed to be an abnormal arteriovenous communications, supplied by choroidal arteries and draining to the dilated medial vein of prosencephalon, which is a precursor of vein of Galen. This median vein of prosencephalon is an embryonic drainage of choroid plexus. This embryonic nature of draining vein of VGAM was first described by Raybaud *et al.* in 1989.<sup>[6]</sup> Lasjaunias *et al.* further refined this disease. He has classified the VGAMs into true and false. The false VGAMs, so-called vein of Galen aneurysmal dilatation, it entails arteriovenous malformations that drain into a dilated vein of Galen but not a true fistula. The true VGAMs are fistulas between the choroidal arterial supply and the vein of Galen and they are further classified into mural or choroidal according to the anatomic pattern of the fistula.<sup>[7]</sup>

Choroidal VGAM is more primitive type, consists of multiple fistulae which communicates with the anterior aspect of the median vein of prosencephalon via an arterial network. Arterial feeders are anterior and posterior choroidal arteries and anterior cerebral arteries. Choroidal type of VGAM is most severe form of disease and it usually causes high output cardiac failure in newborn period because of multiple high flow fistulas. In the mural type of VGAM, there are single or multiple fistulas which are located at the inferolateral wall of dilated median vein of prosencephalon. Usual draining vessels are quadrigeminal or the posterior choroidal arteries or both. In contrast to choroidal VGAM, they have fewer fistulas and more restriction of outflow which causes more dilation of the median vein of prosencephalon but simultaneously



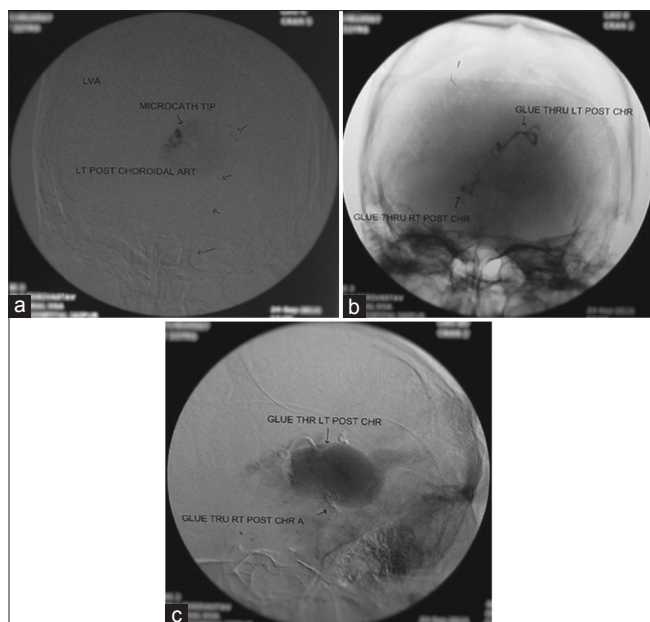
**Figure 2:** (a and b) Left internal carotid artery injection shows, anterior choroidal artery supplying to dilated median prosencephalic vein. (c) Left vertebral artery injection shows, bilateral posterior choroidal arteries supplying to dilated median prosencephalic vein

protects the heart from high output cardiac failure. Therefore, mural type of VGAM usually manifests later in infancy as hydrocephalus, macrocrania, supratentorial, and infratentorial venous congestion leading to white matter ischemia and cerebral atrophy, and eventually leading to mental retardation and seizures.<sup>[7]</sup> Although it may manifests as a mild cardiac failure or as asymptomatic cardiomegaly.

Presentations vary according to the hemodynamics of the fistula; therefore, it either manifests as early as the perinatal or early neonatal period in the form of congestive heart failure due to high-velocity shunt and causing high-output cardiac failure or it manifests later during infancy with hydrocephalus and macrocrania caused by the growing Galenic pouch obstructing the normal cerebrospinal fluid pathways and partly due to venous hypertension leading to altered cerebrospinal fluid flow dynamics.<sup>[8-10]</sup>

Adult presentation of true VGAM is very rare. Very few case reports existing about this condition in adults.<sup>[2-5]</sup> Peculiar of this case is that the patient was asymptomatic throughout her life and now she presented with an orthostatic headache. Unlike the usual cases VGAM, persistent venous hypertension leads to cerebral atrophy, eventually leading to seizure and mental retardation, the patient had normal life until this age which raised the hypothesis of delayed increased venous pressure in this patient. The cause of an orthostatic headache was probably venous hypotension in the background of persistently elevated venous pressure or because of obstruction of CSF flow in recumbent position by dilated Galenic pouch.

As the case is true VGAM, the pathology must have started early in the neonatal period but its presentation was delayed probably because of the slow rise of venous hypertension and delayed enlargement of Galenic pouch. Chronicity of lesion is supported by the presence of calcification of



**Figure 3:** (a) Microcatheterization through the left posterior choroidal artery. (b and c) Glue cast after embolization through bilateral posterior choroidal arteries

wall of malformation and presence of highly dilated and tortuous cerebral veins, indicating a long-standing venous hypertension.

The treatment of VGAM is primarily endovascular. The aim is to embolize the fistulous point by embolic material either with a detachable coil or with NBCA or both, with transarterial or transvenous routes or a combination of both.<sup>[1,7,8,10]</sup> The final goal of treatment of VGAM must be complete obliteration of lesion without neurological deficit. However, complete obliteration of VGAM fistulas is not necessary to achieve hydrovenous equilibrium. As in this patient, even after partial obliteration of feeding vessels has decreased the venous hypertension which was reflected by symptomatic improvement of the patient.

### Conclusion

This is the first case report of VGAM in an adult who presented with a history of an orthostatic headache. With a very few existing case reports of adult true vein of

Galen malformations, we believe that this case can help in understanding the natural history of vein of Galen malformations and the pathophysiology of its development.

### Financial support and sponsorship

Nil.

### Conflicts of interest

There are no conflicts of interest.

### References

1. Heuer GG, Gabel B, Beslow LA, Stiefel MF, Schwartz ES, Storm PB, *et al.* Diagnosis and treatment of vein of Galen aneurysmal malformations. *Childs Nerv Syst* 2010;26:879-87.
2. Ribeiro VT, Botelho LF, Lopes AC, Ribeiro P, Xavier JA, Teixeira JF, *et al.* Choroidal type aneurysmal malformation of the vein of Galen associated with Dandy-Walker malformation in an adult. *Acta Med Port* 2003;16:217-20.
3. Xu DS, Usman AA, Hurley MC, Eddleman CS, Bendok BR. Adult presentation of a familial-associated vein of Galen aneurysmal malformation: Case report. *Neurosurgery* 2010;67:E1845-51.
4. Marques RM, Lobão CA, Sasaki VS, Aguiar LR. Vein of Galen aneurysm in an adult: Case report. *Arq Neuropsiquiatr* 2006;64:862-4.
5. Muquit S, Shah M, Bassi S. Vein of Galen malformation presenting in adulthood. *Br J Neurosurg* 2008;22:692-4.
6. Raybaud CA, Strother CM, Hald JK. Aneurysms of the vein of Galen: Embryonic considerations and anatomical features relating to the pathogenesis of the malformation. *Neuroradiology* 1989;31:109-28.
7. Lasjaunias PL, Chng SM, Sachet M, Alvarez H, Rodesch G, Garcia-Monaco R. The management of vein of Galen aneurysmal malformations. *Neurosurgery* 2006;59 5 Suppl 3:S184-94.
8. Hassan T, Nassar M, Elghandour M. Vein of Galen aneurysms: Presentation and endovascular management. *Pediatr Neurosurg* 2010;46:427-34.
9. Hassan T, Timofeev EV, Ezura M, Saito T, Takahashi A, Takayama K, *et al.* Hemodynamic analysis of an adult vein of Galen aneurysm malformation by use of 3D image-based computational fluid dynamics. *AJNR Am J Neuroradiol* 2003;24:1075-82.
10. Pearl M, Gomez J, Gregg L, Gailloud P. Endovascular management of vein of Galen aneurysmal malformations. Influence of the normal venous drainage on the choice of a treatment strategy. *Childs Nerv Syst* 2010;26:1367-79.