

Meningioma in Fourth Ventricle of Brain: A Case Report and Literature Review

Abstract

Meningiomas are benign tumors origin from central nervous system. They usually involve cephalic, paravertebral soft tissues, skin and in rare cases in the ear, temporal bone, mandible, foot, lung, and mediastinum. In this case, we report an unusual case of meningioma which placed in the fourth ventricle. A 14-year-old man with seizure and headache referred to our ward. The magnetic resonance imaging reported bilateral acoustic neuroma and fourth ventricle meningioma. The patient was scheduled for total tumor resection and the histopathology revealed psammomatous type of meningioma. The patient discharged with good general status.

Keywords: *Acoustic Neuroma, fourth ventricle, meningioma, neurofibromatosis type 2, psammoma body*

Introduction

Meningiomas are common tumors of the central nervous system (CNS) which origin from arachnoid cells and constitute 15–20% of all intracranial tumors.^[1] Meningiomas are benign in 95% of cases and the prevalence of them estimated to be 97.5/100,000 in the USA. Benign meningiomas classified based on their histopathological pattern to fibrous (fibroblastic), transitional (mixed), angiomatous, microcystic, secretory, lymphoplasmacyte-rich, metaplastic subtypes and psammomatous.^[2] They usually involving cephalic, paravertebral soft tissues, skin and in some are cases in the ear, temporal bone, mandible, foot, lung, and mediastinum.^[3] We report a rare case of psammomatous meningioma placed in the fourth ventricle of the brain that has not been previously reported.

Case Report

A 14-year-old man referred to neurosurgery ward of Imam Reza Hospital with chief complaint of headache and seizure and diagnosis of brain tumor. The father of patient explained that the seizures of his son started from childhood and were controlled with phenobarbital, but it exacerbated recently. In paraclinic investigation, the patient had brain magnetic resonance imaging (MRI) with and without contrast.

This is an open access journal, and articles are distributed under the terms of the Creative Commons Attribution-NonCommercial-ShareAlike 4.0 License, which allows others to remix, tweak, and build upon the work non-commercially, as long as appropriate credit is given and the new creations are licensed under the identical terms.

For reprints contact: reprints@medknow.com

MRI reported bilateral acoustic neuroma in cerebellopontine angle [Figure 1], porecephalic cyst at the right parietal with the right lateral ventricle enlargement, and intraventricular located soft tissue mass at the fourth ventricle which extended toward into the left Luschka foramen and downward into cistern magna [Figure 2]. Sagittal and axial T1-weighted image [Figure 3] and MRI with contrast confirmed these findings [Figure 4]. In further investigations, there were some brown patches around genital area and breasts that they seemed to be café au lait spots [Figure 5a and b]. The diagnosis was neurofibromatosis type 2 (NF 2) because of café au lait spots, headache and bilateral acoustic neuroma (schwannoma). We request for MRI with or without contrast for patient's brother that they were normal. The patient was scheduled for total resection of tumors and meningioma had removed from fourth ventricle [Figure 6]. Our consultant histopathologist reported psammomatous type of meningioma [Figure 7]. The postoperative MRI requested for the patient [Figure 8], there was not any pathological view in brain MRI, and patient discharged with good general status.

Discussion

NF 2 is an autosomal dominant disorder that classically known with bilateral

How to cite this article: Salehpour F, Aghazadeh J, Bazzazi AM, Mirzaei F, Eftekhari Saadat AT, Alavi SA. Meningioma in fourth ventricle of brain: A case report and literature review. *Asian J Neurosurg* 2018;13:428-30.

**Firooz Salehpour,
Javad Aghazadeh,
Amir Mohammad
Bazzazi¹,
Farhad Mirzaei,
Amir Taha Eftekhari
Saadat²,
Seyed Ahmad
Naseri Alavi**

*Department of Neurosurgery,
Faculty of Medicine, Tabriz
University of Medical Sciences,
¹Department of Neurosurgery,
Tabriz Alinasab Hospital,
²Department of Histopathology,
Emam Reza Hospital, Tabriz
University of Medical Sciences,
Tabriz, Iran*

Address for correspondence:
*Dr. Seyed Ahmad Naseri Alavi,
Department of Neurosurgery,
Faculty of Medicine, Tabriz
University of Medical Sciences,
Tabriz, Iran.
E-mail: dr.arsalan2010@gmail.
com*

Access this article online

Website: www.asianjns.org

DOI: 10.4103/1793-5482.228551

Quick Response Code:



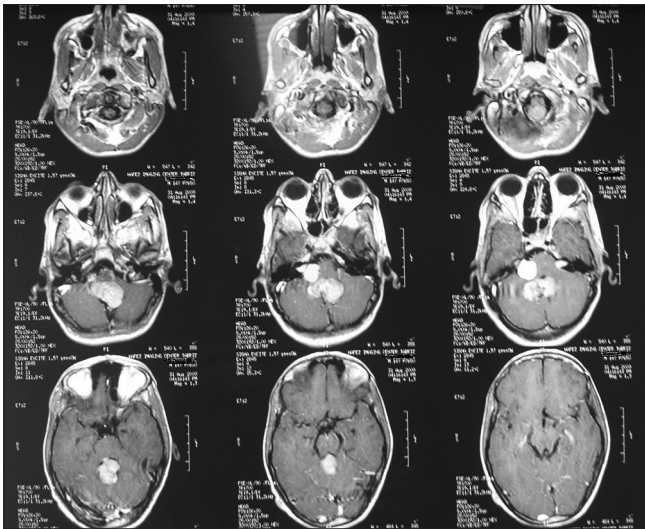


Figure 1: Axial magnetic resonance imaging with contrast: Bilateral acoustic neuroma, and meningioma in 4th ventricle

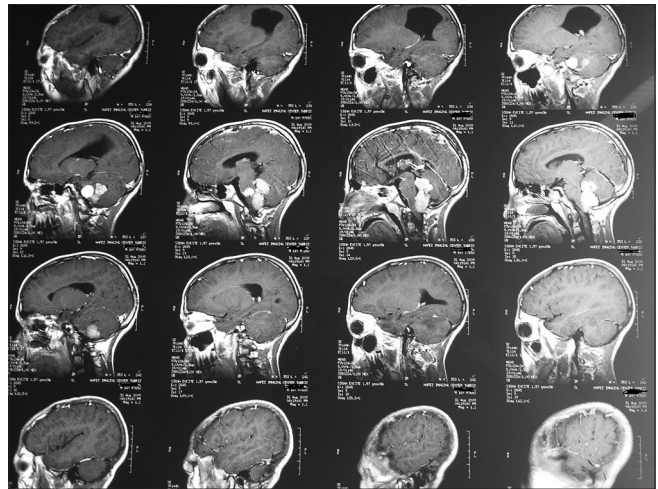


Figure 2: Sagittal magnetic resonance imaging with contrast: Meningioma in 4th ventricle

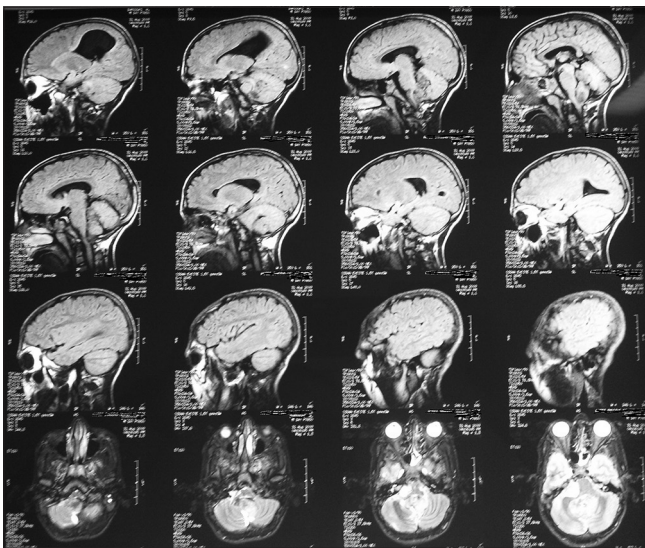


Figure 3: Sagittal and axial T1-weighted magnetic resonance imaging: Tumor in 4th ventricle

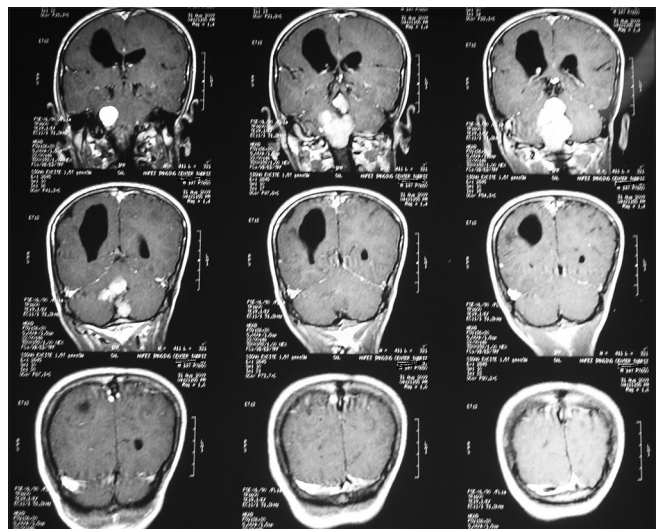


Figure 4: Coronal magnetic resonance imaging with contrast: Bilateral acoustic neuroma, and meningioma

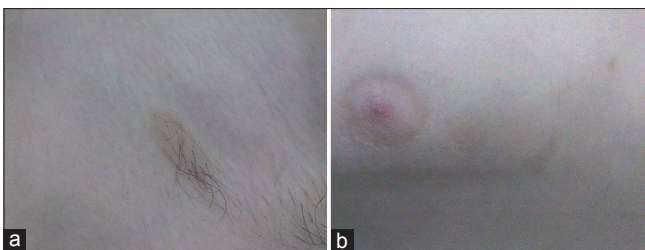


Figure 5: (a) Cafe au lait spot (b) Cafe au lait spots around breast

acoustic neurofibromatosis, vestibular schwannomas, spinal and cranial meningiomas, or other tumors of CNS.^[4] More than half of meningiomas are related with NF2.^[5] Meningiomas are benign intracranial tumors that consist 30% of primary tumors of CNS in adults; however, they

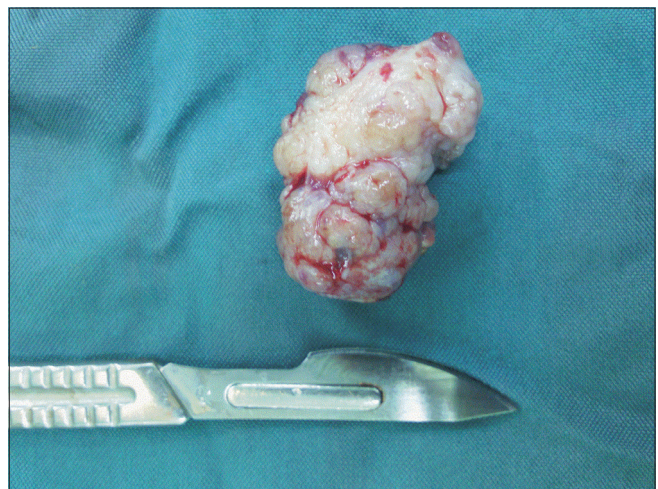


Figure 6: Tumor size

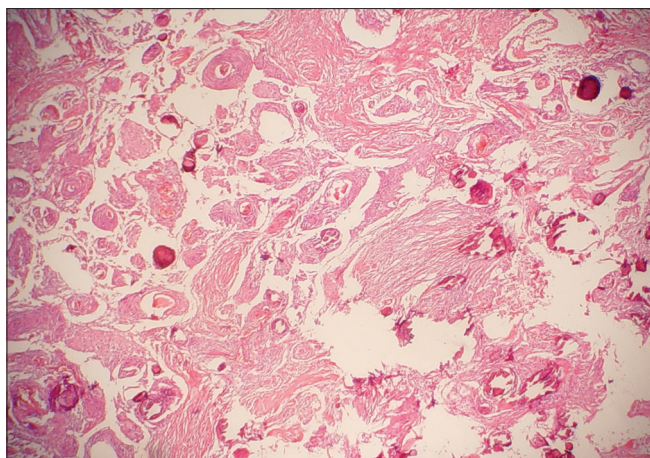


Figure 7: Histopathology of tumor; psammoma type of meningioma

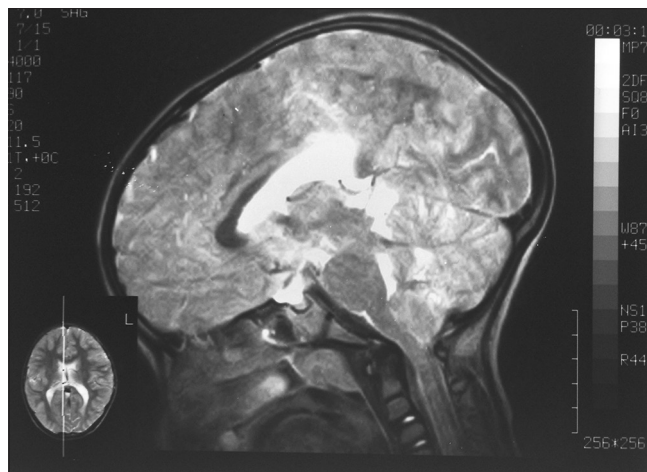


Figure 8: Postoperative magnetic resonance imaging

are rare in youth.^[6,7] Meningiomas divided into three groups based on their increased degree of anaplasia: Typical (WHO Grade I), atypical (WHO Grade II), and anaplastic (WHO Grade III).^[8] Some histological types are belonging to Grade I that one of them is psammomatous type.^[9] Psammoma bodies are composed of calcium that is common in meningiomas and help to distinguish meningiomas from other intracranial tumors.^[10] In this case report, we present a 14-year-old man with meningioma in the fourth ventricle that never had been reported before. The patient referred to neurosurgery ward of Imam Reza Hospital of Tabriz University of Medical Sciences with a diagnosis of bilateral acoustic neuroma and meningioma. Bilateral acoustic neuromas are usually presented in NF2. The café au lait spots confirmed this diagnosis.^[11] The patient had uncontrolled seizures and headache at admission that can be because of his intracranial tumors and NF2.^[12] Meningiomas are usually involving cephalic, paravertebral soft tissues, skin and in rare cases in the ear, temporal bone, mandible, foot, lung, and mediastinum.^[3] However, in this case, we had a psammomatous type of meningioma that is benign type in a rare place. Because of a tumor in the fourth ventricle is unclear to us but perhaps susceptibility to tumors in NF patients is causing the issue.

Financial support and sponsorship

Nil.

Conflicts of interest

There are no conflicts of interest.

References

1. Sanei MH, Berjis N, Mahzouni P, Naimi A. A case of neck ectopic meningioma. *Neuropathology* 2008;28:157-9.
2. Perry LD, Scheithauer BW, Budka H, von Diemling A, Meningiomas Louis DN, Oghaki H, *et al.* World Health Organization Classification of Tumors of the Central Nervous System. 4th ed. Lyon: IARC Press; 2007. p. 164-72.
3. Wiemels J, Wrensch M, Claus EB. Epidemiology and etiology of meningioma. *J Neurooncol* 2010;99:307-14.
4. Ruggieri M, Praticò AD, Evans DG. Diagnosis, management, and new therapeutic options in childhood neurofibromatosis type 2 and related forms. *Semin Pediatr Neurol* 2015;22:240-58.
5. Riemenschneider MJ, Perry A, Reifenberger G. Histological classification and molecular genetics of meningiomas. *Lancet Neurol* 2006;5:1045-54.
6. Choy W, Kim W, Nagasawa D, Stramotas S, Yew A, Gopen Q, *et al.* The molecular genetics and tumor pathogenesis of meningiomas and the future directions of meningioma treatments. *Neurosurg Focus* 2011;30:E6.
7. Kotecha RS, Pascoe EM, Rushing EJ, Rorke-Adams LB, Zwerdling T, Gao X, *et al.* Meningiomas in children and adolescents: A meta-analysis of individual patient data. *Lancet Oncol* 2011;12:1229-39.
8. Louis DN, Ohgaki H, Wiestler OD, Cavenee WK, Burger PC, Jouvet A, *et al.* The 2007 WHO classification of tumours of the central nervous system. *Acta Neuropathol* 2007;114:97-109.
9. Calligaris D, Feldman DR, Norton I, Brastianos PK, Dunn IF, Santagata S, *et al.* Molecular typing of meningiomas by desorption electrospray ionization mass spectrometry imaging for surgical decision-making. *Int J Mass Spectrom* 2015;377:690-8.
10. Moradi A, Semnani V, Djam H, Tajodini A, Zali AR, Ghaemi K, *et al.* Pathodiagnostic parameters for meningioma grading. *J Clin Neurosci* 2008;15:1370-5.
11. Evans DG. Neurofibromatosis type 2 (NF2): A clinical and molecular review. *Orphanet J Rare Dis* 2009;4:16.
12. Mezue WC, Ndubuisi CA, Chikani MC, Onyia E, Iroegbu L, Ohaegbulam SC. Epilepsy in primary intracranial tumors in a neurosurgical hospital in Enugu, South-East Nigeria. *Niger J Clin Pract* 2015;18:681-6.