

Penetrating Injury to Cauda Equina from a Missile Fragment, Completely Recovered after Delayed Surgical Removal of Ballistic Fragment

Abstract

Penetrating injuries to cauda equina due to missile fragment are rare. The mechanism of injury may be more complex due to thermal effect of missile fragment, apart from mechanisms described in penetrating gunshot injuries or stab injuries. We report a case of a 42-year-old male with penetrating missile injury to cauda equina, improved completely after delayed surgical exploration and removal of ballistic fragment. Furthermore, his bowel and bladder dysfunction improved completely within 1 week of neurosurgical exploration. Although early neurosurgical intervention is recommended for penetrating injuries of the cauda equina, delayed intervention may also be beneficial in selected patients. Computed tomography (CT) scan and CT myelogram are extremely useful in surgical planning when magnetic resonance imaging contraindicated due to impregnated metal fragments.

Keywords: *Cauda equina injury, missile injury, magnetic resonance imaging, spine surgery*

**Kamble
Jayaprakash
Harsha,
Anu Thomas¹**

Departments of Neuroimaging and Endovascular Neurosurgery and ¹Neurosurgery, Brain and Spine Centre, Indo-American Hospital, Chemmanakary, Vaikom, Kerala, India

Introduction

Penetrating injuries to cauda equina are commonly encountered due to gunshot wounds and bullet injuries. The missile fragment injuries to cauda equina are rare. The mechanism of injury may be more complex due to thermal effect of missile fragment, apart from mechanisms described in penetrating gunshot injuries or stab injuries. The neurological damage may be complete or incomplete. Both types of injuries can show improvement with surgical treatment in motor power of the lower limbs. However, bowel and bladder dysfunction at the time of presentation usually respond poorly to any type of treatment. Early neurosurgical intervention is indicated for penetrating cauda equina injuries.^[1] Direct compression of cauda equina by migrated bullet in dural sac is described.^[2] We describe a case in which no direct compression of cauda equina nerve roots was seen. The missile fragment was compressing only the right L5 nerve root in L5-S1 neural foramina. However, he recovered completely after surgical removal of ballistic fragment.

Case Report

A 42-year-old male, Indian National, Migrated Resident of Yemen, gave a history

of missile blast near his residence. He gave a history of ballistic fragment penetration in his left side of lower back and another small fragment penetrated into the right gluteal region. He was taken to a local hospital where he was managed conservatively. He developed bilateral lower limb weakness (R > L) and numbness and was unable to walk since then. He presented to our hospital 3 months after the blast. At the time of presentation, he had persistent severe right lower limb weakness, urinary retention, and constipation. His numbness had improved during the 3 months. His local examination revealed entry site wound in the left lower paravertebral region with granulation tissue. Mild blackish discoloration of the skin was noted around the wound site. Wound was almost healed at the time of presentation.

Neurological examination revealed straight leg raising test positive on the right side at 60°. Right lower limb weakness noted at hip flexion and abduction, knee flexion and extension, ankle dorsiflexion, and plantar flexion, with relative preservation of hip extension. Power in extensor hallucis longus was 0/5. Sensory examination revealed hypesthesia for all modalities in the right L5, S1, S2, S3 dermatomes, with right-sided perianal sensory loss. Bilateral plantar response was flexor. He had right-sided

Address for correspondence:

Dr. Kamble Jayaprakash Harsha, Department of Neuroimaging and Endovascular Neurosurgery, Brain and Spine Centre, Indo-American Hospital, Chemmanakary, Vaikom - 686 143, Kerala, India. E-mail: kjharsha@gmail.com

Access this article online

Website: www.asianjns.org

DOI: 10.4103/1793-5482.228565

Quick Response Code:



How to cite this article: Harsha KJ, Thomas A. Penetrating injury to cauda equina from a missile fragment, completely recovered after delayed surgical removal of ballistic fragment. *Asian J Neurosurg* 2018;13:433-5.

This is an open access journal, and articles are distributed under the terms of the Creative Commons Attribution-NonCommercial-ShareAlike 4.0 License, which allows others to remix, tweak, and build upon the work non-commercially, as long as appropriate credit is given and the new creations are licensed under the identical terms.

For reprints contact: reprints@medknow.com

high-stepping gait. Ankle jerk was absent on the right side. His nerve conduction study revealed asymmetrical predominantly axonal motor neuropathy. Absent H-reflex was suggestive of bilateral S1 radiculopathy.

His computed tomography (CT) scan of the lumbosacral spine revealed wound entry site in the left paravertebral region at the level of L4 lower vertebral endplate. The projectile track was noted in the L4-5 interspinous space. A metallic fragment was partially impregnated in right L5 transverse process [Figure 1], part of which was projecting into the right L5-S1 neural foramina. The projectile was indenting exiting right L5 nerve root [Figure 1f]. Bilateral L5 pedicles were fractured perpendicular to the projective track [Figure 1c and e]. There were a few small metallic fragments scattered within the right epidural space at L5 level, few in paravertebral soft tissues [Figure 1d-f]. A small fragment also noted at the right gluteal region [Figure 1a]. CT myelogram revealed abrupt termination of contrast column in thecal sac at the level of L5 vertebral body [Figure 2]. The thecal sac was displaced to the left side of spinal canal [Figure 2c].

He underwent surgical exploration for removal of foreign body. A 15 mm × 5 mm metallic piece was found intraoperatively in the extraforaminal space of L5-S1 foramen, which was removed. The metallic fragment was compressing exiting L5 nerve root. He also underwent right L5 laminectomy and spinal decompression. The nerve root was partially crushed and healed, which was sealing possible dural tear. There was no visible cerebrospinal fluid leak. Hence, intradural exploration avoided. Postoperatively, his power improved dramatically within 1 week. He was able to walk without support. His constipation disappeared within 1 week with restoration of his normal bowel habits.

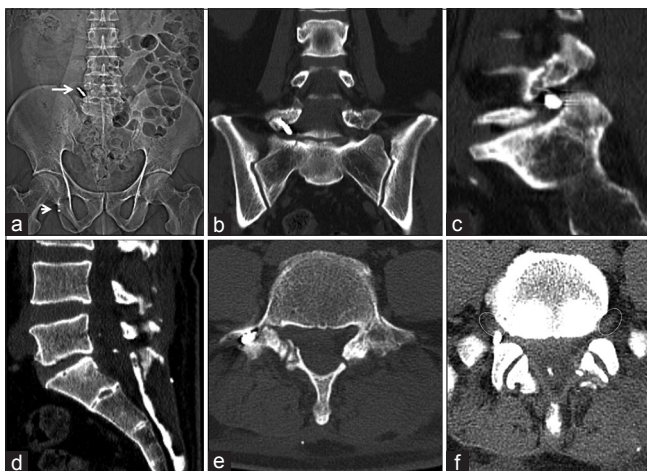


Figure 1: (a) Computed tomography topogram of the pelvis showing missile fragment in the right paravertebral region (long arrow), another small metal fragment overlapping ischium. (b and c) Coronal and sagittal reformatted computed tomography images showing missile fragment impregnated in the right L5 transverse process, projecting into L5-S1 neural foramina. (d) Sagittal reformatted image showing metallic fragment in thecal sac. (e) Fracture of bilateral L5 laminae. (f) Metal fragment compressing exiting right L5 nerve root. Corresponding normal left L5 nerve root shown in circle

His bladder sensations returned; hence, Foley’s catheter was removed. He was discharged with advice to continue physiotherapy.

Discussion

There are four types of blast-related injuries grouped based on the mechanism of injury – primary, secondary, tertiary, and quaternary (or miscellaneous).^[3] The blast-related primary injuries are due to blast wave affecting the body’s surface and tissues, which in turn leading to anatomical and physiological changes in the tissues, primarily in gas-containing structures. The blast-related secondary injuries are due to flying debris (e.g., bomb fragment, wood, glass, etc.), causing penetrating, or less frequently blunt trauma. The blast-related tertiary injuries are due to blast wind force throwing persons’ body away from blast site. The blast-related quaternary injuries are all explosion-related injuries, illnesses, or diseases not due to primary, secondary, or tertiary mechanisms. The injury in our case is secondary related to penetrating projectile of bomb fragment. The entry site was on the left paravertebral region, at the level of L4 vertebral transverse process. Entry site wound at the skin and subcutaneous tissue was larger (3 cm × 3 cm) than the ballistic fragment (1.5 cm × 0.5 cm); this may be due to thermal effect. The projectile had taken rightward, downward, and anterior course as evidenced by wound track in CT scan. The track was adjacent to laminae, in-between spinous process of L4 and L5. After hitting the right L5 transverse process, there is possibility of deflection of ballistic fragment in such a way that a part of the fragment was impregnated within the right L5 transverse process while a part was projecting into L5-S1 neural foramina causing compression of exiting right L5 nerve root [Figure 3].^[4]

The fractures of bilateral L5 laminae were perpendicularly oriented to trajectory path of missile fragment; the possible pathomechanism of these fractures remains elusive.

The L5 nerve root compression was relieved after removal of fragment. However, compression of the right L5 nerve root by ballistic fragment alone could not explain the severe presurgical right lower limb (thigh, knee, and

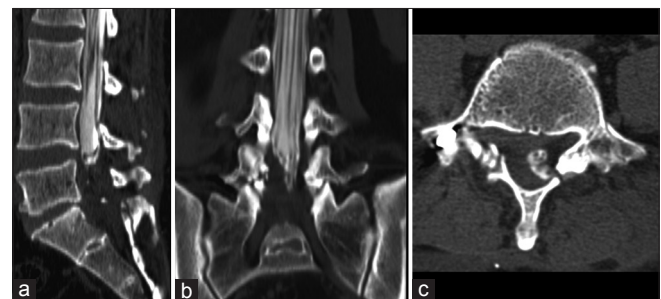

Figure 2: (a-c) Sagittal, coronal, and axial computed tomography myelogram images showing abrupt cutoff of thecal sac at L5 vertebral level, leftward displacement of thecal sac

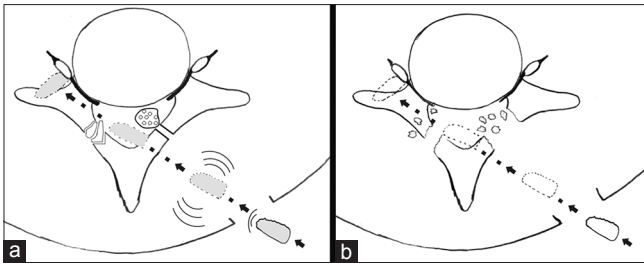


Figure 3: (a) Hypothesized wound profile of the ballistic fragment, location and orientation of fractures, thecal sac, the final position of missile fragment. (b) Hypothesized fracture type and location of fracture fragments if the missile fragment would have hit bones directly, to reach its current final position

ankle) weakness, as well as involvement of bowel and bladder. We postulate that the heat associated with the missile might have damaged right spinal canal epidural fat, dura, and possibly underlying lumbosacral nerves. The intraoperative findings substantiate this hypothesis. The partial laminectomy was performed along with the removal of partially coagulated epidural fat. This act during operation might have significantly relieved compression pressure on multiple lumbosacral nerve roots. Hence, the patient improved dramatically within the first few days of the operation. The nerve roots were neither severe nor fragmented but were only compressed by the coagulated epidural fat. Improvement of bowel and bladder symptoms within 1 week also supports this hypothesis. This observation is against the previous finding in a case series by Robertson and Simpsons,^[1] in which bladder or bowel dysfunction was associated with poor prognosis regardless of the type of treatment.

Magnetic resonance imaging (MRI) would have given more information about soft-tissue damage. However, the

composition of metallic ballistic fragment was unknown. If the ballistic fragment was not MR compatible, then there was possibility of fragment movement or heating of fragment aggravating the existing neurological damage. Hence, CT myelogram was performed avoiding MRI. In a case report by Morenski *et al.*,^[5] CT myelogram was superior to MR myelogram for demonstration of nerve root injuries in blast injury.

Although early neurosurgical intervention is the recommendation for penetrating blast injuries of the cauda equina, delayed intervention may also be beneficial in selected patients. CT scan and CT myelogram are extremely helpful in planning of surgery.

Financial support and sponsorship

Nil.

Conflicts of interest

There are no conflicts of interest.

References

1. Robertson DP, Simpson RK. Penetrating injuries restricted to the cauda equina: A retrospective review. *Neurosurgery* 1992;31:265-9.
2. Jun W, Yi-Jun K, Xiang-Sheng Z, Jing W. Cauda equina syndrome caused by a migrated bullet in dural sac. *Turk Neurosurg* 2010;20:566-9.
3. Phillips YY. Primary blast injuries. *Ann Emerg Med* 1986;15:1446-50.
4. Lee CH. Mechanisms of injury and treatment principles of gunshot wounds. *J Korean Med Assoc* 2012;55:463-72.
5. Morenski JD, Avellino AM, Elliott JP, Winn HR. Bilateral multiple cervical root avulsions without skeletal or ligamentous damage resulting from blast injury: Case report. *Neurosurgery* 2002;50:1368-70.