

## Aspergilloma Mimicking Olfactory Groove Meningioma

### Abstract

Central nervous system aspergillosis is rare with reported mortality rate of 13–50% involving foci in paranasal sinuses and even higher mortality rates (80–100%) in patients of immune-compromised status. Modern day imaging offers an opportunity for early diagnosis, but findings are minimal. A typical finding is that of a space occupying mass lesion with iso-hypointense signal on T1-weighted sequences and extreme hypointense appearance on T2-weighted. This results from the concentration of ferromagnetic substances (iron/zinc/magnesium/manganese) within the lesion. Gadolinium enhancement pattern varies from homogeneous to peripheral ring enhancement. The immune-competent hosts present with homogeneous enhancement while those with immune compromise bear more variable radiological appearance. Due to such radiological appearance, meningioma or tuberculoma is considered in differential earlier than fungal granuloma, if not for the hypointense appearance on T2-weighted sequences which strongly points to fungal granuloma. Through this case report, we attempt to highlight the unusual radiological presentation of the entity.

**Keywords:** *Aspergilloma, immune-competent, magnetic resonance imaging, outcome*

### Introduction

Aspergillosis is an uncommon intracranial infection associated with immune-compromised states such as uncontrolled diabetes mellitus, AIDS, cancer, organ transplant, or immunosuppressive drugs.<sup>[1-3]</sup> Clinical presentation varies from that of meningoencephalitis, infarct, mycotic aneurysms to aspergilloma (tumor-like).<sup>[4]</sup> Cerebral aspergilloma bears poor outcome with reported mortality rates of 85–100% despite antifungal treatment, secondary to angioinvasive nature.<sup>[3,5]</sup> Surgical management of fungal infection of central nervous system (CNS) is always a challenge as the diagnosis is often delayed but timely intervention may improve outcome. The immune-competent host presents a diagnostic dilemma as the possibility of fungal infection is considered less likely, and resulting delay in the management begets a poor outcome.<sup>[6]</sup> Through this case report, an attempt is made to highlight the nuances of clinic-radiological presentation in an immune-competent patient with aspergilloma masquerading as olfactory groove meningioma.

This is an open access journal, and articles are distributed under the terms of the Creative Commons Attribution-NonCommercial-ShareAlike 4.0 License, which allows others to remix, tweak, and build upon the work non-commercially, as long as appropriate credit is given and the new creations are licensed under the identical terms.

For reprints contact: [reprints@medknow.com](mailto:reprints@medknow.com)

### Case Report

A 26-year-old right-handed shopkeeper presented with a headache for 2.5 years. The onset of nasal stuffiness for 1 month duration was associated with anosmia. The patient underwent endoscopic nasal surgery at a different institution 1 year back with incomplete relief of which no records were available. Magnetic resonance imaging (MRI) with gadolinium contrast administration revealed T1 and T2 isointense extra-axial mass in the right basifrontal region with homogeneous enhancement and perilesional edema suggestive of meningioma [Figure 1b-e].

The patient was started on steroids in view of the persisting headache of raised intracranial pressure [Figure 1a]. On day 2 of starting steroid, he developed partial seizure involving left upper and lower limb with postictal hemiparesis. The episode was followed by another generalized tonic-clonic seizure and patient was shifted to an Intensive Care Unit care setting. Contrast-enhanced computed tomography (CT) head revealed parenchymal hematoma involving right caudate lobe and extending in continuity with the lesion into the lateral ventricle [Figure 1f]. The CT-angio study

**How to cite this article:** Sharma P, Bhaisora KS, Pandey S, Srivastava AK, Pani KC, Sardhara J, *et al.* Aspergilloma mimicking olfactory groove meningioma. *Asian J Neurosurg* 2018;13:436-9.

**Pradeep Sharma,  
Kamlesh S.  
Bhaisora,  
Satyadeo Pandey,  
Arun Kumar  
Srivastava,  
Krushna C. Pani<sup>1</sup>,  
Jayesh Sardhara,  
Kuntal K. Das,  
Anant Mehrotra,  
Rabi Narayan Sahu,  
Awadhesh K.  
Jaiswal,  
Sanjay Behari**

*Departments of Neurosurgery  
and <sup>1</sup>Pathology, SGPGIMS,  
Lucknow, Uttar Pradesh, India*

#### Address for correspondence:

*Dr. Arun Kumar Srivastava,  
Department of Neurosurgery,  
SGPGIMS, Lucknow - 226 014,  
Uttar Pradesh, India.  
E-mail: [doctorarunsrivastava@gmail.com](mailto:doctorarunsrivastava@gmail.com)*

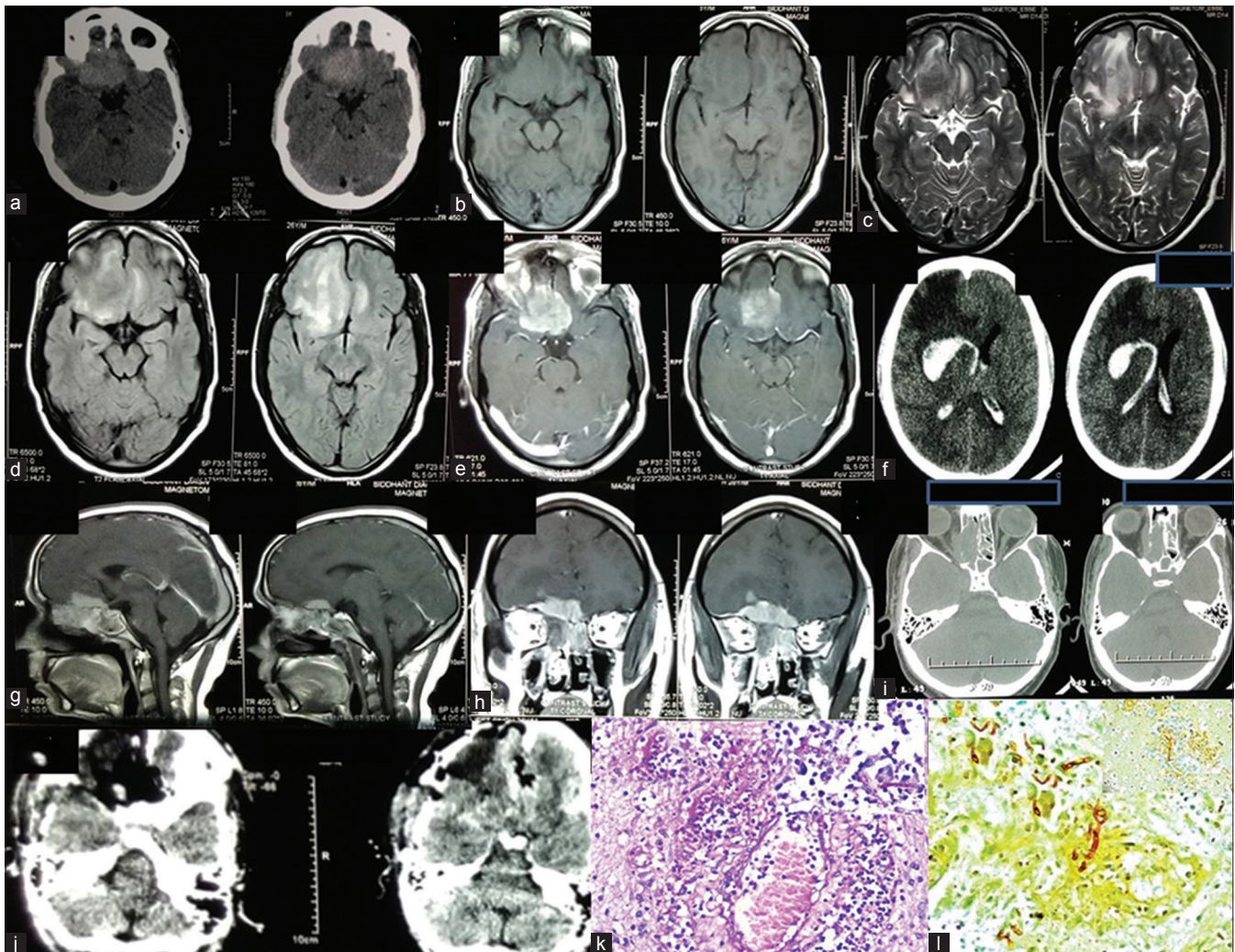
#### Access this article online

**Website:** [www.asianjns.org](http://www.asianjns.org)

**DOI:** 10.4103/1793-5482.228571

#### Quick Response Code:





**Figure 1:** (a) Contrast-enhanced computed tomography - solitary heterogeneously enhancing mass in right basifrontal region. (b) Magnetic resonance T1 sequences-isointense lesion. (c and d) T2-weighted image and T2 fluid attenuated inversion recovery - heterogenous mass with peri-lesional oedema. (e) Heterogenous moderate enhancement. (f) Noncontrast computed tomography (patient deterioration) - haemorrhage within lesion extending into right lateral ventricle. (g) Contrast MRI sequences: lesion is seen with both intra nasal and intra cranial extension. (h and i) Lesion extension is seen into the ethmoid sinus with associated bony erosion. The bony erosion is seen better on CT study while the soft tissue details are better seen on contrast MR sequences with intra cranial lesion extending into the left ethmoid sinus. (j) Postoperative computed tomography: No residual enhancing lesion. (k) Septate fungal hyphae with acute angle branching on inflammatory and necrotic background. Angioinvasion is noted (Periodic acid-Schiff,  $\times 40$ ). (l) Fungal profiles better appreciated in silver stain (Methenamine Silver,  $\times 40$ )

did not reveal any underlying aneurysm. The patient was taken up for urgent decompression with evacuation of hematoma and mass excision. Intraoperatively, cheesy yellowish white avascular partially suckable mass with pus pockets was seen, involving interoptic recess and right carotico-optic recess with sellar, suprasellar, and retro sellar extension and liquefactive necrosis of adjoining brain parenchyma. The defect in anterior cranial fossa [Figure 1g-i] near cribriform plate was secured with pedicled galeal flap.

The cultures proved negative for aerobic/anaerobic organisms. Potassium hydroxide wet mount was populated with hyaline, septate acute branching fungal hyphae suggestive of hyalohyphomycetes and culture later revealed *Aspergillus* species after 72 h of incubation

[Figure 1k and l]. The nail scraping of the patient also revealed plenty of thin septate branching fungal hyphae. No evidence of immune-suppression detected during hospital stay (serology negative for HIV and hepatitis B/C and no pancytopenia). Anti-fungal therapy was administered as voriconazole (400 mg BD on day 1, followed by 200 mg BD). Patient at the time of discharge [Figure 1j] on postoperative day 19 was conscious, following commands with left hemiparesis. He is in regular follow-up and is undergoing rehabilitation.

### Discussion

*Aspergillus* is a normal commensal of respiratory tract and external auditory canal. It involves CNS through contiguous or haematogenous spread. Intracranial



extension of *Aspergillus* from paranasal sinuses may occur either secondary to bone erosion or spread along vessels.<sup>[6]</sup> CNS aspergillosis can present in varied forms as infarction, granuloma, abscess, mycotic aneurysms, or meningoencephalitis.<sup>[4]</sup> It is a rare disease with reported mortality rate of 13–50% in patients with foci in paranasal sinuses and even higher mortality rates (80–100%) in patients of immune-compromised status.<sup>[3,5]</sup> The usual victims are immune-compromised hosts (those with organ transplant/AIDS/long-term steroids).<sup>[1-3]</sup> However, an increasing number of cases is identified in immune-competent population.

Classically, patients of intracranial aspergillosis present with signs and symptoms of space occupying lesion with/without a history of nasal blockage in setting of an immune-compromised patient. The usual presenting symptoms are nasal stuffiness, headache, periorbital pain, seizures, and cranial nerve deficits. Patients with orbital extension may develop proptosis, ophthalmoplegia, visual compromise, or chemosis.<sup>[7-9]</sup> The symptoms may evolve slowly or present acutely with infarction/hemorrhage secondary to the angioinvasive nature of fungus.<sup>[10]</sup> Patients of mycotic aneurysms may present with subarachnoid hemorrhage.

The modern day imaging techniques offer an opportunity for timely diagnosis, but finding is minimal on CT and MRI in early stages of CNS aspergillosis.<sup>[11,12]</sup> On CT a hyperdense mass involving sinuses along with bony expansion or erosion along the cranial base suggests fungal infection.<sup>[6]</sup> On MR sequences typical finding is that of a space occupying mass lesion with iso-hypointense signal on T1-weighted sequences and on T2-weighted sequences the lesion appears extremely hypointense.<sup>[6]</sup> This results from the concentration of ferromagnetic substances (iron/zinc/magnesium/manganese) within the lesion.<sup>[13]</sup> On gadolinium administration, the enhancement pattern varies from homogeneous to peripheral ring enhancement. The immune-competent hosts who muster a good immune response are more likely to present with homogeneous enhancement as compared to those with immune compromise, who bear more variable radiological appearance.<sup>[6]</sup> Such radiological appearance in an immune-competent host suggests the diagnosis of meningioma or tuberculoma earlier than fungal granuloma; however, hypointense appearance on T2-weighted sequences strongly points toward fungal granuloma.<sup>[6]</sup> Our patient represents an unusual radiological presentation of this entity with an iso-intense appearance on both T1- and T2-weighted image and homogeneous enhancement in the absence of characteristic T2 hypointensity.

The high mortality rate seen in this condition results from a prolonged delay in diagnosis as it may frequently mimic meningioma/tuberculoma.<sup>[6]</sup> Early intervention with focused treatment for fungal infection is the key to

reducing mortality and morbidity. This need is highlighted in our case where the patient initially suspected to have meningioma developed rapid deterioration with hemorrhagic infarct and left hemiplegia. Despite the delay in presentation, early treatment with anti-fungal could have averted the hemorrhagic complication.

There are no specific guidelines for management of intracranial aspergilloma, the commonly recommended regimen is surgery followed by antifungal treatment. Despite the development of newer, safer, and more effective antifungal medications surgical excision remains cornerstone in management of intracranial aspergilloma.<sup>[6]</sup> Schwartz *et al.* in their study have shown improved outcome in immune-compromised patients who underwent surgical excision with voriconazole therapy.<sup>[14]</sup> Radical excision of aspergilloma involving noneloquent region has shown to improve outcome and among those with sinonasal origin clearance of nasal passage is strongly recommended.<sup>[6]</sup>

Most common strain isolated in cerebral aspergillosis is *A. fumigatus* but the culprits in other instances are *A. flavus*, *A. niger* and *A. terreus*.<sup>[15]</sup> Diagnosis may be confirmed by histopathology, culture or galactomannan antigen.<sup>[16]</sup> In our patient, the diagnosis was established on both culture and histopathology. As per the recommendations of Infectious Diseases Society of America (2008) and American Thoracic Society (2011) voriconazole is recommended as monotherapy for invasive aspergillosis.<sup>[17,18]</sup> Patients who are intolerant to voriconazole may be managed with liposomal amphotericin B.<sup>[16]</sup>

The most common site is frontal lobe and immune-competent patients present with granuloma formation as was our case.<sup>[19]</sup> The most common site of colonization and source for CNS infection is lungs.<sup>[6]</sup> In our patient, however, no such colonization was documented, but the patient did have fungal nail plate infection. The recommended treatment regimen is surgery followed by oral voriconazole and despite this regimen patients usually have a dismal outcome with mortality rates of 28–85% in various series.<sup>[15]</sup> Some studies have also advised preoperative use of antifungal drugs in which a diagnosis of cerebral aspergillosis is suspected on clinical or radiological evaluation. Preoperative use of antifungal drugs may help in decreasing mortality and morbidity in these patients.

Aspergilloma is of relatively rare occurrence in immune-competent in comparison to immune-compromised patients. Morbidity and mortality are high despite adequate treatment. Early diagnosis and treatment may help in limiting mortality. When involving anterior cranial fossa base, it mimics meningioma or tuberculoma and hence must be kept in differential diagnosis during evaluation of neoplasm in this region.

## Financial support and sponsorship

Nil.

## Conflicts of interest

There are no conflicts of interest.

## References

1. Bokhari R, Baesa S, Al-Maghrabi J, Madani T. Isolated cerebral aspergillosis in immunocompetent patients. *World Neurosurg* 2014;82:e325-33.
2. Hoenigl M, Krause R. Antifungal therapy of aspergillosis of the central nervous system and *Aspergillus* endophthalmitis. *Curr Pharm Des* 2013;19:3648-68.
3. Kourkoumpetis TK, Desalermos A, Muhammed M, Mylonakis E. Central nervous system aspergillosis: A series of 14 cases from a general hospital and review of 123 cases from the literature. *Medicine (Baltimore)* 2012;91:328-36.
4. Kathuria MK, Gupta RK. Fungal infections. In: Gupta RK, Lufkin RB, editors. *MR Imaging and Spectroscopy of Central Nervous System Infections*. New York: Kluwer Press; 2001. p. 177-203.
5. Lee JC, Lim DJ, Ha SK, Kim SD, Kim SH. Fatal case of cerebral aspergillosis: A case report and literature review. *J Korean Neurosurg Soc* 2012;52:420-2.
6. Shamim MS, Siddiqui AA, Enam SA, Shah AA, Jooma R, Anwar S. Craniocerebral aspergillosis in immunocompetent hosts: Surgical perspective. *Neurol India* 2007;55:274-81.
7. Walsh TJ, Hier DB, Caplan LR. Aspergillosis of the central nervous system: Clinicopathological analysis of 17 patients. *Ann Neurol* 1985;18:574-82.
8. Beal MF, O'Carroll CP, Kleinman GM, Grossman RI. Aspergillosis of the nervous system. *Neurology* 1982;32:473-9.
9. Jinkins JR, Siqueira E, Al-Kawi MZ. Cranial manifestations of aspergillosis. *Neuroradiology* 1987;29:181-5.
10. MacCormick WF, Schochet SS Jr., Weaver PR, MacCrary JA 3<sup>rd</sup>. Disseminated aspergillosis. *Aspergillus* endophthalmitis, optic nerve infarction, and carotid artery thrombosis. *Arch Pathol* 1975;99:353-9.
11. Sorensen AG, Buonanno FS, Gonzalez RG, Schwamm LH, Lev MH, Huang-Hellinger FR, *et al.* Hyperacute stroke: Evaluation with combined multisection diffusion-weighted and hemodynamically weighted echo-planar MR imaging. *Radiology* 1996;199:391-401.
12. Boes B, Bashir R, Boes C, Hahn F, McConnell JR, McComb R. Central nervous system aspergillosis. Analysis of 26 patients. *J Neuroimaging* 1994;4:123-9.
13. Jain KK, Mittal SK, Kumar S, Gupta RK. Imaging features of central nervous system fungal infections. *Neurol India* 2007;55:241-50.
14. Schwartz S, Ruhnke M, Ribaud P, Corey L, Driscoll T, Cornely OA, *et al.* Improved outcome in central nervous system aspergillosis, using voriconazole treatment. *Blood* 2005;106:2641-5.
15. Nadkarni T, Goel A. Aspergilloma of the brain: An overview. *J Postgrad Med* 2005;51 Suppl 1:S37-41.
16. Marr KA, Schlamm HT, Herbrecht R, Rottinghaus ST, Bow EJ, Cornely OA, *et al.* Combination antifungal therapy for invasive aspergillosis: A randomized trial. *Ann Intern Med* 2015;162:81-9.
17. Walsh TJ, Anaissie EJ, Denning DW, Herbrecht R, Kontoyannis DP, Marr KA, *et al.* Treatment of aspergillosis: Clinical practice guidelines of the Infectious Diseases Society of America. *Clin Infect Dis* 2008;46:327-60.
18. Limper AH, Knox KS, Sarosi GA, Ampel NM, Bennett JE, Catanzaro A, *et al.* An official American Thoracic Society statement: Treatment of fungal infections in adult pulmonary and critical care patients. *Am J Respir Crit Care Med* 2011;183:96-128.
19. Mohammadi H, Sadeghi S, Zandi S. Central nervous system aspergilloma in an immunocompetent patient: A case report. *Iran J Public Health* 2015;44:869-72.