

Hemifacial Spasm Caused by a Vein: A Case Report

Abstract

Hemifacial spasm (HFS) caused by a venous offender is rare, and its clinical course and optimal surgical strategy are unclear. A case of 57-year-old male who had an HFS caused by a venous offender is described in this report. Frontalis, orbicularis oculi, orbicularis oris, and mentalis muscles were involved while his platysma muscle showed no spasm. He was treated successfully with microvascular decompression using Teflon felt and 12 months outcome was excellent without any complications. Lateral spread response was not observed in the facial electromyography during the whole operation. Adequate visualization of the facial nerve root exit zone and meticulous exploration for offenders are necessary to avoid surgical failure and reoperation.

Keywords: Hemifacial spasm, microvascular decompression, vein

Introduction

Hemifacial spasm (HFS) is a disorder that has involuntary paroxysmal movement in one side of the face. It is caused commonly by arterial compression of the root exit zone (REZ) of facial nerve in posterior fossa. However, it may have other unusual offenders such as cerebellopontine angle tumors, small unnamed arteries, and veins. Microvascular decompression (MVD) using Teflon felt have been performed as a standard surgical treatment for most of the cases. However in rare cases having unusual offenders, there are no definite surgical guidelines for each case. HFS caused by a vein is a rare finding and its clinical course, and optimal surgical strategy is unclear. In this paper, the authors report a case of HFS which was caused by a venous offender that was treated successfully with MVD using Teflon felt.

Case Report

A 57-year-old male visited the hospital with involuntary paroxysmal clonic movement on the left side of his face for 2 years. He had no history of Bell's palsy and other craniofacial diseases. He presented no periauricular pain and lacrimation, and salivation were normal. Frontalis, orbicularis oculi, orbicularis oris, and mentalis muscles were involved.

This is an open access journal, and articles are distributed under the terms of the Creative Commons Attribution-NonCommercial-ShareAlike 4.0 License, which allows others to remix, tweak, and build upon the work non-commercially, as long as appropriate credit is given and the new creations are licensed under the identical terms.

For reprints contact: reprints@medknow.com

No contraction of platysma muscle was observed. He had a House-Brackmann Grade II facial muscle weakness. His spasm had gradually been worsened, and so he suffered from problems with social relationships and activities.

The patient was diagnosed as HFS with his typical clinical findings. After 5 months of medical treatment which was not satisfactory, the patient decided to have a surgical treatment. Preoperative magnetic resonance imaging showed a small vessel having a contact with REZ of CN VII in the left side [Figure 1]. We decided to perform an exploration of REZ of the facial nerve and MVD for his HFS.

The operation was performed through a retrosigmoid suboccipital approach with a lateral park bench position, under generalized anesthesia. Intraoperative facial electromyography (EMG) and brainstem auditory evoked potentials (BAEPs) were monitored during the operation.

Careful retraction of the flocculus revealed the REZ of CN VII. There were no offending arteries found, instead, a small vein was observed to have a contact with the REZ [Figure 2a and b]. We found no other structures contacting with the facial nerve from REZ to distal cisternal portion of CN VII. Fine dissection between the facial nerve and the vein was performed to mobilize the vein away from the REZ [Figure 2c]. A small piece of Teflon felt

How to cite this article: Eun J, Choi Jg, Son Bc. Hemifacial spasm caused by a vein: A case report. Asian J Neurosurg 2018;13:786-8.

Jin Eun¹,
Jin-gyu Choi¹,
Byung-chul Son^{1,2}

¹Department of Neurosurgery, Seoul St. Mary's Hospital, ²Catholic Neuroscience Institute, College of Medicine, The Catholic University of Korea, Seoul, Republic of Korea

Address for correspondence:
Prof. Byung-chul Son,
222 Banpo-daero, Seocho-gu,
Seoul 137-702,
Republic of Korea.
E-mail: sbc@catholic.ac.kr

Access this article online

Website: www.asianjns.org

DOI: 10.4103/1793-5482.238005

Quick Response Code:



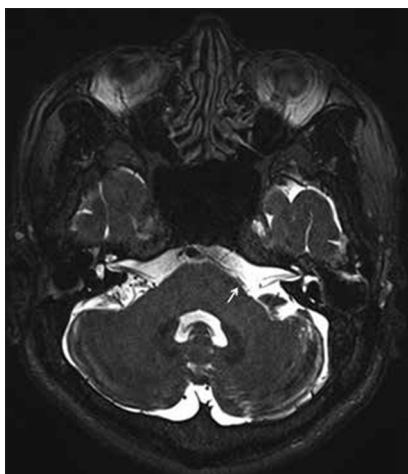


Figure 1: Preoperative T2 magnetic resonance imaging of the patient. A small vessel having a contact with root exit zone of CN VII is observed in the left side (white arrow)

was placed between the vein and the REZ [Figure 2d]. To prevent migration of Teflon felt, fibrin glue was applied. Facial EMG and BAEP showed no change during the operation. LSR was not definitely observed from the start.

There was no immediate improvement of spasm. The spasm showed progressive improvement from the third postoperative day and eventually disappeared at the seventh postoperative day. No facial palsy or hearing impairment was observed. The postoperative course was uneventful, and he was free of spasm at 12 months postoperative follow-up.

Discussion

Primary HFS is related to paroxysmal ephaptic transmission and functional changes in the facial motor nucleus which is caused by vascular compression of the facial nerve REZ.^[1-4] The cause of vascular compression of REZ is unclear. Atherosclerosis and hypertension have been thought to be possible contributing factors for arterial compression of REZ in adults, but controversy remains still.^[4-6] There were some reports that arachnoid adhesion and thickening may cause HFS in children and adolescents, who have nothing to do with atherosclerosis or hypertension.^[7] However, it is difficult to find a relevant explanation regarding venous compression to facial nerve REZ. Our intraoperative finding was that a vein was densely adherent to the cranial, and lateral side of facial nerve REZ [Figure 2] and no other causes such as arachnoid adhesion or thickening were found.

Though it is still controversial, the most common offender reported is anterior inferior cerebellar artery or posterior inferior cerebellar artery [Table 1].^[1,8-13] HFS caused by a venous offender is rare (0–7.9%) and reported clinical characteristics are limited [Table 1]. Since Jannetta reported a case of HFS caused by a venule in 1984,^[14] the report describing HFS with venous offender is limited.^[15]

In the present case, frontalis, orbicularis oculi, orbicularis oris, and mentalis muscles were involved within symptom

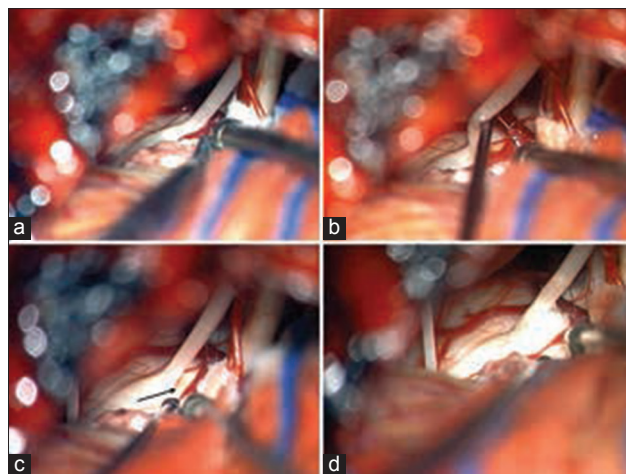


Figure 2: Intraoperative findings of hemifacial spasm caused by a vein. (a) An intraoperative photograph showing that there is no arterial offender in the root exit zone of the facial nerve except a venous loop adherent to the cranial and lateral portion of the facial nerve root exit zone. Some deviation of the distal portion of the facial root exit zone was noted. (b) With an elevation of the facial nerve, a vein, and a small tributary vein are found. (c) After careful mobilization of veins from the facial root exit zone, a small dimple (arrow) on the pial surface of the pons is found and the venous structure is now away from the facial root exit zone. (d) A small piece of Teflon felt was inserted between the facial nerve root exit zone and the vein

Table 1: Offenders of large series of microvascular decompression for treatment of hemifacial spasm

Author (year)	Cases involved	Most common offender (%)	Vein (%)
Barker (1995) ^[8]	648	PICA (68.2)	19 (2.9)
Chung <i>et al.</i> , (2001) ^[9]	1169	PICA (42.7)	1 (0.1)
Illingworth <i>et al.</i> , (1996) ^[10]	83	PICA (52.8)	5 (6)
Samii <i>et al.</i> , (2002) ^[11]	145	AICA (54.5)	6 (4.1)
Dannenbaum <i>et al.</i> , (2008) ^[12]	114	AICA (43)	9 (7.9)
Hyun <i>et al.</i> , (2010) ^[11]	1174	AICA (53.2)	4 (0.3)
Shimizu <i>et al.</i> , (2015) ^[13]	100	AICA (23)	0 (0)

AICA – Anterior inferior cerebellar artery; PICA – Posterior inferior cerebellar artery

while no contraction of platysma muscle was observed. In Jannetta's report, the patient had contractions in platysma muscle as well as other facial muscles.^[14] In Wang *et al.*'s clinical analysis of 15 cases of venous offender in HFS patient, the platysma muscle involvement was found in 60% of patients, a higher incidence compared to patients with HFS caused by arterial compression.^[15] In this case, however, the platysma muscle was not involved preoperatively, which was different with those reports.

The LSR is an abnormal muscle response presumed to be caused by ephaptic transmission at the lesion site and motor nucleus hyperactivity of facial nerve in HFS patients.^[2,3,16] It is observed 85.5% of HFS patients in a large prospective study.^[11] In Wang *et al.*'s report, all the 15 patients presented

LSR intraoperatively who had vein as an offender for their HFS.^[15] However, LSR was not observed in this case. It could be caused by anesthesia-related reasons such as muscle relaxant use or by technical error of the technician or by other unknown reasons. According to a large series by Park *et al.*, despite efforts to detect LSR in patients without initial intraoperative LSR on facial EMG, 14.5% of patients showed no LSR eventually.^[1]

The postoperative course of this patient is very similar with Jannetta's case.^[14] Immediate postoperatively, patients of both cases showed no dramatic improvement. Their spasm gradually improved and it took about a week to get a full recovery from the spasm. 12 months outcome was excellent despite previous reports concluded that presence of vein can increase the recurrence rate of HFS.^[8,17,18]

Various techniques have been performed for HFS patients during MVD. The most common technique is interposing with Teflon felt. It is performed for most of HFS cases with arterial compression. Unlike arterial compression, a vein is difficult to mobilize. Because a venous wall is not elastic as an artery's wall, it bleeds easily, and dissection and mobilization are very difficult. Therefore, coagulation and cutting are chosen for some cases. Though cutting a vein in posterior fossa can cause cerebellar edema and hemorrhage due to venous infarction,^[19] many centers with large number of MVD cases, performing MVDs for both HFS and trigeminal neuralgia, report that coagulation and cutting the offending vein is performed in their institutes with quite excellent outcomes, while they try to preserve the superior petrosal vein during the approach.^[11,20,21] The author's policy is to preserve all vessels if possible. If a vein should be coagulated, it must be considered carefully depending on the diameter and course of the vein.

A small vein can be a cause of HFS. Adequate visualization of the facial nerve REZ and meticulous exploration for offenders are necessary to avoid surgical failure and reoperation. Because the published information about these patients are very limited, more reports with large case series describing the clinical characteristics and investigating best surgical strategies for HFS patients with venous offenders are required.

Financial support and sponsorship

Nil.

Conflicts of interest

There are no conflicts of interest.

References

- Hyun SJ, Kong DS, Park K. Microvascular decompression for treating hemifacial spasm: Lessons learned from a prospective study of 1,174 operations. *Neurosurg Rev* 2010;33:325-34.
- Gardner WJ. Cross talk – The paradoxical transmission of a nerve impulse. *Arch Neurol* 1966;14:149-56.
- Møller AR, Jannetta PJ. Microvascular decompression in hemifacial spasm: Intraoperative electrophysiological observations. *Neurosurgery* 1985;16:612-8.
- Jannetta PJ. Observations on the etiology of trigeminal neuralgia, hemifacial spasm, acoustic nerve dysfunction and glossopharyngeal neuralgia. Definitive microsurgical treatment and results in 117 patients. *Neurochirurgia (Stuttg)* 1977;20:145-54.
- Defazio G, Martino D, Aniello MS, Masi G, Logroscino G, Manobianca G, *et al.* Influence of age on the association between primary hemifacial spasm and arterial hypertension. *J Neurol Neurosurg Psychiatry* 2003;74:979-81.
- Ohta M, Kobayashi M, Terano N, Wakiya K, Suzuki K, Fujimaki T. Does arteriosclerosis contribute to hemifacial spasm? *Acta Neurochir (Wien)* 2016;158:181-8.
- Liang J, Guo Z, Zhang L, Yu Y. Adolescent-onset idiopathic hemifacial spasm. *Neurol India* 2014;62:175-7.
- Barker FG 2nd, Jannetta PJ, Bissonette DJ, Shields PT, Larkins MV, Jho HD. Microvascular decompression for hemifacial spasm. *J Neurosurg* 1995;82:201-10.
- Chung SS, Chang JH, Choi JY, Chang JW, Park YG. Microvascular decompression for hemifacial spasm: A long-term follow-up of 1,169 consecutive cases. *Stereotact Funct Neurosurg* 2001;77:190-3.
- Illingworth RD, Porter DG, Jakubowski J. Hemifacial spasm: A prospective long-term follow up of 83 cases treated by microvascular decompression at two neurosurgical centres in the United Kingdom. *J Neurol Neurosurg Psychiatry* 1996;60:72-7.
- Samii M, Günther T, Iaconetta G, Muehling M, Vorkapic P, Samii A. Microvascular decompression to treat hemifacial spasm: Long-term results for a consecutive series of 143 patients. *Neurosurgery* 2002;50:712-8.
- Dannenbaum M, Lega BC, Suki D, Harper RL, Yoshor D. Microvascular decompression for hemifacial spasm: Long-term results from 114 operations performed without neurophysiological monitoring. *J Neurosurg* 2008;109:410-5.
- Shimizu K, Matsumoto M, Wada A, Sugiyama T, Tanioka D, Okumura H, *et al.* Supine no-retractor method in microvascular decompression for hemifacial spasm: Results of 100 consecutive operations. *J Neurol Surg B Skull Base* 2015;76:202-7.
- Jannetta PJ. Hemifacial spasm caused by a venule: Case report. *Neurosurgery* 1984;14:89-92.
- Wang X, Thirumala PD, Shah A, Gardner P, Habeych M, Crammond D, *et al.* The role of vein in microvascular decompression for hemifacial spasm: A clinical analysis of 15 cases. *Neurol Res* 2013;35:389-94.
- Møller AR, Jannetta PJ. Monitoring facial EMG responses during microvascular decompression operations for hemifacial spasm. *J Neurosurg* 1987;66:681-5.
- Engh JA, Horowitz M, Burkhart L, Chang YF, Kassam A. Repeat microvascular decompression for hemifacial spasm. *J Neurol Neurosurg Psychiatry* 2005;76:1574-80.
- Li S, Hong W, Tang Y, Ying T, Zhang W, Li X, *et al.* Re-operation for persistent hemifacial spasm after microvascular decompression with the aid of intraoperative monitoring of abnormal muscle response. *Acta Neurochir (Wien)* 2010;152:2113-8.
- Masuoka J, Matsushima T, Hikita T, Inoue E. Cerebellar swelling after sacrifice of the superior petrosal vein during microvascular decompression for trigeminal neuralgia. *J Clin Neurosci* 2009;16:1342-4.
- Barker FG 2nd, Jannetta PJ, Bissonette DJ, Larkins MV, Jho HD. The long-term outcome of microvascular decompression for trigeminal neuralgia. *N Engl J Med* 1996;334:1077-83.
- Dumot C, Sindou M. Trigeminal neuralgia due to neurovascular conflicts from venous origin: An anatomical-surgical study (consecutive series of 124 operated cases). *Acta Neurochir (Wien)* 2015;157:455-66.