

CASE REPORT

Pituitary hyperplasia resulting from primary hypothyroidism

Amit Agrawal, S. K. Diwan¹Departments of Neurosurgery, and ¹Medicine, Datta Meghe Institute of Medical Sciences, Sawangi (Meghe), Wardha, Maharashtra, India

ABSTRACT

We report an unusual case of pituitary hyperplasia secondary to primary hypothyroidism clinically masquerading pituitary apoplexy. A 22-year-old female presented with intermittent headache, easy fatigability, facial puffiness, coarseness of facial features, and hoarseness of voice for six months duration. Diplopia and diminution of vision was also observed for the last 15 days. Brain imaging findings showed pituitary enlargement, the thyroid function test were suggestive of primary hypothyroidism. Patient did well with thyroid hormone replacement therapy.

Key words: Endocrine, hypothyroidism, pituitary adenoma, pituitary tumor, thyroiditis

Introduction

Pituitary enlargement secondary to primary hypothyroidism is an uncommon occurrence and the reactive pituitary gland enlargement may be difficult to differentiate from inflammatory disorders as well as from functional pituitary adenomas.^[1-3] In this article, we report a case of pituitary hyperplasia secondary to primary hypothyroidism that was masquerading pituitary apoplexy clinically and discuss the characteristic features that helped us to differentiate these two conditions.

Case Report

A 22-year-old female presented with intermittent headache of two year duration, easy fatigability of one year duration, facial puffiness for one year, coarseness of facial features, and hoarseness of voice for the last six months [Figure 1]. She developed diplopia and diminution in vision for the last 15 days. There was no history of altered sensorium. She was having constipation off and on for two to three years and

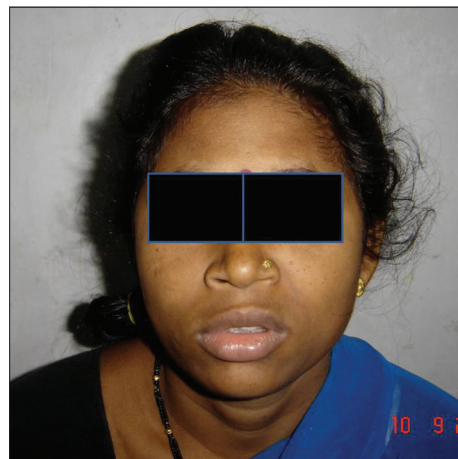

Figure 1: Clinical photograph showing coarse facial features

oligomenrhea since 10 years. Her appetite was normal. Based on these clinical features, a diagnosis of sellar mass lesion was suspected at a peripheral hospital, and a CT scan and magnetic resonance imaging (MRI) of brain showed diffuse pituitary enlargement [Figures 2 and 3]. On examination, pulse rate was 72 beats/minute and regular. She was conscious, but dull. Cranial nerves normal except right lateral rectus paresis. Fundus and vision in both the eyes was normal. There were no focal neurological deficits. Deep tendon reflexes were normal. Routine blood investigations were normal, except low hemoglobin (8.1 gm/dL). Her hormonal profile showed raised thyrotrophin stimulating hormone (TSH) (150 microIU/dL, range 0.30-5.5) and low T3 (17 ng/dL, range 60-200) and T4 (1.90 microgram/mL, range 4.5-12.0). Prolactin was 35 IU/dL. Further investigation showed positive anti-thyroglobulin antibodies (1:15 dilution) but negative antimicrosomal antibodies. A diagnosis of autoimmune thyroiditis and primary hypothyroidism with pituitary hyperplasia was suspected.

Access this article online

Quick Response Code:



Website:

www.asianjns.org

DOI:

10.4103/1793-5482.92171

Address for correspondence:

Dr. Amit Agrawal, Department of Neurosurgery, MM Institute of Medical Sciences and Research, Mullana (Ambala), Haryana - 133 203, India. E-mail: dramitagrawal@gmail.com

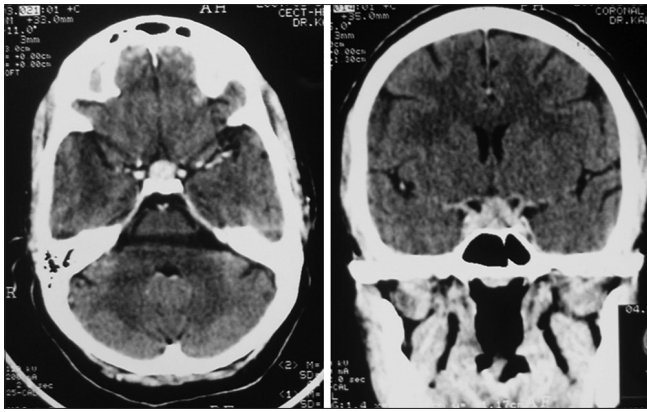


Figure 2: Contrast CT scan showing diffuse enlargement of pituitary gland

She was started on tablet L-thyroxin and low dose of steroids. At two-year follow-up, she was doing well and T3, T4 and TSH levels were in normal range. Follow-up imaging was not performed.

Discussion

Primary hypothyroidism presenting as a pituitary mass is a rare, but a well known entity that can be referred to a neurosurgeon for removal of a pituitary mass.^[1] In the present case, the patient presented with chronic headache and recent onset of diplopia and diminution of vision, features those favored the diagnosis of pituitary tumor with apoplexy, a diagnosis further supported by positive imaging findings. However, a careful analysis of symptoms revealed that she had mainly the features of hypothyroidism. Diplopia in the present case could be due to thyroid ophthalmopathy (lateral rectus involvement) and probably responsible for diminution of subjective visual acuity. In the literature, it has been suggested that in presence of markedly elevated TSH, absence of clinical features of hyperthyroidism, and low thyroid hormone values, one should suspect a diagnosis of pituitary enlargement secondary to primary hypothyroidism.^[1,4] In this type of pituitary hyperplasia, the thyrotroph cells becoming enlarged by lack of negative feedback; indeed, the hormonal profile is usually straightforward, displaying

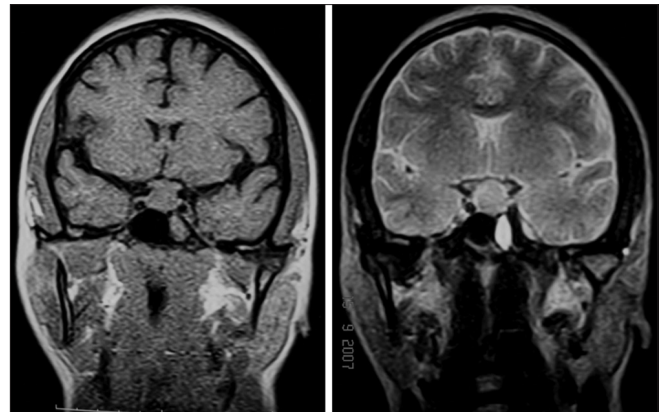


Figure 3: MRI scan(s) showing diffuse enlargement of pituitary gland

unambiguous marked primary hypothyroidism with low circulating thyroid hormones and elevated TSH, easily reversible upon thyroid replacement.^[5] Recognition of this entity is crucial (as in present case). Complete regression can be achieved with thyroxine replacement therapy.^[1-3,5] This case also illustrates the importance of determining thyroid function tests during the investigation of pituitary masses and avoiding the need to perform pituitary surgery.^[4]

References

1. Nicholas WC, Russell WF. Primary hypothyroidism presenting as a pituitary mass. *J Miss State Med Assoc* 2000;41:511-4.
2. Young M, Kattner K, Gupta K. Pituitary hyperplasia resulting from primary hypothyroidism mimicking macroadenomas. *Br J Neurosurg* 1999;13:138-42.
3. Ehirim PU, Kerr DS, Cohen AR. Primary hypothyroidism mimicking a pituitary macroadenoma. *Pediatr Neurosurg* 1998;28:195-7.
4. Betônico CC, Rodrigues R, Mendonça SC, Jorge PT. [Primary hypothyroidism mimicking pituitary macroadenoma][Article in Portuguese] *Arq Bras Endocrinol Metabol* 2004;48:423-6.
5. Beck-Peccoz P, Brucker-Davis F, Persani L, Smallridge RC, Weintraub BD. Thyrotropin-secreting pituitary tumors. *Endocr Rev* 1996;17:610-38.

How to cite this article: Agrawal A, Diwan SK. Pituitary hyperplasia resulting from primary hypothyroidism. *Asian J Neurosurg* 2011;6:99-100.

Source of Support: Nil, **Conflict of Interest:** None declared.

Announcement

iPhone App



Download
iPhone, iPad
application

FREE

A free application to browse and search the journal's content is now available for iPhone/iPad. The application provides "Table of Contents" of the latest issues, which are stored on the device for future offline browsing. Internet connection is required to access the back issues and search facility. The application is Compatible with iPhone, iPod touch, and iPad and Requires iOS 3.1 or later. The application can be downloaded from <http://itunes.apple.com/us/app/medknow-journals/id458064375?ls=1&mt=8>. For suggestions and comments do write back to us.