

CASE REPORT

Idiopathic hypertrophic cranial pachymenigitis – A long follow-up needed

M. A. Hashmi, G. Gautam¹, P. Sengupta¹, H. Singh², N. Haque²

EKO CT and MRI Scan Centre, Medical College and Hospitals Campus, Kolkata, ¹Department of Neurology, Medical College and Hospitals, Kolkata, ²Department of Radiology, Darbhanga Medical College, India

ABSTRACT

Idiopathic hypertrophic cranial pachymenigitis is a rare clinical condition caused by localized or diffuse inflammatory thickening of dura matter. Described here is a person having diffuse thickening of dura matter of base of skull and he was on follow-up treatment for 5 years with us. Diagnosis was done by excluding other conditions and with biopsy. The patient responded to steroid and the MRI picture, which is given serially, shows improvement

Key words: Idiopathic hypertrophic cranial pachymenigitis, magnetic resonance imaging

Introduction

Idiopathic hypertrophic cranial pachymenigitis is a focal or diffuse swelling of dura matter of brain or spine. Usually males are involved. The patient presents as headache, cranial nerve palsy, cerebellar ataxia, neuro-ophthalmic problems etc. These signs and symptoms are due to entrapment of cranial nerve or Cerebro-spinal fluid (CSF) flow interruption.^[1,2] Diagnosis is based on exclusion of a large number of inflammatory causes like tubercular, fungal, syphilis, etc. Other conditions like collagen vascular disease, sarcoidosis, mucopolysaccharidosis, and neoplastic conditions like lymphomas and meningiomas are excluded.^[1] MRI scan is very helpful and it can depict the extent and thickening of the dura and its follow-up.^[2]

Case Report

The patient was from Medical College and Hospitals. The patient had presented in 2004 with headache and diplopia.^[4] He also had a H/O of vocal cord paralysis. The study was done on 1.5 tesla GE signa and contrast Gadodiamide (Omniscan) was used.

His MRI scan had shown thickened dura of base of skull [Figures 1 and 2]. He was put on full course of antitubercular medicine. In 2006, the patient came back with not much relief of his symptoms. MRI did not reveal much change [Figure 3]. His Polymerase chain reaction (PCR) for tuberculosis and Elisa test for HIV were negative. A CSF study revealed no acid-fast bacilli or fungal lesions. His adenosine deaminase level was normal. His rheumatoid arthritis factor was within normal limit. A test for sarcoidosis was also negative. Serum angiotensin converting enzyme, C-Reactive Protein (CRP), and Venereal Disease Research Laboratory (VDRL) tests were also negative. A biopsy revealed inflammatory areas and the patient was put on steroid therapy with mark recovery of symptoms. MRI findings show improvement as a decrease in enhancement in postcontrast study [Figure 4].

Discussion

Idiopathic hypertrophic cranial pachymenigitis is a chronic fibrogenic inflammatory disease of dura leading to focal and diffuse thickening of it.^[5,6] The patient usually present with complains which are usually due to the local factor related to its thickening. Pressure effects are seen on exiting nerves with flow disturbance of CSF being noted. The diagnosis is done first by exclusion of all the common conditions leading to thickening of dura and it is confirmed by biopsy of the dura.^[7-10] Mark typical enhancement of dura matter is seen in MRI.^[6] The enhancement is evenly seen with no gyral pattern, which is seen in pachymenigitis. As the inflammatory condition resolves the enhancement also decreases.

In South Asians the common condition of tuberculosis has to be excluded. The patient should be closely monitored and long-term evaluation of the patient is needed in this disease.

Access this article online

Quick Response Code:



Website:

www.asianjns.org

DOI:

10.4103/1793-5482.92181

Address for correspondence:

Dr. M. A. Hashmi, EKO CT and MRI Scan Centre, At Medical College and Hospitals Campus, 88-College St, Kolkata - 700 073, India. E-mail: ahashmidr@yaho.co.in

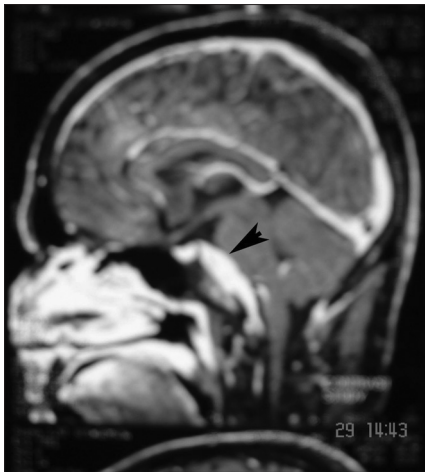

Figure 1: T1 weighted postcontrast sagittal images are showing thickened dura matter at the base of skull pointed by the arrowhead

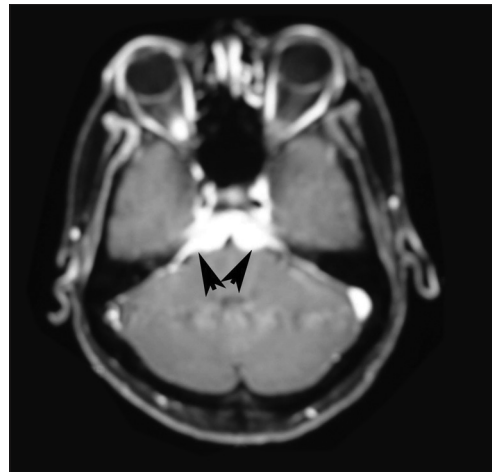


Figure 2: T1 weighted postcontrast axial images showing thickened thecal sac

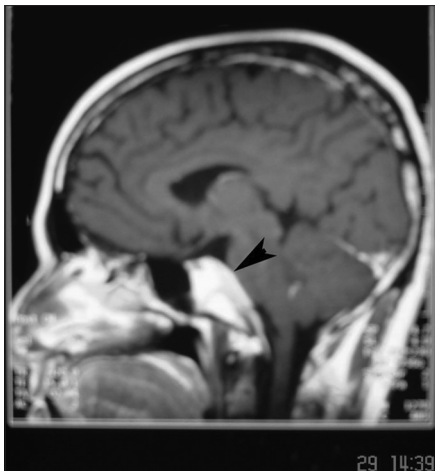

Figure 3: Not much changes are seen in comparison to Figure 1 after full course of antitubercular treatment

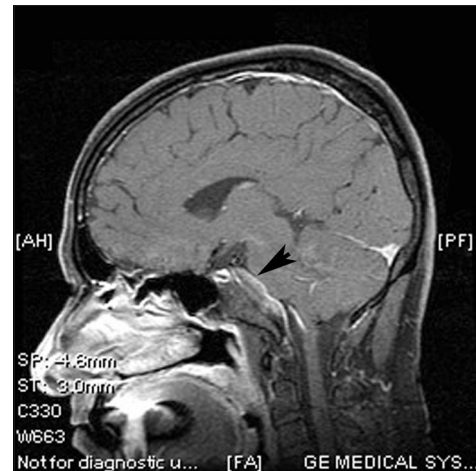


Figure 4: Mark improvement is seen with the lesion not enhancing much and resolving after the patient was put on steroids

References

- Misra UK, Kalita J. Idiopathic hypertrophic cranial pachymeningitis: Easy to suspect, difficult to prove. *Neurol India* 2002; 50:4-5.
- Kupersmith MJ, Martin V, Heller G, Shah A, Mitnick HJ. Idiopathic hypertrophic pachymeningitis. *Neurology* 2004;62: 686-94.
- Goyal M, Malik A, Mishra NK, Gaikwad SB. Idiopathic hypertrophic pachymeningitis: Spectrum of the disease. *Neuroradiology* 1997; 39:619-23.
- Terada K, Misu N, Nara Y. Painful ophthalmoplegia caused by idiopathic hypertrophic cranial pachymeningitis in the cavernous sinus. *J Clin Neurosci* 1998;5:363-5.
- Vargas-Bellina V, Saavedra-Pastor H, Alvarado-Rosales M, Porras-Carrión M, Cjuno-Pinto R, Gonzales-Quispe I, *et al.* Idiopathic hypertrophic pachymeningitis: A case report. *Rev Neurol* 2009; 48:300-3.
- Rudnik A, Larysz D, Gamrot J, Rudnik A, Skorupa A, Bierzyńska-Macyszyn G, *et al.* Bazowski idiopathic hypertrophic pachymeningitis - Case report and literature review. *Folia Neuropathol* 2007;45:36-42.
- Pai S, Welsh CT, Patel S, Rumboldt Z. Idiopathic hypertrophic spinal pachymeningitis: Report of two cases with typical MR imaging findings *AJNR Am J Neuroradiol* 2007;28:590-2.
- Lowden MR, Gill D. Teaching neuroImage: Idiopathic hypertrophic spinal pachymeningitis. *Neurology* 2009;72: e27.
- Ahmadi-Simab K, Lamprecht P, Reuter M, Gross WL. Pachymeningitis in mixed connective tissue disease. *Ann Rheum Dis* 2005;64:1656-7.
- Chang GY, Park SH, Youn YC, Kwon OS. Neuroimaging findings in scleroderma en coup de sabre. *Neurology* 2004;63:2197-8.

How to cite this article: Hashmi MA, Gautam G, Sengupta P, Singh H, Haque N. Idiopathic hypertrophic cranial pachymeningitis - A long follow-up needed. *Asian J Neurosurg* 2011;6:119-20.

Source of Support: Nil, **Conflict of Interest:** None declared.