

CASE REPORT

Isolated intramedullary spinal cord cysticercosis

Shubhangi V. Agale, Shweta Bhavsar, Barnik Choudhury, Vidhya Manohar

Department of Pathology, Grant Medical College, Mumbai, Maharashtra, India

ABSTRACT

We report a case of intradural, intramedullary, spinal cord neurocysticercosis at dorsal 10-11 (D10-11) level in a mentally retarded male. A 38-year-old, mentally retarded male presented with weakness and stiffness in both the lower limbs and waist since one year. Magnetic resonance imaging revealed a D10-D11 intradural space occupying lesion with cord compression. Intraoperatively, the tumor was grayish white, soft, cystic, and intramedullary with a well-defined plane with surrounding cord tissue. Gross examination revealed a cystic lesion of $1.5 \times 1 \times 0.8$ cm, with a whitish nodule of 0.3 cm in diameter. The cyst wall was thin, shiny, and translucent. Microscopic examination revealed cysticercous cyst. Spinal neurocysticercosis should be considered in differential diagnosis of spinal mass lesion in patients residing in endemic area such as India.

Key words: Cysticercosis, intramedullary, spinal cord, neurocysticercosis

Introduction

Cysticercosis is a parasitic disease caused by the larval stage of *Taenia solium*.^[1-4] Human Cysticercosis was first described in 1550 by Paranoli, and the causative agent *Taenia solium* was recognized by Leuckart and Kuchenmeister, much later in the 19th century.^[5] Cysticercosis is endemic in Indian subcontinent. In endemic regions, the incidence of neurocysticercosis approaches 4% of the general population.^[5]

The authors report a case of D10-D11 intradural, intramedullary neurocysticercosis in a mentally retarded male, who was presented with weakness in both the lower limbs and was unable to walk.

Case Report

A 38-year-old, mentally retarded male presented with weakness and stiffness in both the lower limbs and waist since one year. He developed weakness in the left lower limb which was gradual in onset and progressive in nature. This was followed by weakness in the right lower limb in a similar

pattern. Examination revealed increased tone and zero power in both the lower limbs. There was no evidence of diminished sensation to pain, touch, and temperature. Magnetic resonance imaging (MRI) revealed a D10-D11 intradural space occupying lesion with cord compression [Figure 1]. Preoperatively, diagnosis of neurofibroma was considered on neuroimaging. D10-D11 laminectomy with removal of tumor and myelotomy was carried out. Intraoperatively, the tumor was grayish white, cystic, soft, and intramedullary with a well-defined plane with surrounding cord tissue. The final diagnosis, however, turned out to be cysticercosis, after histopathological examination. The patient was given a course of albendazole after surgery and he recovered from the weakness. The spasticity decreased in both the lower limbs and power improved to 3/5, so that he was able to walk with support.

Pathological findings

Gross examination revealed a cystic lesion of $1.5 \times 1 \times 0.8$ cm, with a whitish nodule of 0.3 cm in diameter. The cyst wall was thin, shiny, and translucent [Figure 2]. Microscopic examination revealed cysticercous cyst comprised of branched tract with external eosinophilic wavy layer, whose inner aspect rested on a marginal cell layer with scant nuclei. Internal to this was a layer of loose connective tissue [Figure 3].

Discussion

Spinal cysticercosis is a rare form of neurocysticercosis with an incidence of 0.7 to 5.85%.^[4] This low incidence of spinal cysticercosis can be explained on the basis of 'sieve effect'. Majority of cysticerci cannot pass through the subarachnoid space at the cervical level due to its size and the physiological sieve.^[1]

Access this article online

Quick Response Code:



Website:

www.asianjns.org

DOI:

10.4103/1793-5482.98655

Address for correspondence:

Dr. Shubhangi V. Agale, Flat No. 6, Dhanvantari Bldg, Sir JJ Hospital Campus, Byculla, Mumbai - 400 008, Maharashtra, India.
E-mail: shubhagale@hotmail.com

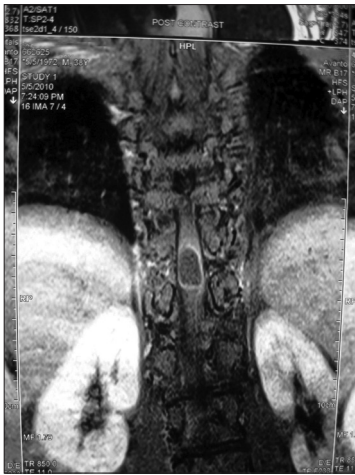

Figure 1: MRI revealed D10–D11 intradural space occupying lesion

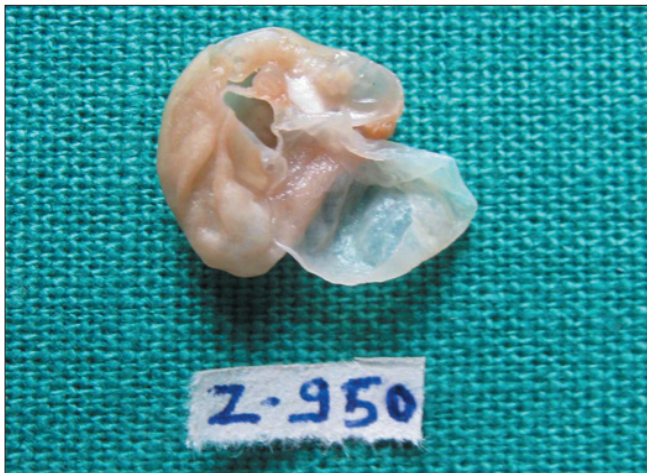

Figure 2: A 1.5×1.0×0.8 cm septate cystic lesion with a whitish nodule; cyst wall was thin, shiny, and grayish white

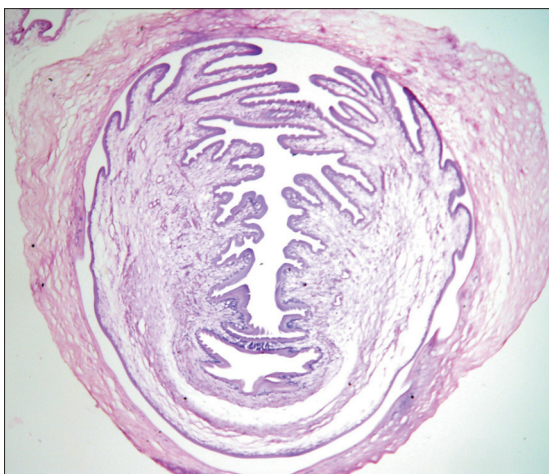


Figure 3: Cysticercous cyst comprised of branched tracts with eosinophilic wavy layer

Spinal neurocysticercosis occurs in patients with intracranial neurocysticercosis in approximately 75% of the cases, and isolated cases of spinal neurocysticercosis either intra-

medullary or extramedullary are considered to be very rare.^[5,6] Spinal forms have been identified in the vertebral, extradural, intradural, and intramedullary regions. Intramedullary involvement in cysticercosis is seldom observed accounting for fewer than 20% of the intradural spinal cases.^[1] Migration of the cysticercus through the ventriculo-ependymal pathway and hematogenous dissemination has been identified to be the possible pathogenetic mechanisms. The higher incidence of spinal neurocysticercosis in the thoracic region may be related to the high blood flow in the thoracic segment of the spinal cord.^[4,7]

These patients usually present with radicular pain, paraesthesia, paraparesis, bowel and bladder incontinence, and sensory loss.^[1] The clinical presentation depends on location, spinal level, lesion size and presence or absence of inflammation.^[5,8] Our patient presented with features of cord compression.

In the absence of previous history of neurocysticercosis or subcutaneous nodules, it may be difficult to clinically suspect intramedullary cysticercosis.^[7] High eosinophilic count and calcification of soft tissues in the plain radiogram may be suggestive, but such are rare.^[4,7] Cerebrospinal fluid and serum enzyme linked immunoelectric transfer blot assay for cysticercus antibody may be helpful.^[7] Cerebrospinal fluid studies were not performed in this case, as the diagnosis was not considered preoperatively. MR imaging can help in diagnosis of these lesions on which the cysticercal cysts appear hypointense on T1W1 MRI and hyperintense on T2W1 with surrounding edema.^[6,9] Sometimes, MRI features may be similar to intramedullary or extramedullary neoplastic mass lesions, as in our case.

Though various therapeutic options exist for spinal neurocysticercosis, the rarity of spinal involvement has precluded the evolution of definite guidelines as compared to cerebral neurocysticercosis.^[5] Medical treatment of intramedullary spinal cysticercosis can be considered in patients with a stable neurological status and in cases diagnosed by cerebrospinal fluid assay. However, in patients presenting with acute or progressive neurological state, and in those where the diagnosis is missed or is in doubt, surgical excision is the choice of treatment as histopathology not only confirms the diagnosis, but early surgery also provides recovery before any irreversible cord damage takes place.^[8] Postoperatively, anticysticercal drugs should be instituted.^[4,5]

Conclusions

Spinal neurocysticercosis should be considered in differential diagnosis of spinal mass lesion in patients residing in endemic area such as India. In patients with spinal form, clinical and imaging features may be similar to intramedullary or

extramedullary neoplastic mass lesions. Both surgical and medical therapy has a role in the management of spinal cysticercosis.

References

1. Colli BO, Valenca MM, Carlotti CG Jr, Machado HR, Assirati JA Jr. Spinal cord cysticercosis: Neurological aspects. *Neurosurg Focus* 2002;12:9.
2. Flisser A, Sarti E, Lightowers M, Schantz P. Neuro cysticercosis: Regional status, epidemiology, impact and control measures in the Americas. *Acta Trop* 2003;87:43-51.
3. Rajeshwar V, Joshi DD, Doanh NQ, van De N, Xiaonong Z. Taenia solium taeniosis/cysticercosis in Asia: Epidemiology, impact and issues. *Acta Trop* 2003;87:53-60.
4. Mohanty A, Das S, Kolluri VR, Das BS. Spinal extradural cysticercosis: A case report. *Spinal Cord* 1998;36:285-7.
5. Alsina GA, Johnson JP, McBride DQ, Rhoten PR, Mehringer CM, Stokes JK. Spinal neurocysticercosis. *Neurosurg Focus* 2002;12:1-7.
6. Kasliwal MK, Gupta DK, Suri V, Sharma BS, Garg A. Isolated Spinal neuro cysticercosis with clinical pleomorphism. *Turk Neurosurg* 2008;18:294-7.
7. Singh P, Sahai K. Intramedullary cysticercosis. *Neurol India* 2004;52:264-5.
8. Gupta S, Singh PK, Gupta B, Singh V, Azam A. Isolated primary intradural extramedullary spinal neurocysticercosis: A case report and review of literature. *Acta Neurol Taiwan* 2009;18:187-92.
9. Garcia HH, Del Brutto OH. Cysticercosis working group in Peru. Neurocysticercosis: Updated, concepts about an old disease. *Lancet Neurol* 2005;4:653-61.

How to cite this article: Agale SV, Bhavsar S, Choudhury B, Manohar V. Isolated intramedullary spinal cord cysticercosis. *Asian J Neurosurg* 2012;7:90-2.

Source of Support: Nil, **Conflict of Interest:** None declared.