

CASE REPORT

Mixed Medullary-Follicular Thyroid Cancer Treated with Surgery and Radioiodine Ablation: An Illustrative Case

Alaaeldin MK Bashier¹, Manal Abdulrahim², Shaheena Dawood³, Fauzia Rashid¹, Fatheya Alawadi¹

¹Endocrine, ²Histopathology and ³Oncology Units, Dubai Hospital, Dubai Health Authority, Dubai, United Arab Emirates.

Corresponding author: Dr. A MK Bashier Email: alaaeldin11@gmail.com

Published: 28 February 2015

Ibnosina J Med BS 2015;7(1):31-36

Received: 24 October 2014

Accepted: 28 December 2014

This article is available from: <http://www.ijmbs.org>

This is an Open Access article distributed under the terms of the Creative Commons Attribution 3.0 License, which permits unrestricted use, distribution, and reproduction in any medium, provided the original work is properly cited.

Abstract

Introduction: Differentiated thyroid cancer is the commonest cancer affecting thyroid gland. Medullary thyroid carcinoma (MTC) constitutes only 2-8% of all thyroid cancers. Simultaneous occurrence of mixed medullary and follicular thyroid carcinoma (mixed MTC-FTC) is rare. This may pose challenges in diagnosis, treatment, follow up and future prediction of prognosis.

Case presentation: A 24 -year-old female presented with a neck swelling that increased in size over 2 months period. She was clinically and biochemically euthyroid. Thyroid Technetium Pertechnetate (^{99m}TcO₄) scan showed a cold nodule in the right lobe and ultrasound thyroid confirmed the presence of hypo-echoic well defined lesion. Fine needle aspiration biopsy (FNAB) revealed a medullary thyroid cancer. She underwent total thyroidectomy and lymph node dissection. The histopathology showed a solitary tumor with mixed features, predominantly medullary with areas of follicular architecture, confirmed by immunohistochemical

staining as mixed MTC-FTC. Work up for MEN II and RET-proto-oncogen was negative. Postoperative isotope scan showed an increased uptake in the remnant thyroid tissue. She was treated with adjuvant radioactive iodine therapy. Her initial calcitonin level post operatively was 13.4 pg/ml (NR < 5.0), CEA 36 ng/ml (NR <3.8), and thyroglobulin was 0.7 ng/ml (NR <1). On follow up visits, the thyroglobulin as well as calcitonin and CEA levels were all suppressed. **Conclusion:** Cases of mixed follicular and medullary cancer present significant diagnostic and management challenges. Although we have managed our case surgically as well as by radioactive iodine and we are satisfied that follow up with calcitonin and thyroglobulin did not show any evidence of recurrence, we propose that mixed tumors be included in thyroid cancer management guidelines.

Key words: Mixed, Medullary thyroid cancer, Follicular thyroid cancer, Thyroglobulin, Radioactive iodine

Introduction

Thyroid cancers represent approximately 0.5-1% of all new cancers diagnosed annually. It is three times more common in women than in men and typically arises from two cell types. (1). The endodermally-derived follicular cells give rise to papillary (PTC), follicular, and probably anaplastic carcinomas of the thyroid gland while neural crest-derived parafollicular C-cells give rise to medullary thyroid cancer (MTC). MTC, first described in 1950 is a rare tumor that constitutes approximately 2-8% of all thyroid cancers, occurs with equally frequency in men and women and typically secretes calcitonin as well as number of neuroendocrine and Gastro-intestinal peptides (e.g. ghrelin, ACTH, chromogranin A, serotonin, and vasoactive intestinal peptide) (2). Almost 70% of MTC are sporadic, 10-20% occur in association with MENII syndromes while the rest are familial. Diagnostic features of MTC include an amyloid-rich stroma, a trabecular and nesting arrangement, positive calcitonin and CEA immunostaining, the presence of neuro-secretory granules and scarce atypia and nuclear uniformity (3,4). Due to the known aggressive natural history of this MTC, 50% of patients will present with either local or distant metastatic disease at the time of diagnosis. A rare variant of medullary thyroid cancer may contain both Calcitonin and Thyroglobulin, suggesting coexistence of both MTC and follicular cancer (5). This concomitance is seen in two main settings, a mixed tumor showing dual differentiation, or a collision tumor (a tumor with two separate and different components). The first description of these mixed tumors was by Hales et al

who described a mixed medullary-follicular carcinoma in 1982, followed by Pfaltz et al in 1983 (6). Featuring these two different malignant cells in one neoplasm carries a particular treatment challenge as well as uncertainties about the prognosis. There are no specific recommendations on treatment of mixed medullary-follicular thyroid cancer, but management should be driven by the medullary component. Surgical resection of the tumor with lymph node dissection, and preservation of laryngeal nerves, is the first-choice strategy. There is no evidence that radioiodine therapy is effective. However, the presence of thyroglobulin immunoreactive cells suggests a possible chance of action at least on the follicular component (7). We describe a case of mixed medullary follicular thyroid cancer in a 24 years old female. We will review the pertinent literature and addressing the management of this rare tumor.

Case Report

A 24 years old native female with no known comorbid conditions first presented in 2011 with a 2 months history of swelling increasing in size on the right side of her neck. She had no prior history of radiation exposure and no family history of endocrine disorders or thyroid cancer. Systemic review and clinical examination revealed her to be euthyroid. Clinical examination of the neck revealed a non-tender nodule in the right lobe measuring approximately 1.5-2.0 cm. No regional lymph nodes were palpable. The rest of her clinical examination was unremarkable. Thyroid function test was normal. Ultrasound of the thyroid, revealed a well-defined hypoechoic nodule with peripheral vascular

Table 1. Biochemical screening for multiple endocrine neoplasia (MENII). All results were well in the normal ranges.

Test	Patient's results	Reference ranges
Serum Calcium	8.0 mg/dl	8.9-10.2
Serum intact parathyroid hormone	7.8 pg/ml	6.2-29.0
Urine metanephrines	57 ug/24h	<400
Urinary metanephrines/creatinine ratio	62 ug/g	31-140
Urinary normetanephrine	99 ug/24h	<800
Urinary normetanephrine/creatinine ratio	107 ug/g	47-310

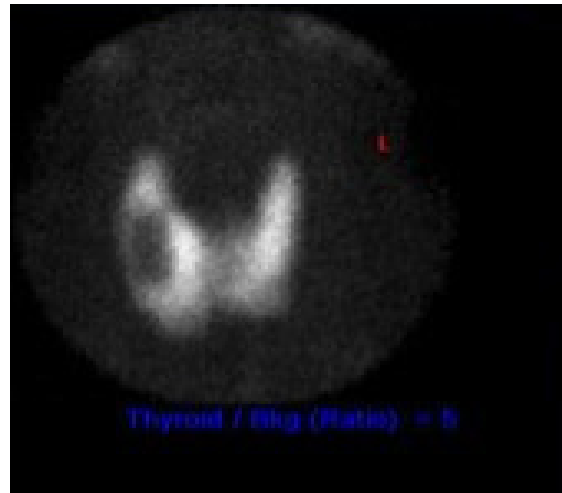
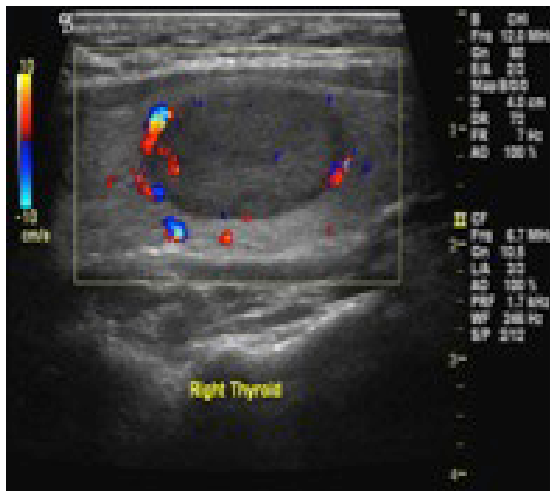


Figure 1. Ultrasound (Left) shows hypoechoic nodule; well-defined with clear margins, and peripheral vascular flow, measuring 2.7x1.4 cm, there are no calcifications. Corresponds to the cold nodule seen on the Technetium Perchnetate ($^{99m}\text{TcO}_4$) thyroid scintigraphy (Right).

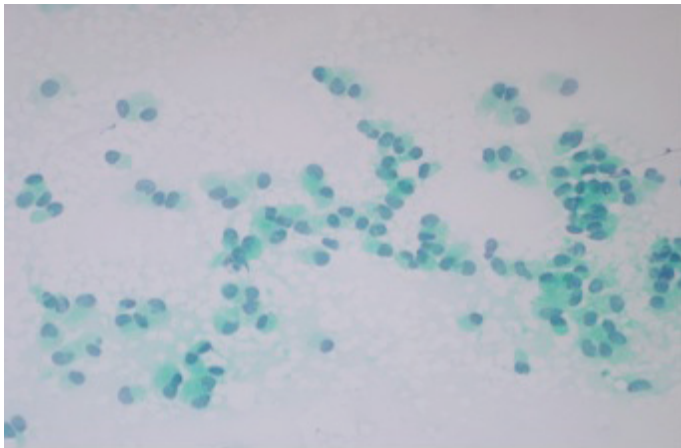


Figure 2. Medullary thyroid carcinoma. Fine needle aspiration (FNA) smear preparation [Papanicolaou stain]: Cellular smear consisting of mainly single, occasionally clustered, cells. Many cells show a plasmacytoid appearance (400X).

flow (and no associated calcifications) in the right lobe measuring 2.7x1.3 cm (Figure 1). Fine needle aspiration of the nodule revealed the presence of numerous isolated, focally aggregated cells with eccentric nuclei resulting in a plasmacytoid appearance. The tumor cell nuclei were hyperchromatic with stippled nuclear chromatin. In addition occasional nuclear pseudo-inclusions, granular cell cytoplasm and. Occasional multinucleated forms were observed. These findings were consistent with features of MTC (Figure 2). She subsequently underwent a total

thyroidectomy with lymph node dissection. Pathology revealed the presence of a 1.8 cm nodule showing predominantly (90%) medullary carcinoma (forming 90% of the microscopically examined tissue) admixed with a smaller portion of tumor showing follicular architecture. Congo red stain for amyloid was focally positive in the medullary areas, calcitonin was positive in both components (Figure 3) and thyroglobulin was positive in the neoplastic follicular population while negative in the medullary areas (Figure 4). There was evidence of vascular invasion (8-11). Fifteen lymph nodes were removed from the right lateral, central and left lateral compartments, all of which were negative for malignancy. In addition two parathyroid glands were identified in the resected specimen. Final pathological TNM stage was determined to be pT1bN0. Work up for Multiple Endocrine Neoplasia (Table 1) and testing of RET-proto-oncogene, was done. Results for both were negative (Table 1). She was subsequently treated with adjuvant radioactive iodine therapy (75mCi), and thyroxine 175mcg. Baseline calcitonin 1 week preoperatively was 1720 pg/ml. Post-operatively it dropped to 13.4pg/ml (normal < 5.0) and to <2pg/ml on follow up visits. CEA preoperatively was 36ng/ml (NR0 <3.8) that dropped to 1.1ng/ml during follow up. Thyroglobulin level was not done preoperatively however immediate postoperative thyroglobulin level was 0.7ng/ml (NR <1) that dropped to <0.1ng/ml on follow up visits. Preoperative calcium level was 9.4mg/dl, which dropped to 7.5mg/dl post operatively. She was started on calcium carbonate as well

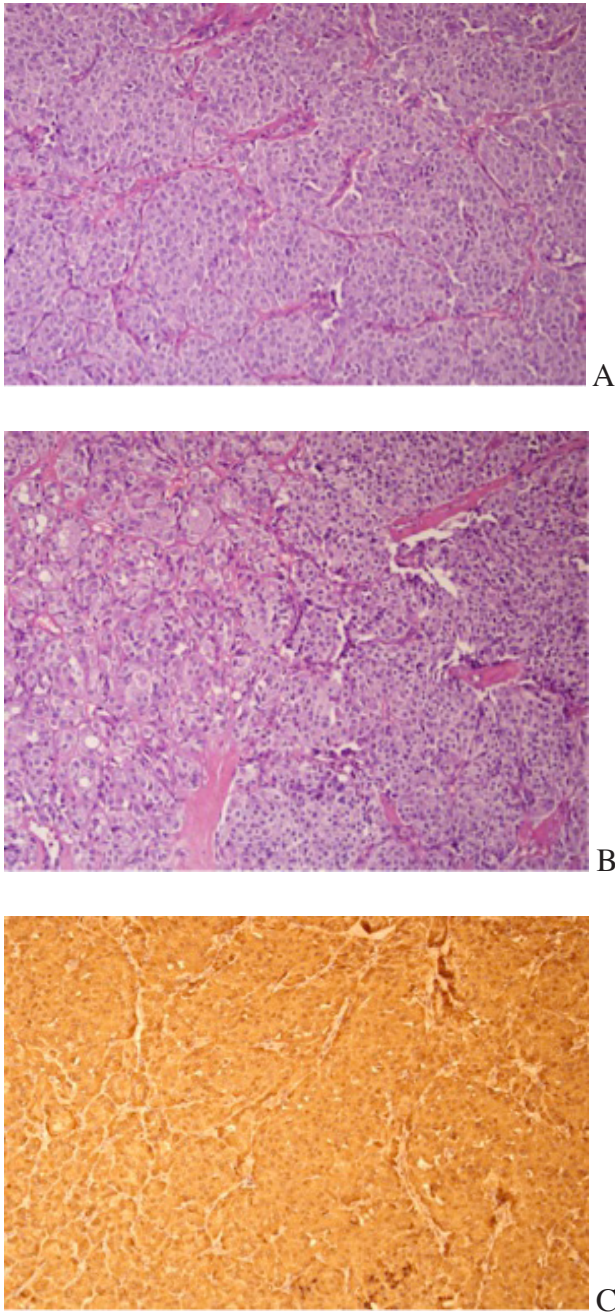


Figure 3. Histological confirmation of the mixed medullary and follicular carcinoma. A. The medullary carcinoma component was predominant and was characterized by nests and trabeculae composed of polygonal cells with round nuclei and granular cytoplasm with intervening stroma (H&E, 200X); B. The right side of the photomicrograph shows medullary carcinoma component juxtaped with the follicular carcinoma component seen on the left (H&E, 200X) and C. The immunohistochemical stain for calcitonin - both medullary and follicular carcinoma components are labeled with brown signal and are calcitonin positive (200X).

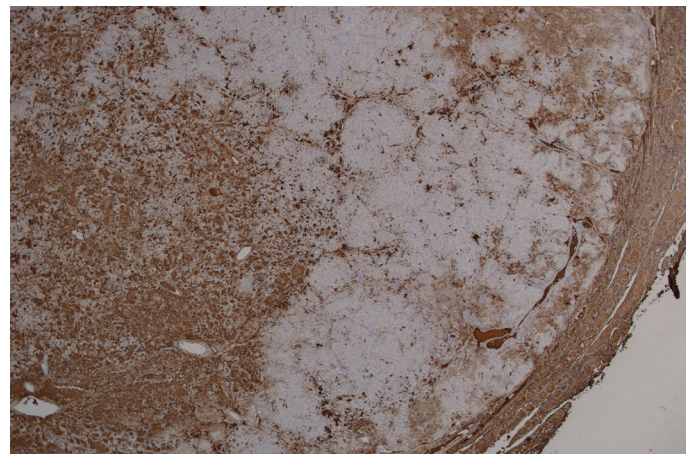
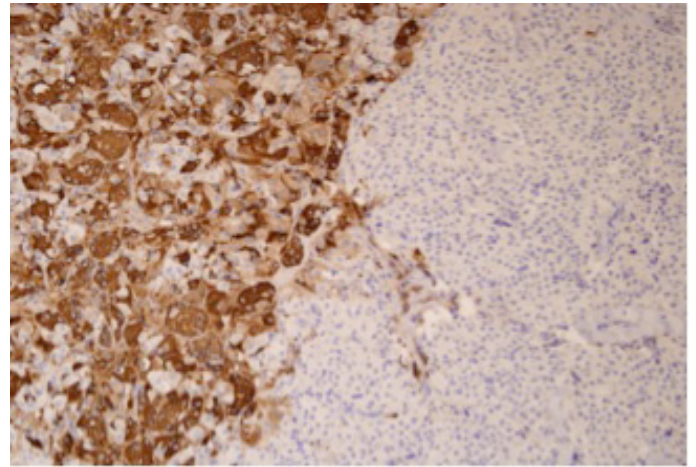


Figure 4. The mixed medullary and follicular carcinoma is illustrated by thyroglobulin immune-stain positive signal [brown labeling of cell cytoplasm] being confined to the follicular component (F) and is not present in the medullary component (M) of the tumor nor the normal thyroid tissue (N) as seen in the upper high power images (200X) and lower low power images (x40) showing both medullary and follicular components within the tumor capsule.

as alfa calcidol for her postoperative hypoparathyroidism. Her disease is evident by persistently low parathyroid hormone levels and surgical removal of two parathyroid glands, rather than high calcitonin level. She is currently 2.5 years post op and doing well with no biochemical or clinical evidence of recurrence. Written informed consent was obtained from the patient for publication of this case report and any accompanying images.

Discussion

The world health organization defines mixed medullary

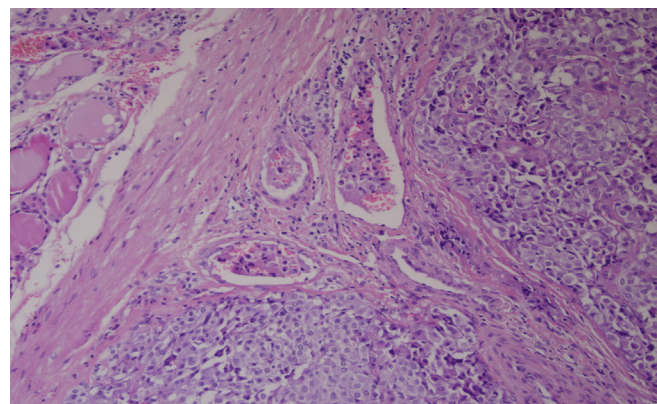
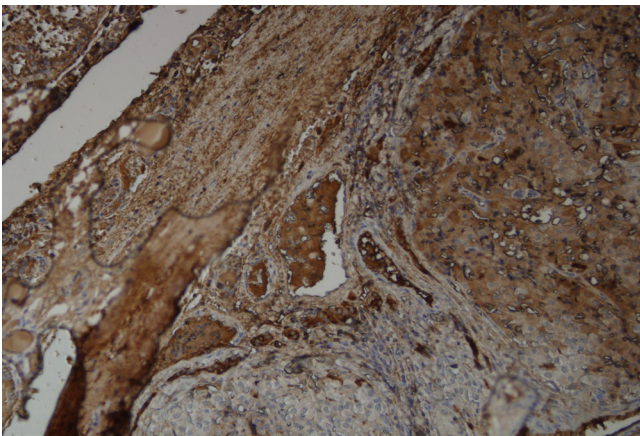
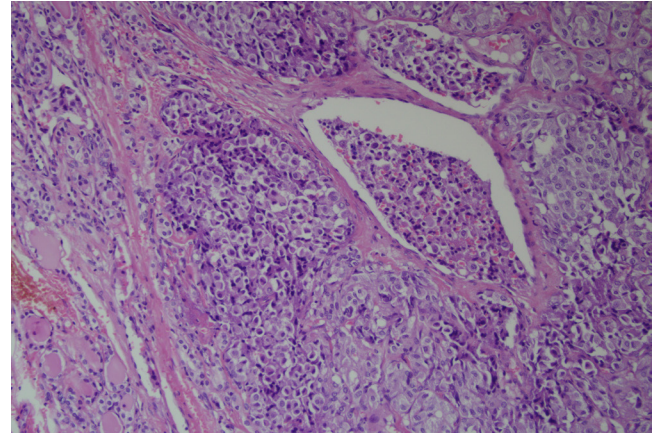
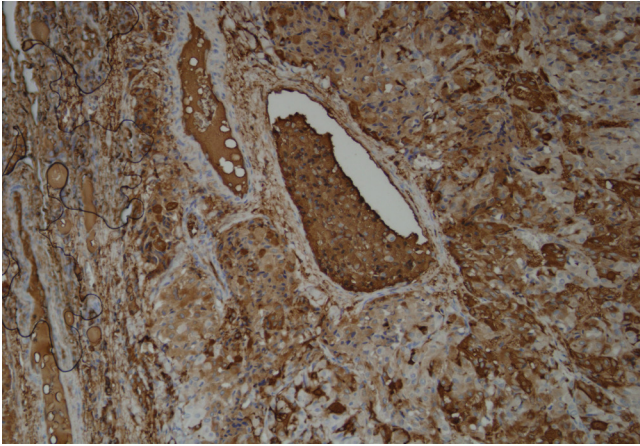


Figure 5. Vascular invasion by follicular thyroid cancer shown by high power (1096x200) using thyroglobulin staining (A&B) and H&E staining (C&D)

and follicular cell carcinomas as those tumors that show morphological features of both medullary carcinoma (immunoreactive to calcitonin) and follicular (or papillary) carcinomas (immunoreactive thyroglobulin). In the case presented based on the presence of thyroglobulin positive neoplastic follicles that formed a minor component of a predominantly typical medullary carcinoma, that was positive for calcitonin, the tumor was classified as a mixed medullary and follicular cell carcinoma and are considered a clinic-pathological variant of medullary thyroid cancer (8). These mixed tumors can present either in synchronous fashion where they appear as anatomically separate tumors or as two components mixed within a single lesion (9).

The American Thyroid Association (ATA) recommends the use of radioactive iodine (RAI) therapy for non-

papillary thyroid cancer (follicular and Hurthle cell cancer). Minimally-invasive follicular cancers (capsular invasion) might not require RAI therapy (10). The first choice of treatment for MTC is thyroidectomy with lymph nodes dissection. ATA has also set specific indications to the use of external beam irradiation (EBR) therapy in MTC (11). The follicular component of mixed medullary follicular thyroid cancer, as in conventional FTC, accumulates radioactive iodine, but no evidence to suggest that any medical therapy is effective for treatment of MTC. Treatment of MTC with chemotherapy is still controversial (12).

On review of the literature (using the Pub Med database) using different search terms for available evidence-based management of these rare tumors, more than forty cases were found. Emphasis was mostly on histopathologic

criteria and origin of these mixed tumors (13-15). Only one article discussed the treatment (7). It suggested that treatment should be driven by the medullary component namely surgery and lymph node dissection. Following total thyroidectomy and lymph node dissection, we treated our patient further with radioactive iodine. Our decision was based on the fact that the follicular thyroid cancers are more invasive than papillary, and that in our patient there was vascular invasion. Lack of specific recommendations and guidelines for such tumors is highlighted.

In conclusion, cases of mixed follicular and medullary cancer present significant diagnostic and management challenges. We have managed our case surgically as well as by radioactive iodine, we are fairly satisfied that follow up with calcitonin and thyroglobulin did not show any evidence of recurrence. We suggest mixed tumors deserve a special mention in thyroid cancer management guidelines.

Acknowledgement

The authors would like to acknowledge Dr. Azza Bin Hussain for her contribution in revision the manuscript.

References

1. Papotti M, Negro F, Carney JA, Bussolati G, Lloyd RV. Mixed medullary-follicular carcinoma of the thyroid. A morphological, immunohistochemical and in situ hybridization analysis of 11 cases. *Virchows Arch* 1997;430:397-405.
2. Kanamoto N, Akamizu T, Hosoda H, Hataya Y, Ariyasu H, Takaya K, Hosoda K, et al. Substantial production of Ghrelin by a human medullary thyroid carcinoma cell line. *J Clin Endocrinol Metab* 2001;86:4984-90.
3. Hazard J, Hawk W, Crile G J. Medullary (solid) carcinoma of the thyroid. A clinicopathologic entity. *J Clin Endocrinol Metab* 1959;19:152.
4. Matias-Guiu X. Mixed medullary and follicular carcinoma of the thyroid. On the search for its histogenesis. *Am J Pathol*. 1999;155(5):1413-8.
5. Noel M, Delehay M, Segond N, Caillou F, Gardet P, Fragu P, Moukhtar M. Study of calcitonin and thyroglobulin gene expression in human mixed follicular and medullary thyroid carcinoma. *Thyroid* 1991;1(3):249-56.
6. Sobrinho-Simoes M, Fonseca E. Recently described tumors of the thyroid. In: Anthony PP, MacSween NR, editors. *Recent Advances in Histopathology*. Edinburgh (UK): Churchill Livingstone Publishers; 1994. p. 213-29.
7. Papotti M, Volante M, Komminoth P, Sobrinho-Simoes M, Bussolati G. Thyroid carcinomas with mixed follicular and C-cell differentiation patterns. *Semin Diagn Pathol* 2000;17:109-19.
8. Hsieh MH, Lin MC, Shun CT, Chang TC. Fine needle aspiration cytology of mixed medullary-follicular thyroid carcinoma: a case report. *Acta Cytol* 2008;52(3):361-5.
9. Sadow PM, Hunt JL. Mixed Medullary-Follicular-derived carcinomas of the thyroid gland. *Adv Anat Pathol* 2010;17(4):282-4.
10. Van Heerden JA, Hay ID, Goellner JR, Salomao D, Ebersold JR, Bergstrahl EJ, et al. Follicular thyroid carcinoma with capsular invasion alone: a nonthreatening malignancy. *Surgery* 1992;112:1130.
11. Kloos RT, Eng C, Evans DB, Francis GL, Gagel FR, Gharib H, et al. Medullary thyroid cancer: Management guidelines of the American Thyroid Association. *Thyroid* 2009;19(6):565-612.
12. Hales M, Rosenau W, Okerlund MD, Galante M. Carcinoma of the thyroid with a mixed medullary and follicular pattern: morphologic, immunohistochemical, and clinical laboratory studies. *Cancer* 1982;50:1352-9.
13. Hanna AN, Michael CW, Jing X. Mixed medullary-follicular carcinoma of the thyroid: diagnostic dilemmas in fine needle aspiration cytology. *Dign Cytopath*. 2011;39(11):862-5.
14. Hasney CP, Amedee RG. Mixed medullary-papillary carcinoma of the thyroid: a case report. *Laryngoscope*. 2010;120 suppl(4):S153.
15. Nanque C, bron L, Portmann L, Volante M, Ris HB, Monnier P, Andrejevic-Blant S. Mixed medullary-papillary carcinoma of the thyroid: report of a case and review of the literature. *Head Neck*. 2009;31(7):968-74.