

ARTICLE

Histological Effects of Permethrin Insecticide on the Testis of Adult Wistar Rats

Gabriel Olaiya Omotoso, Ismail Olasile Onanuga, Ridwan Babatunde Ibrahim

Department of Anatomy, Faculty of Basic Medical Sciences, College of Health Sciences, University of Ilorin, PMB 1515, Ilorin, 240003, Nigeria.

Corresponding author: Dr. Gabriel Olaiya Omotoso

Email: gabrielolaiya@yahoo.com

Published: 01 May 2014

Ibnosina J Med BS 2014;6(3):125-129

Received: 03 September 2103

Accepted: 05 January 2014

This article is available from: <http://www.ijmbs.org>

This is an Open Access article distributed under the terms of the Creative Commons Attribution 3.0 License, which permits unrestricted use, distribution, and reproduction in any medium, provided the original work is properly cited.

Abstract

Permethrin is a common constituent in some household insecticides. This study examined the effects of this chemical on the testicular histology of exposed rats. Fifteen adult male Wistar rats were subgrouped into a control and two treatment groups. The controls were fed on normal rat feeds, whilst the diet of animals in the two treatment groups was mixed with 500 mg/kg and 1000 mg/kg Permethrin respectively. An increase in body weights and organ weights was observed in the animals in both treatment groups. Various degrees of histological alterations in the structure of their seminiferous tubules were also observed in comparison with the control group. These abnormalities included disruption of the normal architecture, reduction in the population of mature sperm cells, wider luminal diameter and reduced interstitial spaces. These effects could impair the fertility potential of male subjects.

Keywords: Permethrin, Testes, Histology, Fertility.

Introduction

Pyrethroids are synthesized derivatives of the naturally occurring pyrethrum (*Chrysanthemum* flowers); and Permethrin is a type I pyrethroid widely used as an insecticide (1). It is also used topically in the medical treatment of scabies and diseases associated with lice and mites (2). Very frequently, it is used in many household, in its powdery form, in killing insects, like cockroaches. In the tropics, insecticide nets are often treated with pyrethroids as part of efforts in combating the scourge of Malaria (3). Both agricultural and domestic uses of pesticides and insecticides have resulted in different forms of diseases (4), and the effects are not only limited to the immediate users. Although they have high selectivity for insects (5), several studies have described the adverse effects of pyrethroids on

the different organs and systems of the body, such as the liver, gastro-intestinal, respiratory, nervous and immune systems. Permethrin inhibits natural killer cells which are critical components of the immune system (6), and is both mutagenic and carcinogenic (7). Pyrethroids are metabolised in the liver (8). Their mechanism of action is by acting on voltage-sensitive sodium channels to prolong the closure time, with consequent reduction in action potential threshold and repetitive firing (3,9). Studies in rats showed that permethrin affects male reproductive functions by directly reducing the motility of mature sperm cells (1). Chronic exposure to pesticides containing pyrethroids may also cause disturbances in endocrine functions relating to androgen action, as they interact competitively with human androgen receptors and sex

hormone binding globulin (10). Although, interaction with sex hormone binding globulin was only seen with other members of the pyrethroid family (namely, Pyrethrins and Bioallethrin) but not Permethrin (10), a more recent study revealed that Permethrin had detrimental effects on plasma testosterone level and sexual behaviour in adult male NMRI mice (11). The current study examined the effects of Permethrin on the histology of the male gonads.

Materials and Methods

Experimental animals

Fifteen adult male Wistar rats were bred and used for the study. They were housed in individual cages and allowed to acclimatize prior to commencement of the experiment. They were kept under hygienic and

Table 1: Body weight and testicular weight in control and treatment groups of animals (n=5 per group).

Study Groups	Final body weight (g)	Initial body weight (g)	Body weight difference (g)	Testicular weight (g)	Testicular/Body weight ratio
A. Control	244 ± 6	209 ± 3	35 ^a	1.01 ± 0.0	0.0042
B. Permethrin 500 mg/kg	274 ± 6	234 ± 5	40 ^a	1.11 ± 0.1	0.0041
C. Permethrin 1000 mg/kg	305 ± 8	260 ± 6	45 ^a	1.20 ± 0.0 ^b	0.0040

Statistically significant (p <0.05) difference in body weights between the groups (a) and in the testicular weights of the high dose group C only compared with the controls (b).

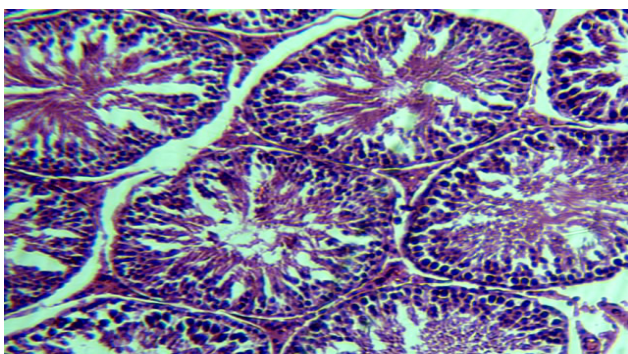


Figure 1. Photomicrograph of the seminiferous tubules of the testis of rats in the control group showing apparently normal architecture: the outer layer made up of myoid cells (yellow arrow), basally located Sertoli cells (red arrow), spermatogonia (white arrow), lumen (L) filled with mature sperm cells, and the interstitium with Leydig cells (green arrow). H&E x100.

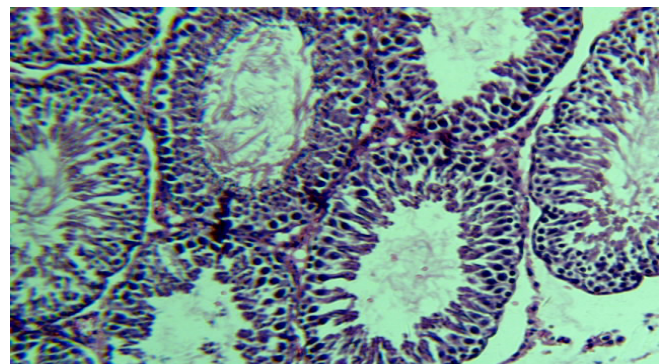


Figure 2. Photomicrograph of the seminiferous tubules of the testis of rats in the group B administered with 500 mg/kg permethrin showing reduced staining intensity, wider luminal diameter, with reduced population of mature sperm cells in the lumen. H&E x100.

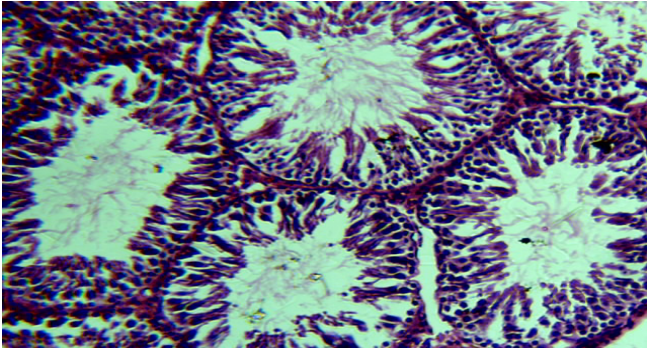


Figure 3. Photomicrograph of the seminiferous tubules of the testis of rats in the group C administered with 1000 mg/kg Permethrin showing wider luminal diameter, reduced luminal spermatozoa, reduced interstitial spaces; staining is however better, compared to group B. H&E x100.

favorable conditions, and maintained under a 12h light/12h dark cycle, with pelletized rat feeds (UAC Vital Feeds®, Nigeria) and water available *ad libitum*.

Experimental design

Insecticide powder (Rambo®; Gongoni Co. Ltd, Kano, Nigeria) containing 0.6% Permethrin and 99.6% inert carriers, was obtained and used for the study. The LD₅₀ of Permethrin in rats ranges from 430-4000 mg/kg (12). The animals were randomly divided into three (3) groups, with five (5) rats in each group. Group A rats were fed with normal diet, and served as controls, while treated groups B and C had 500 mg/kg and 1000 mg/kg of Permethrin respectively mixed with their regular diet. The experiment lasted for 14 days.

Sample collection

The animals were sacrificed by cervical dislocation 24 hours after the last day of administration. The abdomen was dissected, and tissue specimens of the testes were removed and fixed in 10% formal saline for histological processing, using standard Haematoxylin and Eosin staining.

Results

Body and testicular weights

The weights of the animals increased proportionately in all three groups (Table 1). The treated groups gained more weights particularly in the group C ($P < 0.05$). The testicular weights of both treated groups increased in comparison with the control group (Table 1). The

testicular weight was also higher in group C.

Histological changes

Observation from the histological sections demonstrated apparently normal seminiferous tubules in controls with sperm cell series at different stages of development and they were well stained. The lumens were filled with a good population of mature sperm cells (spermatozoa) and a healthy interstitium was also demonstrable (Figure 1). The testes of rats that received 500 mg/kg Permethrin showed seminiferous tubules with poor staining intensity compared with the control group. The luminal diameter of the seminiferous tubules was also wider and the population of spermatozoa was markedly reduced. Generally, the spermatogenic cells appeared to have decreased in number compared to the control, and the characteristic shape of the seminiferous tubules was lost (Figure 2). Although tissue staining of the testes of rats administered with 1000 mg/kg Permethrin was better than the low dose group, presence of wider luminal diameter and reduced interstitial spaces were noted, and the population of sperm cells was also reduced within the lumen (Figure 3).

Discussion

Findings from this study revealed that oral ingestion of Permethrin-containing feeds was associated with increase in both body weights and testicular weights in comparison with animals fed on normal diet throughout the two weeks experiment. This assessment was based solely on weight measurement, but the rate of food consumption or quantity consumed was not measured, making it difficult to ascertain the reasons for the increase in weight. In vitro studies of the effect of the Pyrethroids on male reproductive function showed that both type I and type II are capable of directly reducing the motility of spermatozoa (1), with a possible impairment of male reproductive capability. In the current study, animals fed on Permethrin-containing feeds exhibited some degree of loss in the consistency of their seminiferous tubules, and the general architecture was not as intact as seen in the controls. The reduction in the staining intensity could complement the reduction in

spermatogenic cells, or could be due to a structural or biochemical compromise in the sperm cells, since the cell nuclei normally take up the Haematoxylin stains. The Sertoli cells were not well demonstrated in the treated groups; however, alterations in the interstitial spaces, in the form of loss of tissue components and obliteration of the space by closely packed seminiferous tubules in the high dose group could adversely affect the structure and function of Leydig cells, especially as it relates to the male sex hormone, testosterone. Pyrethroids and their metabolites disrupt the function of multiple nuclear hormone receptors (13), possessing antiandrogen-like effects; and, significant reductions in androgen-dependent sex accessory tissues have been reported (14). These adversely affect testosterone level, with a possibility of impaired male reproductive capability (11). The mechanism by which Permethrin affects testosterone could also be linked to mitochondrial membrane impairment in Leydig cells (15), which disrupts testosterone biosynthesis.

We conclude that exposure to Permethrin is detrimental to the architecture of the testes. Both the spermatogenic and non-spermatogenic cells of the testes were impaired. Together with the work on hormonal effects published previously (11), we propose that male reproductive functions may be adversely affected by exposure to Permethrin. Similar effects in humans may possibly occur with possible adverse effects on fertility potential of male subjects.

References

1. Yuan C, Wang C, Gao SQ, Kong TT, Chen L, Li XF et al. Effects of permethrin, cypermethrin and 3-phenoxybenzoic acid on rat sperm motility in vitro evaluated with computer-assisted sperm analysis. *Toxicol In Vitro*. 2010;24(2):382-6.
2. Yoon KS, Gao J, Lee SH, Clark JM, Brown L, Taplin D. Permethrin-resistant human head lice, *Pediculus capitis*, and their treatment. *Arch Dermatol*. 2003;139(8):994-1000.
3. Bradberry SM, Cage SA, Proudfoot AT, Vale JA. Poisoning due to pyrethroids. *Toxicol Rev*. 2005;4(2):93-106.
4. Otitoju O. Sub-chronic effect of Rambo insect powder contaminated diet on superoxide dismutase (SOD) activity in Wistar albino rats. *Biokemistri*. 2005;17(2):157-63.
5. Wolansky MJ, Harrill JA. Neurobehavioral toxicology of pyrethroid insecticides in adult animals: a critical review. *Neurotoxicol Teratol*. 2008;30(2):55-78.
6. Blaylock BL, Abdel-Nasser M, McCarty SM, Knesel JA, Tolson KM, Ferguson PW et al. Suppression of cellular immune responses in BALB/c mice following oral exposure to permethrin. *Bull Environ Contam Toxicol*. 1995;54(5):768-74.
7. Kale PG, Bobby T, Petty BT, Walker S, Ford JB, Dehkordi N. Mutagenicity testing of nine herbicides and pesticides currently used in agriculture. *Environ Mol Mutagen* 1995;25(2):148-53.
8. Lotti M. 2001. Clinical toxicology of anticholinesterase agents in humans. In: Krieger RI, ed. *Handbook of Pesticide Toxicology*. Vol. 2, Agents. 2nd ed. San Diego, CA: Academic Press. Pp. 1043–1085
9. Kakko I, Toimela T, Tähti H. The synaptosomal membrane bound ATPase as a target for the neurotoxic effects of pyrethroids, permethrin and cypermethrin. *Chemosphere* 2003;51:475-80.
10. Eil C, Nisula BC. The binding properties of pyrethroids to human skin fibroblast androgen receptors and to sex hormone binding globulin. *J Steroid Biochem* 1990;35:409-14.
11. Solati J, Tondar M, Abutalebi N. Effects of permethrin on sexual behaviour and plasma concentrations of pituitary–gonadal hormones in adult male NMRI mice. *Endocrine Abstracts* 2009;20:512.
12. Tomlin CDS. *The Pesticide Manual: A World Compendium*. Ed. 14, Alton, England: British Crop Production Council; 2006.
13. Du G, Shen O, Sun H, Fei J, Lu C, Song L et al. Assessing hormone receptor activities of pyrethroid insecticides and their metabolites in reporter gene assays. *Toxicol Sci* 2010;116(1):58-66.
14. Kim SS, Lee RD, Lim KJ, Kwack SJ, Rhee GS, Seok JH et al. Potential estrogenic and antiandrogenic effects of permethrin in rats. *J*

Reprod Dev 2005;51(2):201-10.

15. Zhang S-Y, Ito Y, Yamanoshita O, Yanagiba Y, Kobayashi M, Taya K et al. Permethrin may disrupt testosterone biosynthesis via mitochondrial membrane damage of Leydig cells in adult male mouse. *Endocrinology* 2007;148(8):3941-9.